National Comprehensive Cancer Network®

NCCN Clinical Practice Guidelines in Oncology (NCCN Guidelines®)

Biliary Tract Cancers

Version 1.2026 — March 10, 2026

NCCN recognizes the importance of clinical trials and encourages participation when applicable and available. Trials should be designed to maximize inclusiveness and broad representative enrollment.

NCCN Guidelines for Patients® available at www.nccn.org/patients

Version 1.2026, 03/10/26 © 2026 National Comprehensive Cancer Network® (NCCN®), All rights reserved. NCCN Guidelines® and this illustration may not be reproduced in any form without the express written permission of NCCN.

PLEASE NOTE that use of this NCCN Content is governed by the End-User License Agreement, and you MAY NOT distribute this Content or use it with any artificial intelligence model or tool.
Printed by Máximo López Chenlo on 5/4/2026 6:13:37 PM. Copyright © 2026 National Comprehensive Cancer Network, Inc. All Rights Reserved.

***Al B. Benson, III, MD/Chair †**
Robert H. Lurie Comprehensive Cancer Center of Northwestern University

***Michael I. D'Angelica, MD/Vice-Chair ¶**
Memorial Sloan Kettering Cancer Center

Aijaz Ahmed, MD ¤
Stanford Cancer Institute

Mehmet Akce, MD † ‡
O'Neal Comprehensive Cancer Center at UAB

Daniel A. Anaya, MD ¶
Moffitt Cancer Center

Robert Anders, MD, PhD ¤ ≠
Johns Hopkins Kimmel Cancer Center

Chandrakanth Are, MBBS, MBA ¶
Fred & Pamela Buffett Cancer Center

Lydia Aye, DO ¤ ξ
UC Davis Comprehensive Cancer Center

Melinda Bachini ¥
Cholangiocarcinoma Foundation

Marshall Baker, MD, MBA ¶
Huntsman Cancer Institute at the University of Utah

David Binder, MD §
University of Colorado Cancer Center

Adam Burgoyne, MD, PhD †
UC San Diego Moores Cancer Center

Jason Castellanos, MD, MS ¶
Fox Chase Cancer Center

Saurin Chokshi, MD †
St. Jude Children's Research Hospital/The University of Tennessee Health Science Center

NCCN
Cindy Hochstetler, PhD
Ryan Schonfeld, BA
MaryElizabeth Stein, PhD

James Cleary, MD, PhD †
Dana-Farber/Brigham and Women's Cancer Center | Mass General Cancer Center

Jordan Cloyd, MD ¶
The Ohio State University Comprehensive Cancer Center - James Cancer Hospital and Solove Research Institute

Darren Cullinan, MD, MSCI ¶
Siteman Cancer Center at Barnes-Jewish Hospital and Washington University School of Medicine

Meaghan Dendy Case, MD, MA ф
Vanderbilt-Ingram Cancer Center

Joseph Franses, MD, PhD †
The UChicago Medicine Comprehensive Cancer Center

William Harris, MD †
Fred Hutchinson Cancer Center

Lawrence Jennings, MD, PhD ≠
Robert H. Lurie Comprehensive Cancer Center of Northwestern University

R. Kate Kelley, MD † ‡
UCSF Helen Diller Family Comprehensive Cancer Center

Sajid Khan, MD ¶
Yale Cancer Center/Smilow Cancer Hospital

Matthew Levine, MD, PhD ξ
Abramson Cancer Center at the University of Pennsylvania

Laleh Melstrom, MD, MS ¶
City of Hope National Medical Center

Manisha Palta, MD §
Duke Cancer Institute

Steven Raman, MD ф
UCLA Jonsson Comprehensive Cancer Center

Sean Ronnekleiv-Kelly, MD ¶
University of Wisconsin Carbone Cancer Center

Vaibhav Sahai, MBBS, MS †
University of Michigan Rogel Cancer Center

Kevin Stephans, MD §
Case Comprehensive Cancer Center/ University Hospitals Seidman Cancer Center and Cleveland Clinic Taussig Cancer Institute

Kannan Thanikachalam, MD †
Roswell Park Comprehensive Cancer Center

Anita Turk, MD †
Indiana University Melvin and Bren Simon Comprehensive Cancer Center

Jean-Nicolas Vauthey, MD ¶
The University of Texas MD Anderson Cancer Center

Alan P. Venook, MD † ‡ Þ
UCSF Helen Diller Family Comprehensive Cancer Center

Motoyo Yano, MD, PhD ф
Mayo Clinic Comprehensive Cancer Center

Adam Yopp, MD ¶
UT Southwestern Simmons Comprehensive Cancer Center

Ken Zhao, MD ф
Memorial Sloan Kettering Cancer Center

ф Diagnostic/Interventional radiology
¤ Gastroenterology
‡ Hematology/Hematology oncology
Þ Internal medicine
† Medical oncology
≠ Pathology
¥ Patient advocacy
§ Radiotherapy/Radiation oncology
¶ Surgery/Surgical oncology
ξ Transplantation
* Discussion section writing committee

NCCN Guidelines Panel Disclosures

Version 1.2026, 03/10/26 © 2026 National Comprehensive Cancer Network® (NCCN®), All rights reserved. NCCN Guidelines® and this illustration may not be reproduced in any form without the express written permission of NCCN.

PLEASE NOTE that use of this NCCN Content is governed by the End-User License Agreement, and you MAY NOT distribute this Content or use it with any artificial intelligence model or tool.
Printed by Máximo López Chenlo on 5/4/2026 6:13:37 PM. Copyright © 2026 National Comprehensive Cancer Network, Inc. All Rights Reserved.

NCCN Guidelines Version 1.2026
Biliary Tract Cancers

NCCN Biliary Tract Cancers Panel Members
Summary of the Guidelines Updates

Gallbladder Cancer
- Incidental Finding of Suspicious Mass During Surgery (GALL-1)
- Hepatobiliary Surgery Expertise Unavailable (GALL-2)
- Incidental Finding on Pathologic Review (GALL-3)
- Mass on Imaging (GALL-4)
- Jaundice and Metastatic Disease (GALL-5)
- Post-Surgical Treatment, Surveillance (GALL-6)
- Principles of Surgery (GALL-A)
- Principles of Pathology (GALL-B)

Intrahepatic Cholangiocarcinoma
- Presentation, Workup, Primary Treatment (INTRA-1)
- Post-Surgical Treatment, Surveillance (INTRA-2)
- Principles of Surgery (INTRA-A)
- Principles of Mixed HCC-CCA (INTRA-B)
- Principles of Pathology (INTRA-C)
- Principles of Arterial/Locoregional Therapy for Intrahepatic Cholangiocarcinoma (INTRA-D)

Extrahepatic Cholangiocarcinoma
- Presentation, Workup, Primary Treatment (EXTRA-1)
- Post-Surgical Treatment, Surveillance (EXTRA-2)
- Principles of Surgery (EXTRA-A)
- Principles of Pathology (EXTRA-B)

- Principles of Imaging (BIL-A)
- Principles of Biomarker Testing (BIL-B)
- Principles of Systemic Therapy (BIL-C)
- Principles of Radiation Therapy (BIL-D)

Biliary Tract Cancer Staging
AJCC Staging (ST-1)

Abbreviations (ABBR-1)

Find an NCCN Member Institution: https://www.nccn.org/home/member-institutions.

NCCN Categories of Evidence and Consensus: All recommendations are category 2A unless otherwise indicated.

See NCCN Categories of Evidence and Consensus.

NCCN Categories of Preference: All recommendations are considered appropriate.

See NCCN Categories of Preference.

The NCCN Guidelines® are a statement of evidence and consensus of the authors regarding their views of currently accepted approaches to treatment. Any clinician seeking to apply or consult the NCCN Guidelines is expected to use independent medical judgment in the context of individual clinical circumstances to determine any patient's care or treatment. The National Comprehensive Cancer Network® (NCCN®) makes no representations or warranties of any kind regarding their content, use or application and disclaims any responsibility for their application or use in any way. The NCCN Guidelines are copyrighted by National Comprehensive Cancer Network®. All rights reserved. The NCCN Guidelines and the illustrations herein may not be reproduced in any form without the express written permission of NCCN. ©2026.

PLEASE NOTE that use of this NCCN Content is governed by the End-User License Agreement, and you MAY NOT distribute this Content or use it with any artificial intelligence model or tool.
Printed by Máximo López Chenlo on 5/4/2026 6:13:37 PM. Copyright © 2026 National Comprehensive Cancer Network, Inc. All Rights Reserved.

Updates in Version 1.2026 of the NCCN Guidelines for Biliary Tract Cancers:

GALL-1
- Footnote a added: Refer to the NCCN Distress Thermometer and Problem List, which includes social determinants of health. This tool can be utilized throughout the patient's care continuum. See NCCN Guidelines for Distress Management (DIS-A).
- Footnote f added: Core biopsy is preferred over fine-needle aspiration (FNA). (Also for GALL-2 through GALL-5)

GALL-3
- Bottom pathway, resectable arrow changed to direct to "consider neoadjuvant systemic therapy or clinical trial".

GALL-6
- Post-surgical treatment
  - Top pathway, options, last bullet revised: *Combination of chemotherapy and* chemoradiation (category 2B)

GALL-B
- Pathologic staging
  - Bullet 1, last sub-bullet, tertiary bullet 2 added: Core biopsy is preferred over fine-needle aspiration (FNA)

Intrahepatic Cholangiocarcinoma

INTRA-1
- Workup
  - Bullet 9 revised: *Consider* esophagogastroduodenoscopy and colonoscopy
- Primary Treatment
  - Last column, last bullet revised: Consider *re*-evaluation for liver transplantation.
- Footnote a added: Refer to the NCCN Distress Thermometer and Problem List, which includes social determinants of health. See NCCN Guidelines for Distress Management (DIS-A). (Also for EXTRA-1)
- Footnote s revised: Patients who meet the following criteria will be eligible for transplant exception points: biopsy-proven iCCA or mixed HCC-iCCA, presence of cirrhosis, unresectable, received locoregional or systemic therapy, and 6 months from time of diagnosis or last treatment with no new lesions or extrahepatic disease. *Consider referral to hepatologist.*

INTRA-B (1 of 2)
- Paragraph 2, second sentence revised: 2 Though prospective data are lacking, liver-directed ~~local~~ *locoregional* therapies may be appropriate for patients with a limited extent of unresectable hepatic disease, similar to management algorithms for HCC and intrahepatic CCA (iCCA) (see NCCN Guidelines for Hepatocellular Carcinoma and INTRA-1).
- Footnote b added: Pembrolizumab and berahyaluronidase alfa-pmph subcutaneous injection may be substituted for IV pembrolizumab. Pembrolizumab and berahyaluronidase alfa-pmph has different dosing and administration instructions compared to IV pembrolizumab. (Also as footnote k on BIL-C 2 and 3 of 5)

INTRA-C
- Intrahepatic Cholangiocarcinoma Undergoing Resection, reported parameters
  - Bullet 1, sub-bullet 5 revised: Histologic differentiation *(small duct type or large duct type).*

Extrahepatic Cholangiocarcinoma

EXTRA-2
- Surveillance revised: ~~Consider imaging every 3–6 mo for 2 y, then every 6–12 mo for up to 5 y,a or as clinically indicated~~ *Consider multiphasic abdomen/pelvis CT/MRI with IV contrast and chest CT ± contrast every 3–6 mo for 2 y, then every 6–12 mo for up to 5 y, or as clinically indicated.*

EXTRA-A
- General Principles
  - Bullet 1, last sentence revised: ~~Rarely~~ *Occasionally*, a mid bile duct tumor can be resected with a bile duct resection and regional lymphadenectomy.
  - Bullet 4, first sentence revised: ~~Occasionally~~ *Rarely*, a bile duct tumor will involve the biliary tree over a long distance such that a hepatic resection and pancreaticoduodenectomy will be necessary.
- Distal Cholangiocarcinoma
  - Bullet 3 added: If suspected diagnosis, consider assessing frozen section of proximal bile duct margin.

Continued

Version 1.2026, 03/10/26 © 2026 National Comprehensive Cancer Network® (NCCN®), All rights reserved. NCCN Guidelines® and this illustration may not be reproduced in any form without the express written permission of NCCN.

PLEASE NOTE that use of this NCCN Content is governed by the End-User License Agreement, and you MAY NOT distribute this Content or use it with any artificial intelligence model or tool.
Printed by Máximo López Chenlo on 5/4/2026 6:13:37 PM. Copyright © 2026 National Comprehensive Cancer Network, Inc. All Rights Reserved.

Updates in Version 1.2026 of the NCCN Guidelines for Biliary Tract Cancers:

Biliary Tract Cancers

BIL-B (1 of 8)

- Recommendations
  - Bullet 1 revised: Biomarker testing in BTCs: MGPT and other biomarker testing is recommended for patients with unresectable or metastatic BTC who are candidates for systemic therapy (see Table 1 and Table 2). A comprehensive panel including the targets listed in Table 1 may optimize the chance of identifying a biomarkers for targeted therapy. *Consider tissue RNA-based MGPT to maximize detection of fusion events.* If tissue is too scant or not available, consider repeat biopsy depending on tumor accessibility, safety, and clinical context. A circulating tumor DNA (ctDNA) testing may also be considered for identifying gene mutations. This technique may not reliably identify gene fusions or rearrangements depending on the panel used and the specific partner gene.

BIL-B (2 of 8)

- Table 1, last row added: *NRG1* gene fusion (Also for Table 2 on BIL-B 3 of 8)
- Footnote e added: Consider RNA-based MGPT to maximize detection of fusion events.

BIL-B (4 of 8)

- *NTRK1/2/3* Gene Fusions
  - Bullet 1 revised: *RNA-based MGPT,* ~~Multi-gene next-generation sequencing (NGS) testing,~~ *is the preferred assay because it has higher sensitivity and accuracy than DNA-based testing for gene fusions, including NTRK1/2/3.* ~~preferably with a transcriptome-based approach, is the preferred assay given the rarity of NTRK fusions in BTCs.~~
- Immunotherapy Biomarkers (MSI-H/dMMR, TMB-H, PD-L1)
  - Bullet 1 revised: ~~There are three possible tests to evaluate~~ Mismatch repair (MMR) protein *expression* deficiency ~~(dMMR) or~~ *and MSI* ~~status~~ *are highly correlated*. *Testing for either or both can be used to guide therapy. MMR protein expression can be assessed by* ~~First,~~ *IHC* staining for MLH1, MSH2, MSH6, and PMS2 *proteins* ~~gene products establishes protein retention or loss~~. If all 4 proteins are retained, it is unlikely the sample will display *MSI*. ~~high rates of DNA mutations in microsatellite regions. Loss of two of the four proteins (typical in MLH1/PMS2 and MSH2/MSH6 pairs) correlates with MSI or MSI-H. Second, NGS determines if there are inactivating mutations in the MMR genes: MLH1, MSH2, MSH6, and PMS2. Mutations associated with nonfunctional MMR proteins correlate with MSI-H status.~~ *Testing for MSI may be accomplished by either clinically validated polymerase chain reaction (PCR) testing or MGPT.* ~~Last, microsatellite repeats of tumor DNA are examined by polymerase chain reaction (PCR). Abnormal microsatellites in two or more regions demonstrates MSI-H status.~~ *MGPT is preferred when other genomic alterations are assessed simultaneously, especially if tissue is limited.* Tumor mutational burden (TMB) *testing* ~~can~~ *should* be ~~tested with~~ performed *using* ~~a~~ clinically validated ~~NGS panel~~ *MGPT with considerations that there can be* ~~but has~~ inherent platform variation.
  - Bullet 2 revised: Recommendation: MSI or MMR ~~deficient~~ testing is recommended in patients with unresectable or metastatic gallbladder cancer, iCCA, or eCCA.

BIL-B (5 of 8)

- *FGFR2* Gene Fusions/Other *FGFR* Pathway Aberrations
  - Bullet 1 revised: *MGPT* ~~Both NGS assays~~, which ~~include~~ *analyzes* the FGFR2 gene with its intronic regions, and break apart fluorescence in situ hybridization (FISH) assay, can be used to identify patients with FGFR2 gene fusions/rearrangements in tumor tissue samples. *However, RNA-based MGPT is preferred for gene fusion detection because of improved sensitivity and the ability to predict the fusion protein.* Some gene fusion breakpoints may be detectable using ctDNA assays, but sensitivity is lower than for tumor tissue testing.
- *IDH1* Mutations
  - Bullet 1 revised: IDH1 mutations in iCCA occur most commonly at codon 132 (R132X). Testing can be performed by *targeted mutation testing or by MGPT, which is preferred when other genomic alterations are assessed simultaneously*. ~~tumor NGS using a multi-gene panel or by hotspot mutation testing~~ ctDNA testing can also detect hotspot mutations in IDH1.

Continued

Version 1.2026, 03/10/26 © 2026 National Comprehensive Cancer Network® (NCCN®), All rights reserved. NCCN Guidelines® and this illustration may not be reproduced in any form without the express written permission of NCCN.

PLEASE NOTE that use of this NCCN Content is governed by the End-User License Agreement, and you MAY NOT distribute this Content or use it with any artificial intelligence model or tool.
Printed by Máximo López Chenlo on 5/4/2026 6:13:37 PM. Copyright © 2026 National Comprehensive Cancer Network, Inc. All Rights Reserved.

Updates in Version 1.2026 of the NCCN Guidelines for Biliary Tract Cancers:

BIL-B (6 of 8)
- NRG1 Gene Fusion: Added testing modalities and considerations and recommendation.
- Other Biomarkers (RET, ROS1, KRAS G12C/Other KRAS, Other Tumor-Agnostic Markers)
  - Bullet 2 revised: Testing for RET gene fusions is recommended for patients with unresectable or metastatic gallbladder cancer, iCCA, or eCCA. ~~A comprehensive NGS panel~~ *MGPT* may identify additional alterations for which biomarker-directed therapies exist and have FDA-approved treatments in other tumor types. *RNA-based MGPT is the preferred approach for gene fusion detection.*

BIL-B (8 of 8)
- Reference 32 added: Harding JJ, Kim JW, Oh DY, et al. Concordance analysis between tumor tissue HER2 status by immunohistochemistry (IHC) and in situ hybridization (ISH) and a translational analysis of plasma ctDNA in patients (pts) with biliary tract cancer (BTC): An exploratory analysis from the phase 2 HERIZON-BTC-01 trial [abstract]. J Clin Oncol 2025;43:Abstract;4102.
- Reference 35 added: Jonna S, Feldman RA, Swensen J,et al. Detection of NRG1 gene fusions in solid tumors. Clin Cancer Res 2019;25:4966-4972.
- Reference 36 added: Schram AM, Goto K, Kim DW, et al. Efficacy of zenocutuzumab in NRG1 fusion-positive cancer. N Engl J Med 2025;392:566-576.
- Reference 37 added: Severson E, Achyut BR, Nesline M, et al. RNA sequencing identifies novel NRG1 fusions in solid tumors that lack co-occurring oncogenic drivers. J Mol Diagn 2023;25:454-466.

BIL-C (1 of 5)
- Footnote b added: For more information regarding DPYD testing, see the NCCN Guidelines for Colon Cancer. (Also for BIL-C 2 of 5)
- Footnote f added: This regimen is commonly followed by chemoradiation in instances where the combination of chemotherapy and chemoradiation is recommended.

BIL-C (3 of 5)
- Primary Treatment for Unresectable and Metastatic Disease
  - Right column
    - Last bullet added: For CCA with *NRG1* gene fusions
      - Zenocutuzumab-zbco was added as a category 2B recommendation.
- Subsequent-Line Therapy for Biliary Tract Cancers if Disease Progression
  - For CCA with *NRG1* gene fusions: Zenocutuzumab-zbco was added as a category 2A recommendation.

BIL-C (4 of 5)
- Reference 10 added: Yoo C, Saborowski A, Hyung J, et al. Liposomal irinotecan for previously treated patients with biliary tract cancer: A pooled analysis of NIFTY and NALIRICC trials. J Hepatol 2025;83:909-916.
- Reference 11 added: Hyung J, Kim I, Kim KP, et al. Treatment with liposomal irinotecan plus fluorouracil and leucovorin for patients with previously treated metastatic biliary tract cancer: the phase 2b NIFTY randomized clinical trial. JAMA Oncol 2023;9:692-699.
- Reference 12 added: Vogel A, Saborowski A, Wenzel P, et al. Nanoliposomal irinotecan and fluorouracil plus leucovorin versus fluorouracil plus leucovorin in patients with cholangiocarcinoma and gallbladder carcinoma previously treated with gemcitabine-based therapies (AIO NALIRICC): A multicentre, open-label, randomised, phase 2 trial. Lancet Gastroenterol Hepatol 2024;9:734-744.
- Reference 19 revised: ~~Solomon BJ, Drilon A, Lin JJ, et al. Repotrectinib in patients with NTRK fusion-positive advanced solid tumors, including non-small cell lung cancer: Update from the phase 1/2 TRIDENT-1 trial [abstract]. Ann Oncol 2023;34:Abstract 1372P.~~ *Besse B, Lin JJ, Bazhenova L, et al. Repotrectinib in NTRK fusion–positive advanced solid tumors: a phase 1/2 trial. Nat Med 2026;32:682-689.*

BIL-C (5 of 5)
- Reference 27 added: Schram AM, Goto K, Kim DW, et al. Efficacy of zenocutuzumab in NRG1 fusion-positive cancer. N Engl J Med 2025;392:566-576.
- Reference 28 added: Schram AM, Cleary JM, Arnold D, et al. Zenocutuzumab efficacy and safety in advanced NRG1+ cholangiocarcinoma: Analysis from the phase 2 eNRGy Trial. Mol Cancer Ther 2025;24:Abstract A102.

BIL-D
- General Principles
  - Last bullet added: Brachytherapy may be considered at experienced centers.
- Reference 9 added: Ostwal V, Patkar S, Engineer R, et al. Adjuvant gemcitabine plus cisplatin and chemoradiation in patients with gallbladder cancer: A randomized clinical trial. JAMA Oncol 2024;10:1116-1120.
- Reference 10 added: Li Z, Taner T, Eaton JE, et al. Development of the perihilar cholangiocarcinoma risk estimation of tumor recurrence after transplant (PRETREAT) score. Ann Surg 2025;282:503-514.

Version 1.2026, 03/10/26 © 2026 National Comprehensive Cancer Network® (NCCN®), All rights reserved. NCCN Guidelines® and this illustration may not be reproduced in any form without the express written permission of NCCN.

PLEASE NOTE that use of this NCCN Content is governed by the End-User License Agreement, and you MAY NOT distribute this Content or use it with any artificial intelligence model or tool.
Printed by Máximo López Chenlo on 5/4/2026 6:13:37 PM. Copyright © 2026 National Comprehensive Cancer Network, Inc. All Rights Reserved.

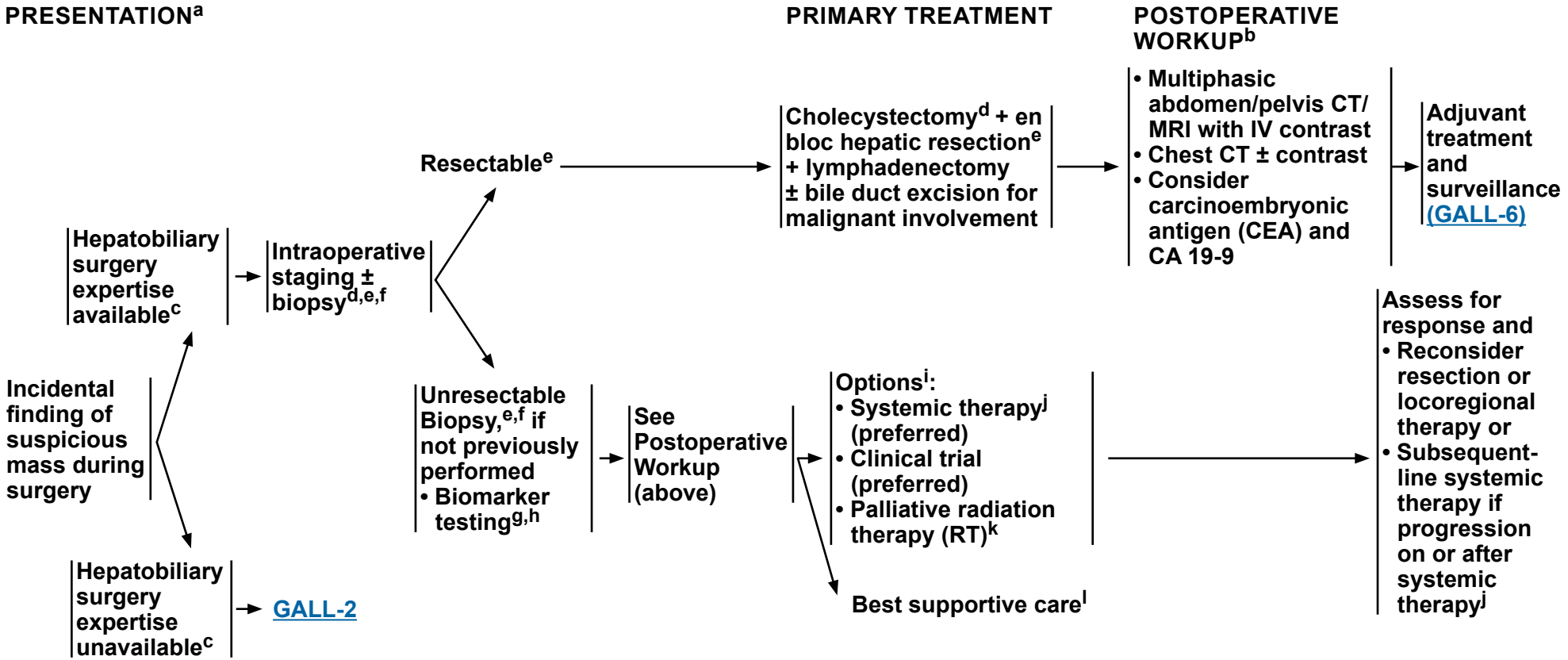

[a] Refer to the NCCN Distress Thermometer and Problem List, which includes social determinants of health. This tool can be utilized throughout the patient's care continuum. See NCCN Guidelines for Distress Management (DIS-A).
[b] Principles of Imaging (BIL-A).
[c] If expertise unavailable or resectability unclear, visually inspect the abdomen, document all findings, and refer to surgeon with hepatobiliary expertise and/or proceed with staging.
[d] Principles of Surgery (GALL-A).
[e] Principles of Pathology (GALL-B).
[f] Core biopsy is preferred over fine-needle aspiration (FNA).
[g] For patients with mismatch repair deficient (dMMR)/microsatellite instability-high (MSI-H) tumors or a family history suggestive of *BRCA1/2* pathogenic variants (PVs), consider germline testing and/or referral to a genetic counselor.
[h] Principles of Biomarker Testing (BIL-B).
[i] Order does not indicate preference. The choice of treatment modality may depend on extent/location of disease and institutional capabilities.
[j] Principles of Systemic Therapy (BIL-C).
[k] Principles of Radiation Therapy (BIL-D).
[l] NCCN Guidelines for Palliative Care.

Other Clinical Presentations
GALL-3, GALL-4, and GALL-5

Note: All recommendations are category 2A unless otherwise indicated.

Version 1.2026, 03/10/26 © 2026 National Comprehensive Cancer Network® (NCCN®), All rights reserved. NCCN Guidelines® and this illustration may not be reproduced in any form without the express written permission of NCCN.

PLEASE NOTE that use of this NCCN Content is governed by the End-User License Agreement, and you MAY NOT distribute this Content or use it with any artificial intelligence model or tool.
Printed by Máximo López Chenlo on 5/4/2026 6:13:37 PM. Copyright © 2026 National Comprehensive Cancer Network, Inc. All Rights Reserved.

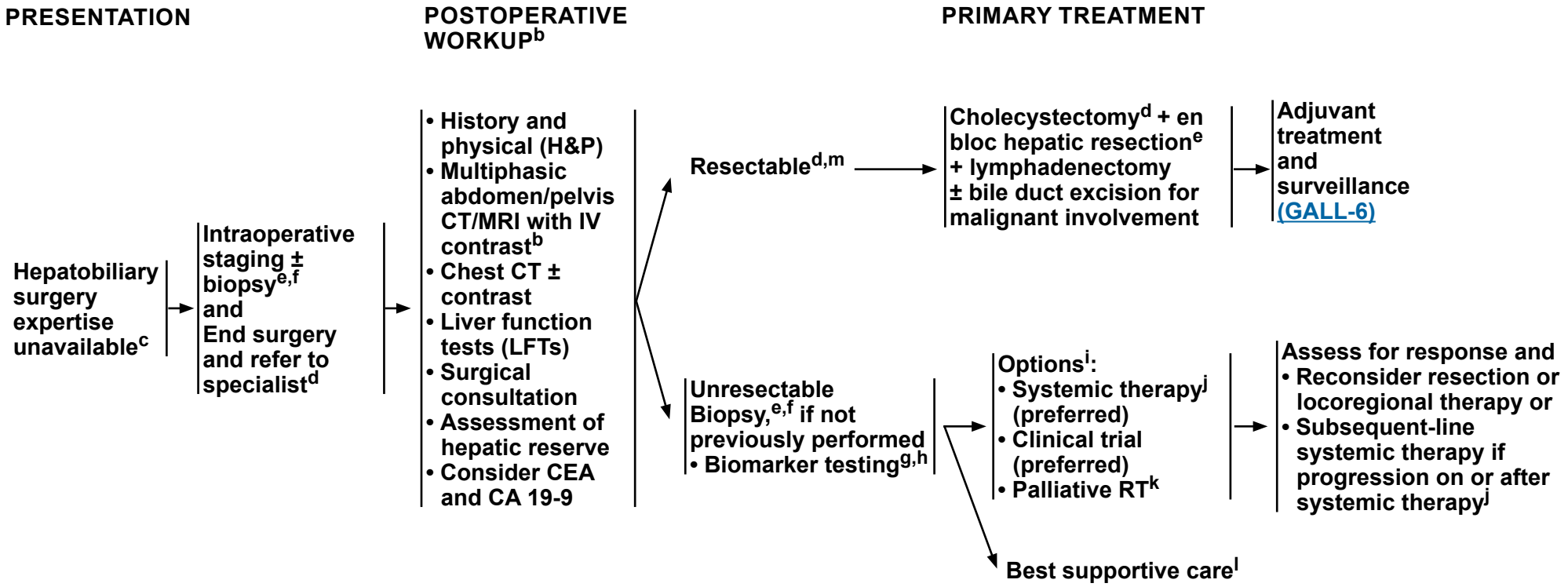

[b] Principles of Imaging (BIL-A).
[c] If expertise unavailable or resectability unclear, visually inspect the abdomen, document all findings, and refer to surgeon with hepatobiliary expertise and/or proceed with staging.
[d] Principles of Surgery (GALL-A).
[e] Principles of Pathology (GALL-B).
[f] Core biopsy is preferred over FNA.
[g] For patients with dMMR/MSI-H tumors or a family history suggestive of *BRCA1/2* PVs, consider germline testing and/or referral to a genetic counselor.
[h] Principles of Biomarker Testing (BIL-B).
[i] Order does not indicate preference. The choice of treatment modality may depend on extent/location of disease and institutional capabilities.
[j] Principles of Systemic Therapy (BIL-C).
[k] Principles of Radiation Therapy (BIL-D).
[l] NCCN Guidelines for Palliative Care.
[m] For locoregionally advanced disease, consider neoadjuvant systemic therapy to rule out rapid progression and avoid futile surgery. There are limited clinical trial data to define a standard regimen or definitive benefit. See Principles of Systemic Therapy (BIL-C).

Note: All recommendations are category 2A unless otherwise indicated.

Version 1.2026, 03/10/26 © 2026 National Comprehensive Cancer Network® (NCCN®), All rights reserved. NCCN Guidelines® and this illustration may not be reproduced in any form without the express written permission of NCCN.

PLEASE NOTE that use of this NCCN Content is governed by the End-User License Agreement, and you MAY NOT distribute this Content or use it with any artificial intelligence model or tool.
Printed by Máximo López Chenlo on 5/4/2026 6:13:37 PM. Copyright © 2026 National Comprehensive Cancer Network, Inc. All Rights Reserved.

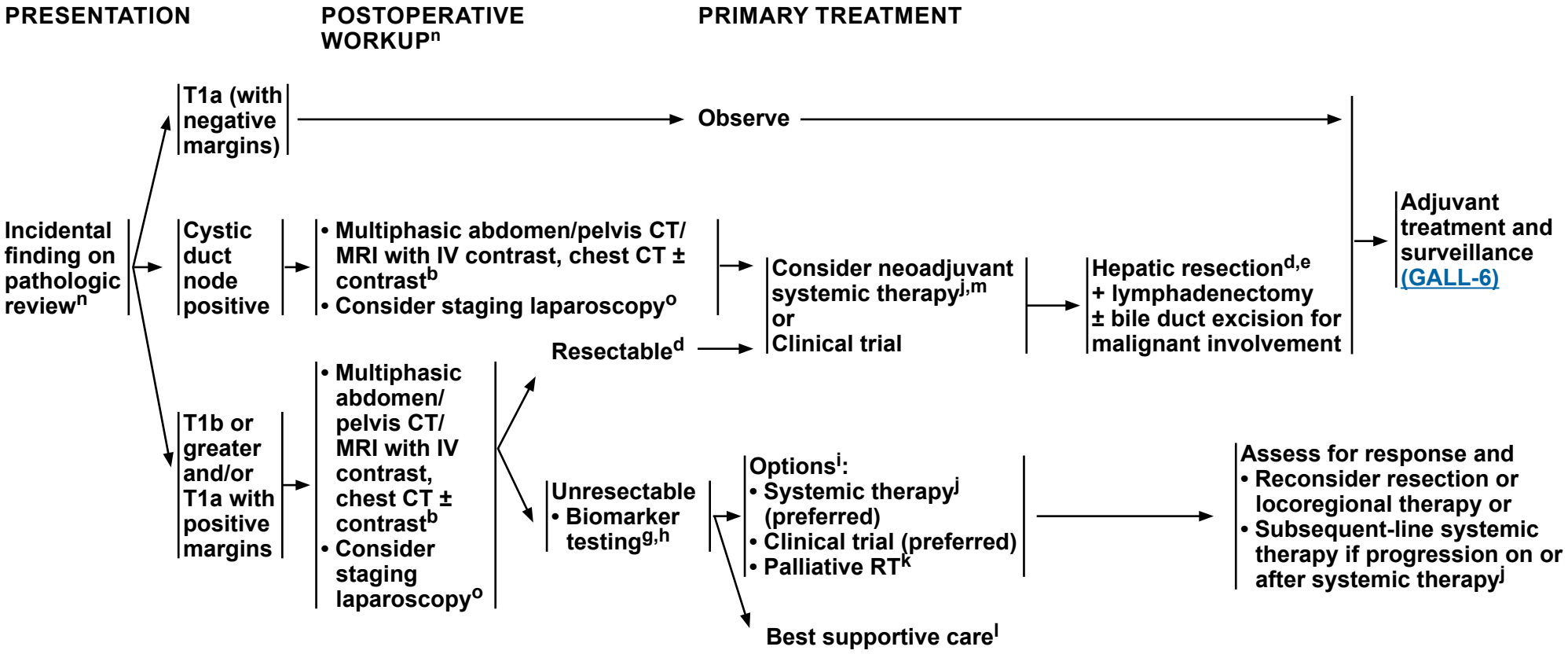

[b] Principles of Imaging (BIL-A).
[d] Principles of Surgery (GALL-A).
[e] Principles of Pathology (GALL-B).
[g] For patients with dMMR/MSI-H tumors or a family history suggestive of *BRCA1/2* PVs, consider germline testing and/or referral to a genetic counselor.
[h] Principles of Biomarker Testing (BIL-B).
[i] Order does not indicate preference. The choice of treatment modality may depend on extent/location of disease and institutional capabilities.
[j] Principles of Systemic Therapy (BIL-C).
[k] Principles of Radiation Therapy (BIL-D).
[l] NCCN Guidelines for Palliative Care.
[m] For locoregionally advanced disease, consider neoadjuvant systemic therapy to rule out rapid progression and avoid futile surgery. There are limited clinical trial data to define a standard regimen or definitive benefit. See Principles of Systemic Therapy (BIL-C).
[n] Consider multidisciplinary review.
[o] Butte JM, et al. HPB (Oxford) 2011;13:463-472.

Other Clinical Presentations
GALL-4 and GALL-5

Note: All recommendations are category 2A unless otherwise indicated.

Version 1.2026, 03/10/26 © 2026 National Comprehensive Cancer Network® (NCCN®), All rights reserved. NCCN Guidelines® and this illustration may not be reproduced in any form without the express written permission of NCCN.

PLEASE NOTE that use of this NCCN Content is governed by the End-User License Agreement, and you MAY NOT distribute this Content or use it with any artificial intelligence model or tool.
Printed by Máximo López Chenlo on 5/4/2026 6:13:37 PM. Copyright © 2026 National Comprehensive Cancer Network, Inc. All Rights Reserved.

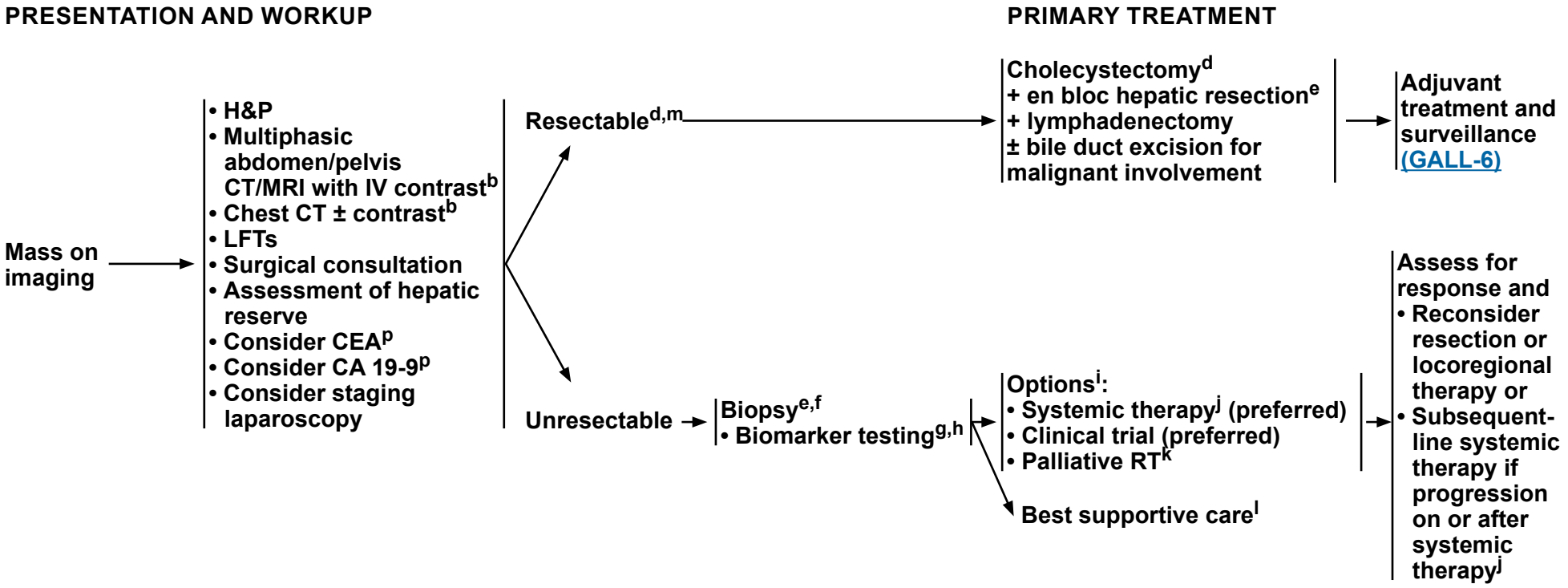

[b] Principles of Imaging (BIL-A).
[d] Principles of Surgery (GALL-A).
[e] Principles of Pathology (GALL-B).
[f] Core biopsy is preferred over FNA.
[g] For patients with dMMR/MSI-H tumors or a family history suggestive of *BRCA1/2* PVs, consider germline testing and/or referral to a genetic counselor.
[h] Principles of Biomarker Testing (BIL-B).
[i] Order does not indicate preference. The choice of treatment modality may depend on extent/location of disease and institutional capabilities.
[j] Principles of Systemic Therapy (BIL-C).
[k] Principles of Radiation Therapy (BIL-D).
[l] NCCN Guidelines for Palliative Care.
[m] For locoregionally advanced disease, consider neoadjuvant systemic therapy to rule out rapid progression and avoid futile surgery. There are limited clinical trial data to define a standard regimen or definitive benefit. See Principles of Systemic Therapy (BIL-C).
[p] CEA and CA 19-9 are baseline tests and should not be done to confirm diagnosis.

Other Clinical Presentations
GALL-1, GALL-3, and GALL-5

Note: All recommendations are category 2A unless otherwise indicated.

Version 1.2026, 03/10/26 © 2026 National Comprehensive Cancer Network® (NCCN®), All rights reserved. NCCN Guidelines® and this illustration may not be reproduced in any form without the express written permission of NCCN.

PLEASE NOTE that use of this NCCN Content is governed by the End-User License Agreement, and you MAY NOT distribute this Content or use it with any artificial intelligence model or tool.
Printed by Máximo López Chenlo on 5/4/2026 6:13:37 PM. Copyright © 2026 National Comprehensive Cancer Network, Inc. All Rights Reserved.

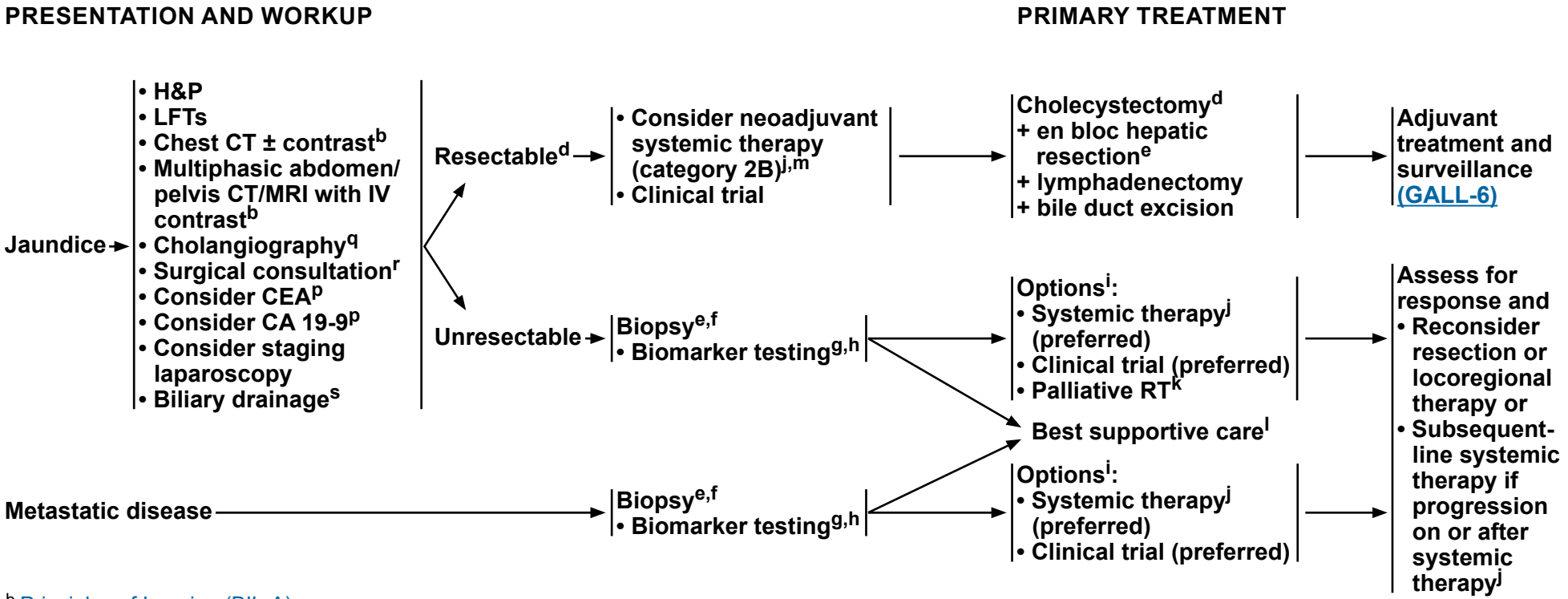

[b] Principles of Imaging (BIL-A).
[d] Principles of Surgery (GALL-A).
[e] Principles of Pathology (GALL-B).
[f] Core biopsy is preferred over FNA.
[g] For patients with dMMR/MSI-H tumors or a family history suggestive of *BRCA1/2* PVs, consider germline testing and/or referral to a genetic counselor.
[h] Principles of Biomarker Testing (BIL-B).
[i] Order does not indicate preference. The choice of treatment modality may depend on extent/location of disease and institutional capabilities.
[j] Principles of Systemic Therapy (BIL-C).
[k] Principles of Radiation Therapy (BIL-D).
[l] NCCN Guidelines for Palliative Care.
[m] For locoregionally advanced disease, consider neoadjuvant systemic therapy to rule out rapid progression and avoid futile surgery. There are limited clinical trial data to define a standard regimen or definitive benefit. See Principles of Systemic Therapy (BIL-C).
[p] CEA and CA 19-9 are baseline tests and should not be done to confirm diagnosis.
[q] Magnetic resonance cholangiopancreatography (MRCP) is preferred. Endoscopic retrograde cholangiopancreatography/percutaneous transhepatic cholangiography (ERCP/PTC) are used more for therapeutic intervention.
[r] Consult with a multidisciplinary team.
[s] Consider biliary drainage for patients with jaundice prior to resection and systemic therapy. Consider baseline CA 19-9 after biliary decompression.

Note: All recommendations are category 2A unless otherwise indicated.

Other Clinical Presentations GALL-3 and GALL-4

Version 1.2026, 03/10/26 © 2026 National Comprehensive Cancer Network® (NCCN®), All rights reserved. NCCN Guidelines® and this illustration may not be reproduced in any form without the express written permission of NCCN.

PLEASE NOTE that use of this NCCN Content is governed by the End-User License Agreement, and you MAY NOT distribute this Content or use it with any artificial intelligence model or tool.
Printed by Máximo López Chenlo on 5/4/2026 6:13:37 PM. Copyright © 2026 National Comprehensive Cancer Network, Inc. All Rights Reserved.

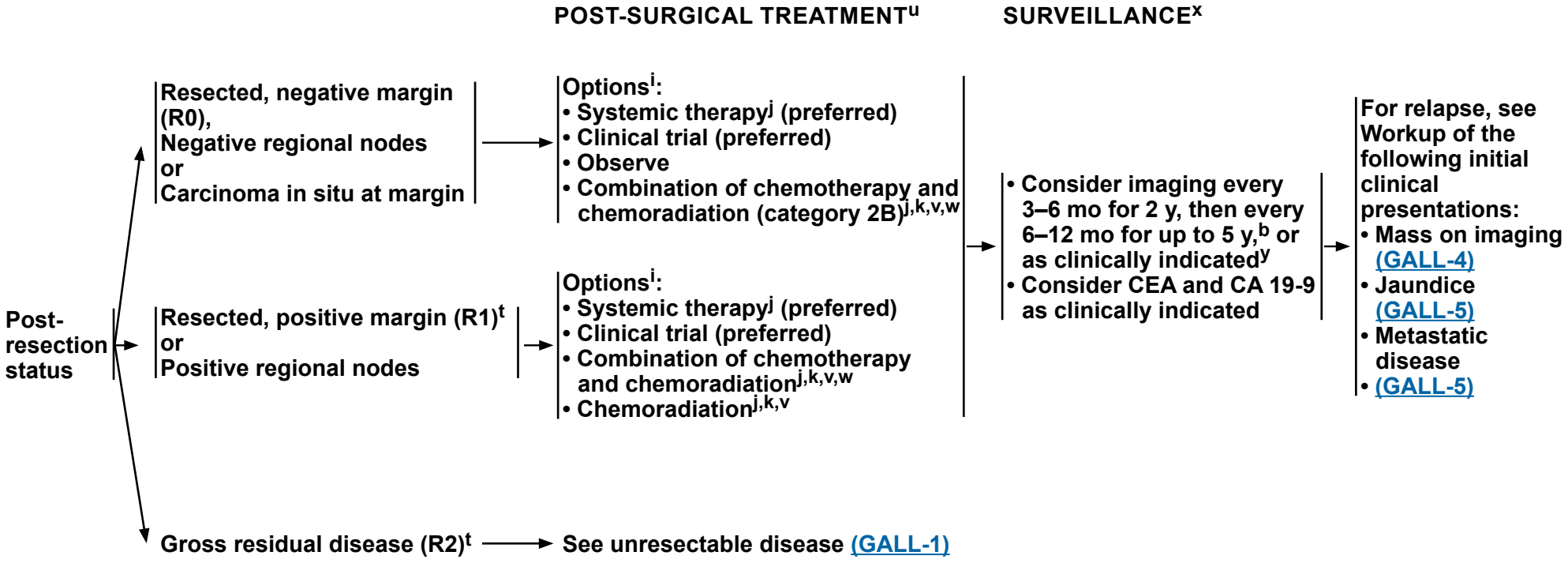

[b] Principles of Imaging (BIL-A).
[i] Order does not indicate preference. The choice of treatment modality may depend on extent/location of disease and institutional capabilities.
[j] Principles of Systemic Therapy (BIL-C).
[k] Principles of Radiation Therapy (BIL-D).
[t] Management of disease in patients with R1 or R2 resections should be evaluated by a multidisciplinary team.
[u] Adjuvant chemotherapy or chemoradiation has been associated with survival benefit in patients with biliary tract cancer (BTC), especially in patients with lymph node-positive disease (Horgan AM, et al. J Clin Oncol 2012;30:1934-1940).
[v] There are limited clinical trial data to define a standard regimen or definitive benefit. Clinical trial participation is encouraged. (Macdonald OK, et al. Surg Oncol Clin N Am 2002;11:941-954).
[w] For a list of gemcitabine-based regimens and fluoropyrimidine-based regimens to be used before or after chemoradiation, see Adjuvant Chemotherapy (BIL-C, 1 of 5).
[x] There are no data to support a specific surveillance schedule or tests for monitoring. Physicians should discuss appropriate follow-up schedules/imaging with patients.
[y] Based on surveillance schedule used in the phase III BILCAP trial. Primrose JN, et al. Lancet Oncol 2019;20:663-673.

Note: All recommendations are category 2A unless otherwise indicated.

Version 1.2026, 03/10/26 © 2026 National Comprehensive Cancer Network® (NCCN®), All rights reserved. NCCN Guidelines® and this illustration may not be reproduced in any form without the express written permission of NCCN.

PLEASE NOTE that use of this NCCN Content is governed by the End-User License Agreement, and you MAY NOT distribute this Content or use it with any artificial intelligence model or tool.
Printed by Máximo López Chenlo on 5/4/2026 6:13:37 PM. Copyright © 2026 National Comprehensive Cancer Network, Inc. All Rights Reserved.

PRINCIPLES OF SURGERY

Incidental Finding of Suspicious Mass During Surgery:
- If expertise is unavailable, document all relevant findings and refer the patient to a center with available expertise. If there is a suspicious mass, a biopsy is not necessary as this can result in peritoneal dissemination.
- If expertise is available and there is convincing clinical evidence of cancer, a definitive resection[a] can be performed as written below. If the diagnosis is not clear, frozen section biopsies can be considered in selected cases before proceeding with definitive resection. If malignancy is suspected or confirmed after cholecystectomy has been initiated and expertise is available, then definitive resection should be undertaken.
- If malignancy is suspected before cholecystectomy has begun and there is a question of resectability (ie, locally advanced, possible metastatic disease, other), then definitive resection can be postponed, regardless of available expertise, until complete staging and evaluation has been performed. Document all findings and consider biopsy[a] if chemotherapy is anticipated.
- The principles of resection are the same as below consisting of radical cholecystectomy including segments IV B and V and lymphadenectomy and extended hepatic or biliary resection as necessary to obtain a negative margin.
- Consider neoadjuvant systemic therapy for locoregionally advanced disease to rule out rapid progression and avoid futile surgery (biopsy required).
- Minimally invasive approaches by experienced surgeons have been proven to be safe and effective for well-selected cases.

Incidental Finding on Pathologic Review:
- Consider pathologic re-review by a hepatobiliary pathology expert[a] and/or speak to surgeon to check for completeness of cholecystectomy, signs of disseminated disease, location of tumor, and any other pertinent information. Review the pathology report for T stage, cystic duct margin status, and other margins.
- Diagnostic laparoscopy can be performed but is of relatively low yield. Higher yields may be seen in patients with T3 or higher tumors, poorly differentiated tumors, or with a margin-positive cholecystectomy. Diagnostic laparoscopy should also be considered in patients with any suspicion of metastatic disease on imaging that is not amenable to percutaneous biopsy.[1]
- Repeat cross-sectional imaging of the chest, abdomen, and pelvis should be performed prior to definitive resection.
- Initial exploration should rule out distant lymph node metastases in the celiac axis or aorto-caval groove as these contraindicate further resection.
- Hepatic resection[a] should be performed to obtain clear margins, which usually consists of segments IV B and V. Extended resections beyond segments IV B and V may be needed in some patients to obtain negative margins.
- Lymphadenectomy should be performed to clear all lymph nodes in the porta hepatis.
- Resection of the bile duct may be needed to obtain negative margins. Routine resection of the bile duct for lymphadenectomy has been shown to increase morbidity without convincing evidence for improved survival.[2,3]
- Port site resection has not been shown to be effective, as the presence of a port site implant is a surrogate marker of underlying disseminated disease and has not been shown to improve outcomes.[4]
- Consider neoadjuvant systemic therapy for locoregionally advanced disease to rule out rapid progression and avoid futile surgery.

Footnote
[a] Principles of Pathology (GALL-B).

References
[1] Butte JM, Gonen M, Allen PJ, et al. The role of laparoscopic staging in patients with incidental gallbladder cancer. HPB (Oxford) 2011;13:463-472.
[2] Fuks D, Regimbeau JM, Le Treut YP, et al. Incidental gallbladder cancer by the AFC-GBC-2009 Study Group. World J Surg 2011;35:1887-1897.
[3] D'Angelica M, Dalal KM, Dematteo RP, et al. Analysis of extent of resection for adenocarcinoma of gallbladder. Ann Surg Oncol 2009;16:806-816.
[4] Maker AV, Butte JM, Oxenberg J, et al. Is port site resection necessary in the surgical management of gallbladder cancer. Ann Surg Oncol 2012;19:409-417.

Note: All recommendations are category 2A unless otherwise indicated.

Version 1.2026, 03/10/26 © 2026 National Comprehensive Cancer Network® (NCCN®), All rights reserved. NCCN Guidelines® and this illustration may not be reproduced in any form without the express written permission of NCCN.

PLEASE NOTE that use of this NCCN Content is governed by the End-User License Agreement, and you MAY NOT distribute this Content or use it with any artificial intelligence model or tool.
Printed by Máximo López Chenlo on 5/4/2026 6:13:37 PM. Copyright © 2026 National Comprehensive Cancer Network, Inc. All Rights Reserved.

PRINCIPLES OF SURGERY

Mass on Imaging: Patients Presenting with Gallbladder Mass/Disease Suspicious for Gallbladder Cancer

- Staging should be carried out with multiphasic cross-sectional imaging of the liver with chest, abdomen, and pelvis CT.
- If there is a suspicious mass, a biopsy is not necessary and a definitive resection[a] should be carried out.
- Diagnostic laparoscopy is recommended prior to definitive resection.
- In selected cases where the diagnosis is not clear it may be reasonable to perform a cholecystectomy (including intraoperative frozen section) followed by the definitive resection during the same setting if pathology confirms cancer.
- The resection is carried out as per the principles described above.
- Consider neoadjuvant systemic therapy for locoregionally advanced disease to rule out rapid progression and avoid futile surgery (biopsy required).

Gallbladder Cancer and Jaundice

- The presence of jaundice in gallbladder cancer usually portends a poor prognosis.[5-7]
- Although a relative contraindication, in select patients curative intent resection[a] can be attempted for resectable disease in centers with available expertise.
- Consider neoadjuvant systemic therapy for locoregionally advanced disease to rule out rapid progression and avoid futile surgery.

Footnote

[a] Principles of Pathology (GALL-B).

References

[5] Hawkins WG, DeMatteo RP, Jarnagin WR, et al. Jaundice predicts advanced disease and early mortality in patients with gallbladder cancer. Ann Surg Oncol 2004;11:310-315.
[6] Regimbeau JM, Fuks D, Bachellier P, et al. Prognostic value of jaundice in patients with gallbladder cancer by the AFC -GBC-2009 study group. Eur J Surg Oncol 2011;37:505-512.
[7] Nishio H, Ebata T, Yokoyama Y, et al. Gallbladder cancer involving the extrahepatic bile duct is worthy of resection. Ann Surg 2011;253:953-960.

Note: All recommendations are category 2A unless otherwise indicated.

Version 1.2026, 03/10/26 © 2026 National Comprehensive Cancer Network® (NCCN®), All rights reserved. NCCN Guidelines® and this illustration may not be reproduced in any form without the express written permission of NCCN.

PLEASE NOTE that use of this NCCN Content is governed by the End-User License Agreement, and you MAY NOT distribute this Content or use it with any artificial intelligence model or tool.
Printed by Máximo López Chenlo on 5/4/2026 6:13:37 PM. Copyright © 2026 National Comprehensive Cancer Network, Inc. All Rights Reserved.

PRINCIPLES OF PATHOLOGY
GALLBLADDER CANCER APPROPRIATE FOR RESECTION

Staging for Diagnosis and Prognosis of Primary Gallbladder Cancer

Pathologic Staging

The following parameters should be reported for cancer with histopathologic type:

- Reported parameters
  - Carcinoma in situ/high-grade dysplasia
  - Tumor depth of invasion into or through (T stage)
    - Lamina propria
    - Muscular layer
    - Perimuscular connective tissue on the peritoneal side and/or on the hepatic side
    - Serosa (visceral peritoneum)
    - Main portal vein or hepatic artery
    - Liver
    - Adjacent organ or structure, such as the stomach, duodenum, colon, pancreas, omentum, or extrahepatic bile ducts
  - Number of regional lymph nodes (N stage)
  - Distant organ (M stage)
  - Adequate sample[1]
    - Identify individual blocks containing malignant tissue and non-malignant tissue ideal for further testing
    - Core biopsy is preferred over fine-needle aspiration (FNA)

If Adequate Sample Available

- Histopathologic types of gallbladder carcinoma[a,b]

- Background liver disease and staging of fibrosis
  - Indicate the presence or absence of chronic liver disease (eg, viral hepatitis, metabolic dysfunction-associated steatotic liver disease [MASLD], metabolic disorder) either from the clinical history or histopathologic changes.
  - Report the degree of fibrosis and the presence or absence of cirrhosis.

Footnotes

[a] Well-differentiated neuroendocrine tumor is not staged as a gallbladder carcinoma.

[b] For rare histologies with distinct systemic therapy options (such as pure neuroendocrine tumors or sarcomas), recommend treatment according to the relevant NCCN Guideline for those tumor histologic types.

Reference

[1] College of American Pathologists. Protocol for the examination of specimens from patients with carcinoma of the gallbladder. 2021. Accessed January 2, 2024.

Note: All recommendations are category 2A unless otherwise indicated.

Version 1.2026, 03/10/26 © 2026 National Comprehensive Cancer Network® (NCCN®), All rights reserved. NCCN Guidelines® and this illustration may not be reproduced in any form without the express written permission of NCCN.

PLEASE NOTE that use of this NCCN Content is governed by the End-User License Agreement, and you MAY NOT distribute this Content or use it with any artificial intelligence model or tool.
Printed by Máximo López Chenlo on 5/4/2026 6:13:37 PM. Copyright © 2026 National Comprehensive Cancer Network, Inc. All Rights Reserved.

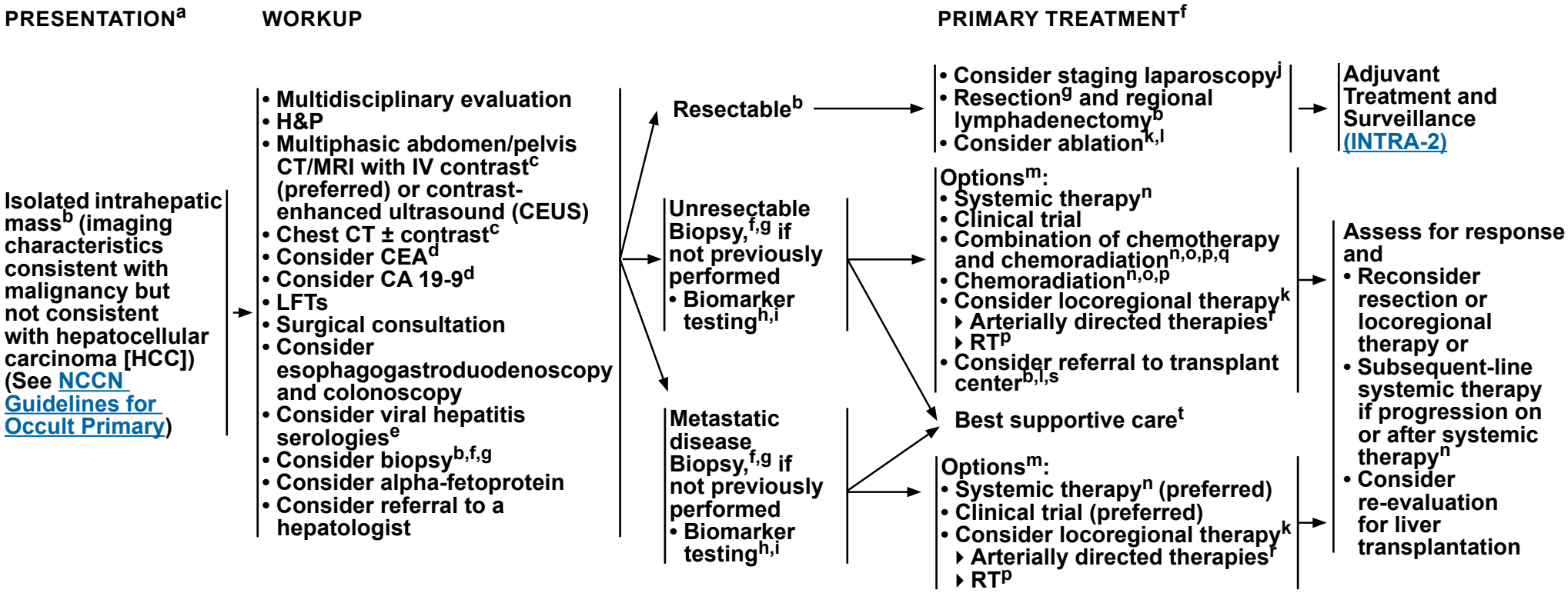

[a] Refer to the NCCN Distress Thermometer and Problem List, which includes social determinants of health. See NCCN Guidelines for Distress Management (DIS-A).
[b] Principles of Surgery (INTRA-A).
[c] Principles of Imaging (BIL-A).
[d] CEA and CA 19-9 are baseline tests and should not be done to confirm diagnosis.
[e] ASCO guidelines for management of viral hepatitis B virus (HBV) in patients with cancer/receiving chemotherapy: Hwang JP, et al. J Clin Oncol 2020;38:3698-3715.
[f] Principles of Mixed HCC-CCA (INTRA-B).
[g] Principles of Pathology (INTRA-C).
[h] For patients with dMMR/MSI-H tumors or a family history suggestive of *BRCA1/2* PVs, consider germline testing and/or referral to a genetic counselor.
[i] Principles of Biomarker Testing (BIL-B).
[j] Laparoscopy may be done in conjunction with surgery if no distant metastases are found.
[k] Principles of Principles of Arterial/Locoregional Therapy for Intrahepatic Cholangiocarcinoma (INTRA-D).
[l] For small single tumors <3 cm.
[m] Order does not indicate preference. The choice of treatment modality may depend on extent/location of disease and institutional capabilities.
[n] Principles of Systemic Therapy (BIL-C).
[o] There are limited clinical trial data to define a standard regimen or definitive benefit. Participation in clinical trials is encouraged (Macdonald OK, et al. Surg Oncol Clin N Am 2002;11:941-954).
[p] Principles of Radiation Therapy (BIL-D).
[q] For a list of gemcitabine-based regimens and fluoropyrimidine-based regimens to be used before or after chemoradiation, see Adjuvant Chemotherapy (BIL-C, 1 of 5).
[r] Hepatic arterial infusion chemotherapy (with or without systemic chemotherapy) may be used in a clinical trial or at experienced centers in carefully selected cases.
[s] Patients who meet the following criteria will be eligible for transplant exception points: biopsy-proven intrahepatic cholangiocarcinoma (iCCA) or mixed HCC-iCCA, presence of cirrhosis, unresectable, received locoregional or systemic therapy, and 6 months from time of diagnosis or last treatment with no new lesions or extrahepatic disease. Consider referral to hepatologist.
[t] NCCN Guidelines for Palliative Care.

Note: All recommendations are category 2A unless otherwise indicated.

Version 1.2026, 03/10/26 © 2026 National Comprehensive Cancer Network® (NCCN®), All rights reserved. NCCN Guidelines® and this illustration may not be reproduced in any form without the express written permission of NCCN.

PLEASE NOTE that use of this NCCN Content is governed by the End-User License Agreement, and you MAY NOT distribute this Content or use it with any artificial intelligence model or tool.
Printed by Máximo López Chenlo on 5/4/2026 6:13:37 PM. Copyright © 2026 National Comprehensive Cancer Network, Inc. All Rights Reserved.

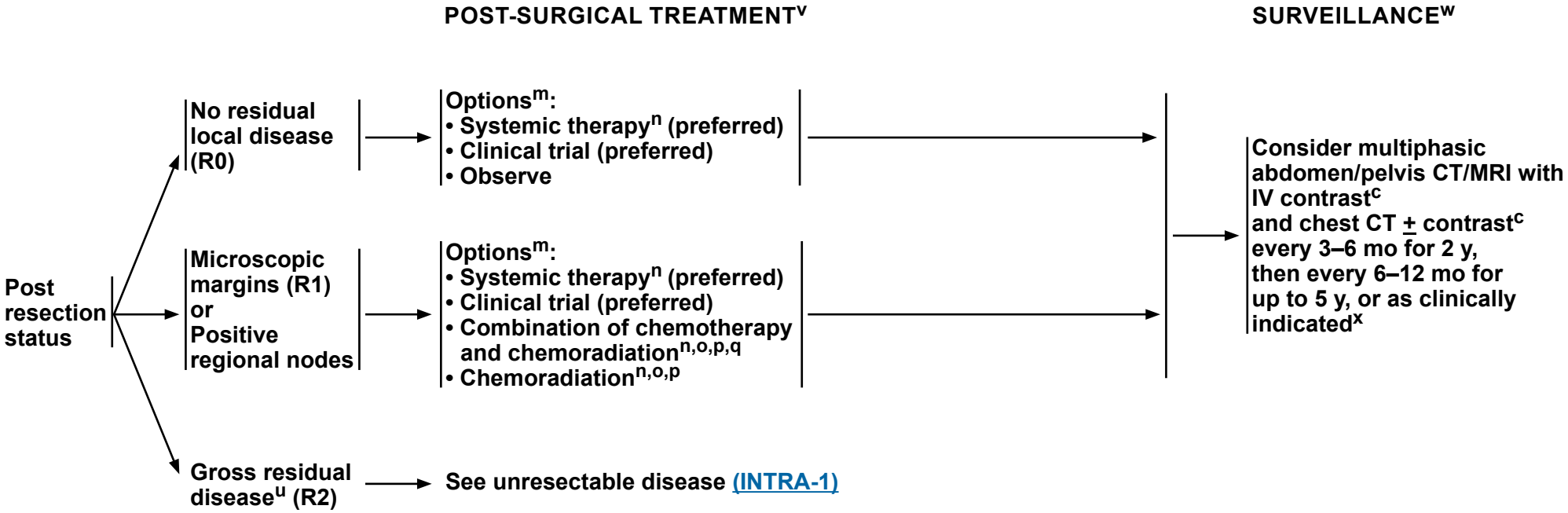

[c] Principles of Imaging (BIL-A).
[m] Order does not indicate preference. The choice of treatment modality may depend on extent/location of disease and institutional capabilities.
[n] Principles of Systemic Therapy (BIL-C).
[o] There are limited clinical trial data to define a standard regimen or definitive benefit. Clinical trial participation is encouraged (Macdonald OK, et al. Surg Oncol Clin N Am 2002;11:941-954).
[p] Principles of Radiation Therapy (BIL-D).
[q] For a list of gemcitabine-based regimens and fluoropyrimidine-based regimens to be used before or after chemoradiation, see Adjuvant Chemotherapy (BIL-C, 1 of 5).
[u] Consult with multidisciplinary team.
[v] Adjuvant chemotherapy or chemoradiation has been associated with survival benefit in patients with BTC, especially in patients with lymph node-positive disease (Horgan AM, et al. J Clin Oncol 2012;30:1934-1940).
[w] There are no data to support a specific surveillance schedule or tests for monitoring. Physicians should discuss appropriate follow-up schedules/imaging with patients.
[x] Based on surveillance schedule used in the phase III BILCAP trial. Primrose JN, et al. Lancet Oncol 2019;20:663-673.

Note: All recommendations are category 2A unless otherwise indicated.

Version 1.2026, 03/10/26 © 2026 National Comprehensive Cancer Network® (NCCN®), All rights reserved. NCCN Guidelines® and this illustration may not be reproduced in any form without the express written permission of NCCN.

PLEASE NOTE that use of this NCCN Content is governed by the End-User License Agreement, and you MAY NOT distribute this Content or use it with any artificial intelligence model or tool.
Printed by Máximo López Chenlo on 5/4/2026 6:13:37 PM. Copyright © 2026 National Comprehensive Cancer Network, Inc. All Rights Reserved.

PRINCIPLES OF SURGERY[1,2]

General Principles

- A preoperative biopsy is not always necessary before proceeding with a definitive, potentially curative resection. A suspicious mass on imaging in the proper clinical setting should be treated as malignant.
- Diagnostic laparoscopy to rule out unresectable disseminated disease should be considered.
- Initial exploration should assess for multifocal hepatic disease, lymph node metastases, and distant metastases. Lymph node metastases beyond the porta hepatis and distant metastatic disease contraindicate resection.
- Hepatic resection with negative margins is the goal of surgical therapy. While major resections are often necessary, wedge resections and segmental resections are all appropriate given that a negative margin can be achieved.
- A regional lymphadenectomy of the porta hepatis is carried out.
- Multifocal liver disease is generally representative of metastatic disease and is a contraindication to resection. In highly selected cases with limited multifocal disease resection can be considered.
- Gross lymph node metastases to the porta hepatis portend a poor prognosis and resection should only be considered in highly selected cases.
- Minimally invasive approaches by experienced surgeons have been proven to be safe and effective for well-selected cases.

[1] Endo I, Gonen M, Yopp A. Intrahepatic cholangiocarcinoma: Rising frequency, improved survival and determinants of outcome after resection. Ann Surg 2008;248:84-96.
[2] de Jong MC, Nathan H, Sotiropoulos GC. Intrahepatic cholangiocarcinoma: an international multi-institutional analysis of prognostic factors and lymph node assessment. J Clin Oncol 2011;29:3140-3145.

Note: All recommendations are category 2A unless otherwise indicated.

Version 1.2026, 03/10/26 © 2026 National Comprehensive Cancer Network® (NCCN®), All rights reserved. NCCN Guidelines® and this illustration may not be reproduced in any form without the express written permission of NCCN.

PLEASE NOTE that use of this NCCN Content is governed by the End-User License Agreement, and you MAY NOT distribute this Content or use it with any artificial intelligence model or tool.
Printed by Máximo López Chenlo on 5/4/2026 6:13:37 PM. Copyright © 2026 National Comprehensive Cancer Network, Inc. All Rights Reserved.

PRINCIPLES OF MIXED HCC-CCA

An estimated 1% to 10% of patients with primary liver tumors are found to have a combination of both HCC and cholangiocarcinoma (CCA) histologies on pathologic review.[1-4] In some cases, tumors may contain separate foci of both HCC and CCA histology in discrete areas of a tumor, while in other cases a tumor may be biphenotypic with expression of immunohistochemical (IHC) markers associated independently with HCC and CCA but co-expressed on the same cells. Multigene panel testing (MGPT) of mixed HCC-CCA suggests a higher prevalence of genomic alterations more commonly associated with HCC than CCA (such as presence of *TP53* and *TERT* promoter mutations), particularly in patients with underlying hepatitis C virus (HCV) infection, but interpretation of these results is limited by small sample sizes.[3,5]

Liver resection is considered the standard treatment for resectable mixed HCC-CCA.[6] Though prospective data are lacking, liver-directed locoregional therapies may be appropriate for patients with a limited extent of unresectable hepatic disease, similar to management algorithms for HCC and intrahepatic CCA (iCCA) (see NCCN Guidelines for Hepatocellular Carcinoma and INTRA-1).

Patients with HCC-CCA that is limited in size based on center-specific criteria used should be considered for evaluation in a transplant center.

In patients with metastatic or locally advanced recurrence after a prior resection or local therapies for mixed HCC-CCA, a repeat biopsy[a] should be considered to ascertain the dominant histology at recurrence. If the biopsy at recurrence suggests an isolated recurrence of either the HCC or CCA component, the Panel would consider a systemic therapy option appropriate for that histologic component.

Tumor MGPT should be considered in all patients with advanced stages of mixed HCC-CCA tumors to identify potential targetable alterations, which are associated with CCA (BIL-B, BIL-C).

For patients with histologic evidence of mixed HCC-CCA at advanced stages requiring systemic therapy, there are limited prospective data to guide the choice of regimen. A retrospective series of 101 patients with mixed HCC-CCA treated with systemic therapy demonstrated similar overall response rates for patients treated with chemotherapy versus non–chemotherapy-based systemic therapies; there was a trend towards longer median overall survival in patients treated with chemotherapy (15.5 vs. 5.3 months; $P = .052$).[7] Based upon these data as well as the potential for activity of component parts in both histologies, a regimen of cisplatin/gemcitabine chemotherapy combined with either durvalumab or pembrolizumab[b] immunotherapy is an appropriate choice for first-line therapy, noting that these combinations include agents with anti-tumor activity in both CCA[8-10] and HCC histologies.[11-14] At progression, molecularly targeted therapies should be considered if the tumor harbors a targetable aberration. In the absence of a targetable aberration, regimens with demonstrated activity in both HCC and CCA are reasonable options, including the combination of ipilimumab + nivolumab[15,16] or regorafenib.[17,18] A repeat biopsy[a] at tumor progression may be warranted to reassess dominant histology of a progressing lesion, especially if there are discordant areas of response and progression and if the patient remains a candidate for further systemic therapy.

[a] Principles of Pathology (INTRA-C).
[b] Pembrolizumab and berahyaluronidase alfa-pmph subcutaneous injection may be substituted for IV pembrolizumab. Pembrolizumab and berahyaluronidase alfa-pmph has different dosing and administration instructions compared to IV pembrolizumab.

Note: All recommendations are category 2A unless otherwise indicated.

References

Version 1.2026, 03/10/26 © 2026 National Comprehensive Cancer Network® (NCCN®), All rights reserved. NCCN Guidelines® and this illustration may not be reproduced in any form without the express written permission of NCCN.

PLEASE NOTE that use of this NCCN Content is governed by the End-User License Agreement, and you MAY NOT distribute this Content or use it with any artificial intelligence model or tool.
Printed by Máximo López Chenlo on 5/4/2026 6:13:37 PM. Copyright © 2026 National Comprehensive Cancer Network, Inc. All Rights Reserved.

PRINCIPLES OF MIXED HCC-CCA
REFERENCES

[1] Childs A, Zakeri N, Ma YT, et al. Biopsy for advanced hepatocellular carcinoma: Results of a multicentre UK audit. Br J Cancer 2021;125:1350-1355.
[2] Teufel A, Rodriguez I, Winzler C, et al. Clinical characterization of HCC/CCA mixed cancers in a population-based cohort. J Gastrointestin Liver Dis 2023;32:190-196.
[3] Raevskaya O, Appelman H, Razumilava N. A contemporary approach to diagnosis and treatment of combined hepatocellular-cholangiocarcinoma. Curr Hepatol Rep 2020;19:478-485.
[4] Tang Y, Wang L, Teng F, et al. The clinical characteristics and prognostic factors of combined hepatocellular carcinoma and cholangiocarcinoma, hepatocellular carcinoma and intrahepatic cholangiocarcinoma after surgical resection: A propensity score matching analysis. Int J Med Sci 2021;18:187-198.
[5] Joseph NM, Tsokos CG, Umetsu SE, et al. Genomic profiling of combined hepatocellular-cholangiocarcinoma reveals similar genetics to hepatocellular carcinoma. J Pathol 2019;248:164-178.
[6] Claasen MPAW, Ivanics T, Beumer BR, et al. An international multicentre evaluation of treatment strategies for combined hepatocellular-cholangiocarcinoma. JHEP Rep 2023;5:100745.
[7] Pomej K, Balcar L, Shmanko K, et al. Clinical characteristics and outcome of patients with combined hepatocellular-cholangiocarcinoma-a European multicenter cohort. ESMO Open 2023;8:100783.
[8] Kelley RK, Ueno M, Yoo C, et al. Pembrolizumab in combination with gemcitabine and cisplatin compared with gemcitabine and cisplatin alone for patients with advanced biliary tract cancer (KEYNOTE-966): a randomised, double-blind, placebo-controlled, phase 3 trial. Lancet 2023;401:1853-1865
[9] Oh DY, He AR, Qin S, et al. Durvalumab plus gemcitabine and cisplatin in advanced biliary tract cancer. NEJM Evid 2022;1:EVIDoa2200015.
[10] Valle J, Wasan H, Palmer DH, et al. Cisplatin plus gemcitabine versus gemcitabine for biliary tract cancer. N Engl J Med 2010;362:1273-1281.
[11] Abou-Alfa GK, Lau G, Kudo M, et al. Tremelimumab plus durvalumab in unresectable hepatocellular carcinoma. NEJM Evid 2022;1:EVIDoa2100070.
[12] Finn RS, Ryoo BY, Merle P, et al. Pembrolizumab as second-line therapy in patients with advanced hepatocellular carcinoma in KEYNOTE-240: A randomized, double-blind, phase III trial. J Clin Oncol 2020;38:193-202.
[13] Qin S, Chen Z, Fang W, et al. Pembrolizumab versus placebo as second-line therapy in patients from Asia with advanced hepatocellular carcinoma: A randomized, double-blind, phase III trial. J Clin Oncol 2023;41:1434-1443.
[14] Zhu AX, Finn RS, Edeline J, et al. Pembrolizumab in patients with advanced hepatocellular carcinoma previously treated with sorafenib (KEYNOTE-224): A non-randomised, open-label phase 2 trial. Lancet Oncol 2018;19:940-952.
[15] Yau T, Kang YK, Kim TY, et al. Efficacy and safety of nivolumab plus ipilimumab in patients with advanced hepatocellular carcinoma previously treated with sorafenib: The checkmate 040 randomized clinical trial. JAMA Oncol 2020;6:e204564.
[16] Klein O, Kee D, Nagrial A, et al. Evaluation of combination nivolumab and ipilimumab immunotherapy in patients with advanced biliary tract cancers: Subgroup analysis of a phase 2 nonrandomized clinical trial. JAMA Oncol 2020;6:1405-1409.
[17] Bruix J, Qin S, Merle P, et al. Regorafenib for patients with hepatocellular carcinoma who progressed on sorafenib treatment (RESORCE): A randomised, double-blind, placebo-controlled, phase 3 trial. Lancet 2017;389:56-66.
[18] Sun W, Patel A, Normolle D, et al. A phase 2 trial of regorafenib as a single agent in patients with chemotherapy-refractory, advanced, and metastatic biliary tract adenocarcinoma. Cancer 2019;125:902-909.

Note: All recommendations are category 2A unless otherwise indicated.

Version 1.2026, 03/10/26 © 2026 National Comprehensive Cancer Network® (NCCN®), All rights reserved. NCCN Guidelines® and this illustration may not be reproduced in any form without the express written permission of NCCN.

PLEASE NOTE that use of this NCCN Content is governed by the End-User License Agreement, and you MAY NOT distribute this Content or use it with any artificial intelligence model or tool.
Printed by Máximo López Chenlo on 5/4/2026 6:13:37 PM. Copyright © 2026 National Comprehensive Cancer Network, Inc. All Rights Reserved.

PRINCIPLES OF PATHOLOGY

Intrahepatic Cholangiocarcinoma Appropriate for Biopsy

Histologic confirmation of primary hepatic malignancy with cholangiocyte differentiation

- Establish cholangiocyte differentiation by histology and if appropriate supported by IHC and albumin in situ hybridization (ISH) studies. There is overlap in the IHC profiles of these malignancies.
- Report the presence of small vessel invasion, undifferentiated/poor differentiation, and associated component of hepatocyte differentiation (possible combined hepatocellular CCA).

Intrahepatic Cholangiocarcinoma Undergoing Resection

Staging for diagnosis and prognosis of iCCA

These features support but do not definitively lead to a clinical diagnosis.

The following parameters should be reported for cancer with cholangiocyte differentiation[a]:

- Reported parameters
  - Carcinoma in situ/high-grade dysplasia
  - Number and size of tumor(s) (T stage)
  - Number of regional lymph nodes[b] evaluated and infiltrated with malignancy (N stage)
  - Metastatic disease (M stage)
  - Histologic differentiation (small duct type or large duct type)
  - Vascular invasion
  - Perineural invasion
  - Resection margin status
  - Cancer perforation of visceral peritoneum or direct invasion into adjacent extrahepatic structures.
  - If adequate sampling: Identify individual blocks containing malignant tissue and non-malignant tissue ideal for further testing.

If Adequate Sample Available

- Histopathologic types of primary carcinomas of the intrahepatic bile ducts[c,d]

- Evaluation of Nontumor Liver Parenchyma
  - Indicate the presence or absence of chronic liver disease (eg, viral hepatitis, MASLD, metabolic disorder) either from the clinical history or histopathologic changes.
  - Report the degree of fibrosis and the presence or absence of cirrhosis.

[a] Perihilar bile duct cancer, gallbladder cancer, and HCC have separate staging.
[b] Regional lymph nodes include those associated with the hilar hepatic artery, portal vein and cystic duct, inferior phrenic, gastrohepatic, periduodenal, and peripancreatic regions.
[c] A mass-forming type of bile duct cancer is a multinodular distinct mass of cholangiocytes forming malignant glands in a sclerotic stroma and well-demarcated borders. Periductal growth type is characterized by poorly defined borders and a linear growth pattern likely along an intermediate or larger native bile duct.
[d] For rare histologies with distinct systemic therapy options (such as pure neuroendocrine tumors or sarcomas), recommend treatment according to the relevant NCCN Guideline for those tumor histologic types.

Note: All recommendations are category 2A unless otherwise indicated.

Version 1.2026, 03/10/26 © 2026 National Comprehensive Cancer Network® (NCCN®), All rights reserved. NCCN Guidelines® and this illustration may not be reproduced in any form without the express written permission of NCCN.

PLEASE NOTE that use of this NCCN Content is governed by the End-User License Agreement, and you MAY NOT distribute this Content or use it with any artificial intelligence model or tool.
Printed by Máximo López Chenlo on 5/4/2026 6:13:37 PM. Copyright © 2026 National Comprehensive Cancer Network, Inc. All Rights Reserved.

PRINCIPLES OF ARTERIAL/LOCOREGIONAL THERAPY FOR INTRAHEPATIC CHOLANGIOCARCINOMA

Patients with iCCA should be evaluated for potentially curative therapies (resection and for small lesions, ablation). Locoregional treatment may be considered in patients who are not candidates for surgical curative therapies or to downstage for other treatments.[1] Locoregional therapies are broadly categorized into ablation, arterially directed therapies, and RT.

Ablation
- All tumors should be amenable to complete ablation so that the tumor and a margin of normal tissue up to 1 cm can be treated.
- For small single tumors <3 cm, whether recurrent or primary, thermal ablation is a reasonable alternative to surgical resection, particularly in patients with high-risk disease.[2-4]
- Options for ablation include radiofrequency ablation, microwave ablation, and irreversible electroporation.

Arterially Directed Therapies
- Hepatic tumors may be amenable to arterially directed therapies provided the supply to tumor may be isolated without excessive non-target treatment.
- Select patients with limited extrahepatic disease (hilar lymph node ≤3 cm or ≤5 lung nodules each ≤1 cm) may be considered for arterially directed therapy in combination with systemic therapy.
- Arterially directed therapies include transarterial embolization, transarterial chemoembolization (TACE), TACE with drug-eluting beads (DEB-TACE), and yttrium-90 (Y-90).[5,6]
- Arterially directed therapies may be used alone or followed by systemic chemotherapy with the intention to prolong survival or downstage to curative resection.[7,8]
- When treating with Y-90, personalized dosimetry/radiation segmentectomy to achieve >205 Gy to tumor may improve outcome.[9]
- Y-90 is relatively contraindicated in patients with bilirubin >3 mg/dL. With well-selected patients, grade 3–4 hepatic toxicity occurs in <10% of patients, although this may be significantly higher in patients with cirrhosis.
- Hepatic arterial infusion chemotherapy (with or without systemic chemotherapy) may be used in a clinical trial or at experienced centers in carefully selected cases.

[1] Bridgewater J, Galle PR, Khan SA, et al. Guidelines for the diagnosis and management of intrahepatic cholangiocarcinoma. J Hepatol 2014;60:1268-1289.
[2] Kim GH, Kim PH, Kim JH, et al. Thermal ablation in the treatment of intrahepatic cholangiocarcinoma: A systematic review and meta-analysis. Eur Radiol 2022;32:1205-1215.
[3] Edeline J, Lamarca A, McNamara MG, et al. Locoregional therapies in patients with intrahepatic cholangiocarcinoma: A systematic review and pooled analysis. Cancer Treat Rev 2021;99:102258.
[4] Han K, Ko HK, Kim KW, et al. Radiofrequency ablation in the treatment of unresectable intrahepatic cholangiocarcinoma: Systematic review and meta-analysis. J Vasc Interv Radiol 2015;26:943-948.
[5] Mosconi C, Solaini L, Vara G, et al. Transarterial chemoembolization and radioembolization for unresectable intrahepatic cholangiocarcinoma – A systemic review and meta-analysis. Cardiovasc Intervent Radiol 2021;44:728-738.
[6] Schartz DA, Porter M, Schartz E, et al. Transarterial yttrium-90 radioembolization for unresectable intrahepatic cholangiocarcinoma: A systematic review and meta-analysis. J Vasc Interv Radiol 2022;33:679-686.
[7] Edeline J, Tochefeu Y, Guiu B, et al. Radioembolization plus chemotherapy for first-line treatment of locally advanced intrahepatic cholangiocarcinoma. JAMA Oncol 2020;6:51-59.
[8] Ahmed O, Yu Q, Patel M, et al. Yttrium-90 radioembolization and concomitant systemic gemcitabine, cisplatin, and capecitabine as the first-line therapy for locally advanced intrahepatic cholangiocarcinoma. J Vasc Interv Radiol 2023;34:702-709.
[9] Paz-Fumagalli R, Core J, Padula C, et al. Safety and initial efficacy of ablative radioembolization for the treatment of unresectable intrahepatic cholangiocarcinoma. Oncotarget 2021;12:2075-2088.

Note: All recommendations are category 2A unless otherwise indicated.

Version 1.2026, 03/10/26 © 2026 National Comprehensive Cancer Network® (NCCN®), All rights reserved. NCCN Guidelines® and this illustration may not be reproduced in any form without the express written permission of NCCN.

PLEASE NOTE that use of this NCCN Content is governed by the End-User License Agreement, and you MAY NOT distribute this Content or use it with any artificial intelligence model or tool.
Printed by Máximo López Chenlo on 5/4/2026 6:13:37 PM. Copyright © 2026 National Comprehensive Cancer Network, Inc. All Rights Reserved.

PRESENTATION AND WORKUP[a]

- Pain
- Jaundice
- Abnormal LFTs
- Obstruction or abnormality on imaging

→

- Multidisciplinary evaluation
- H&P
- Multiphasic abdomen/pelvis CT/MRI (assess for vascular invasion) with IV contrast[b,c]
- Chest CT ± contrast[b,c]
- Biliary protocol imaging[b,c]
- Cholangiography[d]
- Consider CEA testing[e]
- Consider CA 19-9 testing[e]
- LFTs
- Consider endoscopic ultrasound (EUS) after surgical consultation
- Consider serum IgG4 testing to rule out IgG4-related sclerosing cholangitis[f]

PRIMARY TREATMENT

Resectable[g] →

- Surgical exploration[i]
- Consider laparoscopic staging
- Consider preoperative biliary drainage[b]

→ Resectable[g] → Resection[g,k] → Adjuvant treatment and surveillance (EXTRA-2)

→ Unresectable, see below

Unresectable[h] →

- Biliary drainage,[b,j] if indicated
- Biopsy[h,k] (only after determining transplant status)
  - Biomarker testing[l,m]
- Consider referral to transplant center[g]

→ Options[n]:
- Systemic therapy[o]
- Clinical trial
- Combination of chemotherapy and chemoradiation[o,p,q,r]
- Chemoradiation[o,p,r]
- Palliative RT[r]

→ Best supportive care[s]

Metastatic disease →

- Biliary drainage,[b,j] if indicated
- Biopsy[k]
  - Biomarker testing[l,m]

→ Options[n]:
- Systemic therapy[o]
- Clinical trial

→ Assess for response and
- Reconsider resection or locoregional therapy or
- Subsequent-line systemic therapy if progression on or after systemic therapy[o]

[a] Refer to the NCCN Distress Thermometer and Problem List, which includes social determinants of health. See NCCN Guidelines for Distress Management (DIS-A).
[b] Principles of Imaging (BIL-A).
[c] Imaging evaluation for suspected eCCA is ideally performed prior to biliary decompression to facilitate accurate local staging for surgical candidacy.
[d] MRCP is preferred. ERCP/PTC are used more for therapeutic intervention.
[e] CEA and CA 19-9 are baseline tests and should not be done to confirm diagnosis.
[f] Patients with IgG4–related cholangiopathy should be referred to an expert center.
[g] Principles of Surgery (EXTRA-A).
[h] Before biopsy, evaluate if patient is a resection or transplant candidate. If patient is a potential transplant candidate, consider referral to transplant center before biopsy. Importantly, transperitoneal and surgical biopsy may be contraindicated in transplant candidates. Unresectable perihilar or hilar CCAs that measure ≤3 cm in radial diameter, with the absence of intrahepatic or extrahepatic metastases and without nodal disease, as well as those with primary sclerosing cholangitis, may be considered for liver transplantation at a transplant center that has an UNOS-approved protocol for transplantation of CCA.
[i] Surgery may be performed when index of suspicion is high; biopsy is not required.
[j] Consider biliary drainage for patients with jaundice prior to instituting systemic therapy. Consider baseline CA 19-9 after biliary decompression.
[k] Principles of Pathology (EXTRA-B).
[l] For patients with dMMR/MSI-H tumors or a family history suggestive of *BRCA1/2* PVs, consider germline testing and/or referral to a genetic counselor.
[m] Principles of Biomarker Testing (BIL-B).
[n] Order does not indicate preference. The choice of treatment modality may depend on extent/location of disease and institutional capabilities.
[o] Principles of Systemic Therapy (BIL-C).
[p] There are limited clinical trial data to define a standard regimen or definitive benefit. Clinical trial participation is encouraged (Macdonald OK, et al. Surg Oncol Clin N Am 2002;11:941-954).
[q] For a list of gemcitabine-based regimens and fluoropyrimidine-based regimens to be used before or after chemoradiation, see Adjuvant Chemotherapy (BIL-C, 1 of 5).
[r] Principles of Radiation Therapy (BIL-D).
[s] NCCN Guidelines for Palliative Care.

Note: All recommendations are category 2A unless otherwise indicated.

Version 1.2026, 03/10/26 © 2026 National Comprehensive Cancer Network® (NCCN®), All rights reserved. NCCN Guidelines® and this illustration may not be reproduced in any form without the express written permission of NCCN.

PLEASE NOTE that use of this NCCN Content is governed by the End-User License Agreement, and you MAY NOT distribute this Content or use it with any artificial intelligence model or tool.
Printed by Máximo López Chenlo on 5/4/2026 6:13:37 PM. Copyright © 2026 National Comprehensive Cancer Network, Inc. All Rights Reserved.

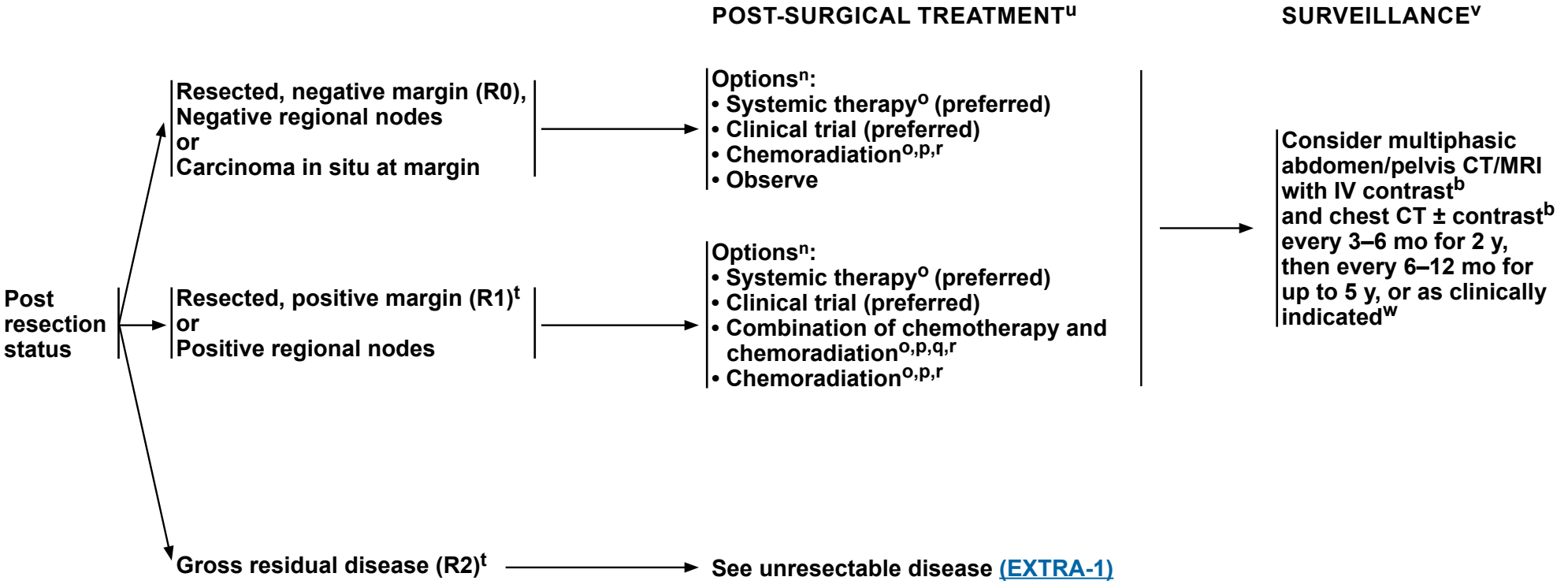

[b] Principles of Imaging (BIL-A).
[n] Order does not indicate preference. The choice of treatment modality may depend on extent/location of disease and institutional capabilities.
[o] Principles of Systemic Therapy (BIL-C).
[p] There are limited clinical trial data to define a standard regimen or definitive benefit. Clinical trial participation is encouraged (Macdonald OK, et al. Surg Oncol Clin N Am 2002;11:941-954).
[q] For a list of gemcitabine-based regimens and fluoropyrimidine-based regimens to be used before or after chemoradiation, see Adjuvant Chemotherapy (BIL-C, 1 of 5).
[r] Principles of Radiation Therapy (BIL-D).
[t] Management of disease in patients with R1 or R2 resections should be evaluated by a multidisciplinary team.
[u] Adjuvant chemotherapy or chemoradiation has been associated with survival benefit in patients with BTC, especially in patients with lymph node-positive disease (Horgan AM, et al. J Clin Oncol 2012;30:1934-1940).
[v] There are no data to support a specific surveillance schedule or tests for monitoring. Physicians should discuss appropriate follow-up schedules/imaging with patients.
[w] Based on surveillance schedule used in the phase III BILCAP trial. Primrose JN, et al. Lancet Oncol 2019;20:663-673.

Note: All recommendations are category 2A unless otherwise indicated.

Version 1.2026, 03/10/26 © 2026 National Comprehensive Cancer Network® (NCCN®), All rights reserved. NCCN Guidelines® and this illustration may not be reproduced in any form without the express written permission of NCCN.

PLEASE NOTE that use of this NCCN Content is governed by the End-User License Agreement, and you MAY NOT distribute this Content or use it with any artificial intelligence model or tool.
Printed by Máximo López Chenlo on 5/4/2026 6:13:37 PM. Copyright © 2026 National Comprehensive Cancer Network, Inc. All Rights Reserved.

PRINCIPLES OF SURGERY

General Principles
- The basic principle is a complete resection with negative margins and regional lymphadenectomy. This generally requires a pancreaticoduodenectomy for distal bile duct tumors and a major hepatic resection for hilar tumors. Occasionally, a mid bile duct tumor can be resected with a bile duct resection and regional lymphadenectomy.
- A preoperative biopsy is not always necessary before proceeding with a definitive, potentially curative resection. A suspicious mass on imaging in the proper clinical setting should be treated as malignant.
- Diagnostic laparoscopy should be considered.
- Rarely, a bile duct tumor will involve the biliary tree over a long distance such that a hepatic resection and pancreaticoduodenectomy will be necessary. These are relatively morbid procedures and should only be carried out in very healthy patients without significant comorbidity. Nonetheless, these can be potentially curative procedures and should be considered in the proper clinical setting. Combined liver and pancreatic resections performed to clear distant nodal disease are not recommended.

Hilar Cholangiocarcinoma
- Detailed descriptions of imaging assessment of resectability are beyond the scope of this guideline. The basic principle is that the tumor will need to be resected along with the involved biliary tree and the involved hemi-liver with a reasonable chance of a margin-negative resection. The contralateral liver requires intact arterial and portal inflow as well as biliary drainage.[1-3]
- Detailed descriptions of preoperative surgical planning are beyond the scope of this outline but require an assessment of the future liver remnant (FLR). This requires an assessment of biliary drainage and volumetrics of the FLR. While not necessary in all cases, the use of preoperative biliary drainage of the FLR and contralateral portal vein embolization should be considered in cases of a small FLR.[4,5]
- Initial exploration rules out distant metastatic disease to the liver, peritoneum, or distant lymph nodes beyond the porta hepatis as these findings contraindicate resection. Further exploration must confirm local resectability.
- Since hilar tumors, by definition, abut or invade the central portion of the liver they require major hepatic resections on the involved side to encompass the biliary confluence and generally require a caudate resection.
- Resection and reconstruction of the portal vein and/or hepatic artery may be necessary for complete resection and require expertise in these procedures.
- Biliary reconstruction is generally through a Roux-en-Y hepaticojejunostomy.
- A regional lymphadenectomy of the porta hepatis is carried out.
- Frozen section assessment of proximal and distal bile duct margins is recommended if further resection can be carried out.

Distal Cholangiocarcinoma
- Initial assessment is needed to rule out distant metastatic disease and local resectability.
- The operation generally requires a pancreaticoduodenectomy with typical reconstruction.
- If suspected diagnosis, consider assessing frozen section of proximal bile duct margin.

[1] Nishio H, Nagino M, Nimura Y. Surgical management of hilar cholangiocarcinoma: the Nagoya experience. HPB (Oxford) 2005;7:259-262.
[2] Matsuo K, Rocha FG, Ito K, et al. The Blumgart preoperative staging system for hilar cholangiocarcinoma: analysis of resectability and outcomes in 380 patients. J Am Coll Surg 2012;215:343-355.
[3] Jarnagin WR, Fong Y, DeMatteo RP, et al. Staging, resectability, and outcome in 225 patients with hilar cholangiocarcinoma. Ann Surg 2001;234:507-517.
[4] Nimura Y. Preoperative biliary drainage before resection for cholangiocarcinoma. HPB (Oxford) 2008;10:130-133.
[5] Kennedy TJ, Yopp A, Qin Y, et al. Role of preoperative biliary drainage of live remnant prior to extended liver resection for hilar cholangiocarcinoma. HPB (Oxford) 2009;11:445-451.

Note: All recommendations are category 2A unless otherwise indicated.

Version 1.2026, 03/10/26 © 2026 National Comprehensive Cancer Network® (NCCN®), All rights reserved. NCCN Guidelines® and this illustration may not be reproduced in any form without the express written permission of NCCN.

PLEASE NOTE that use of this NCCN Content is governed by the End-User License Agreement, and you MAY NOT distribute this Content or use it with any artificial intelligence model or tool.
Printed by Máximo López Chenlo on 5/4/2026 6:13:37 PM. Copyright © 2026 National Comprehensive Cancer Network, Inc. All Rights Reserved.

PRINCIPLES OF PATHOLOGY

eCCA Appropriate for Biopsy
Histologic confirmation of primary hepatic malignancy with cholangiocyte differentiation
- Establish cholangiocyte differentiation by histology and if appropriate supported by IHC and albumin ISH studies.
- Report the presence of small vessel invasion and undifferentiated/poor differentiation.

eCCA Undergoing Resection
Staging for diagnosis and prognosis of primary hepatic malignancy

Pathologic Staging
The following parameters should be reported for cancer with histopathologic type: perihilar, Klatskin type, and distal bile duct cancers have separate staging parameters. Perihilar tumors are defined by a tumor arising in the main lobar ducts in the extrahepatic biliary system proximal to the cystic duct. Extrahepatic bile duct cancers are defined as tumors arising in the extrahepatic biliary tree between the confluence of the cystic duct and common hepatic duct and the ampulla of Vater. Tumors of the ampulla of Vater (hepatopancreatic ampulla) are staged separately.

- Reported Parameters
  - Perihilar bile duct
    - Carcinoma in situ/high-grade dysplasia
    - Tumor extent (T stage)
      - Confined to the bile duct
      - Tumor depth of invasion into or through
        - Bile duct muscle layer or fibrous tissue
        - Bile duct wall
        - Surrounding adipose tissue
        - Adjacent hepatic parenchyma
        - Uni- or bilateral branches of the portal vein or hepatic artery
        - Main portal vein
        - Second-order biliary radicals with contralateral portal vein or hepatic artery involvement
  - Extrahepatic bile duct
    - Carcinoma in situ/high-grade dysplasia
    - Depth of tumor invasion into the bile duct wall <5 mm, 5–12 mm, or >12 mm
    - Tumor involves the celiac axis, superior mesenteric artery, and/or common hepatic artery
  - Number of regional lymph nodes (N stage)
  - Distal organ metastasis (M stage)
  - If adequate sampling: Identify individual blocks containing malignant tissue and non-malignant tissue ideal for further testing.

If Adequate Sample Available
- Histopathologic types of eCCA[a,b]

- Background liver disease
  - Indicate the presence or absence of chronic liver disease (eg, viral hepatitis, MASLD, metabolic disorder) either from the clinical history or histopathologic changes.
  - Report the degree of fibrosis and the presence or absence of cirrhosis.

[a] Well-differentiated neuroendocrine tumor is not staged as a extrahepatic biliary carcinoma.
[b] For rare histologies with distinct systemic therapy options (such as pure neuroendocrine tumors or sarcomas), recommend treatment according to the relevant NCCN Guideline for those tumor histologic types.

Note: All recommendations are category 2A unless otherwise indicated.

Version 1.2026, 03/10/26 © 2026 National Comprehensive Cancer Network® (NCCN®), All rights reserved. NCCN Guidelines® and this illustration may not be reproduced in any form without the express written permission of NCCN.

PLEASE NOTE that use of this NCCN Content is governed by the End-User License Agreement, and you MAY NOT distribute this Content or use it with any artificial intelligence model or tool.
Printed by Máximo López Chenlo on 5/4/2026 6:13:37 PM. Copyright © 2026 National Comprehensive Cancer Network, Inc. All Rights Reserved.

PRINCIPLES OF IMAGING[1-4]

General Principles
- CT of the chest with or without contrast and multiphasic contrast-enhanced CT or MRI of the abdomen and pelvis are recommended for follow-up imaging.
- PET/CT has limited sensitivity but high specificity and may be considered when there is an equivocal finding or on a case-by-case basis.[5] The routine use of PET/CT in the preoperative setting has not been established in prospective trials.

Gallbladder Cancer
- Detection of early-stage gallbladder cancer remains difficult, and is commonly discovered incidentally at surgery or pathologic examination of the gallbladder.
- If gallbladder cancer is suspected preoperatively, multiphase CT of the abdomen (and pelvis) or contrast-enhanced MRI with magnetic resonance cholangiopancreatography (MRCP) of the abdomen (and pelvis) and chest CT with or without contrast should be performed. MRI is preferred for evaluating masses within the gallbladder and demonstrating bile duct involvement.
- Because lymphatic spread is common, careful attention should be made to evaluate nodal disease, specifically the porta hepatis and left gastric and aorto-caval basins.

Intrahepatic[6] and Extrahepatic Cholangiocarcinoma
- Surgical management is based on the location and extent of the tumor.
- Preoperative imaging for accurate staging of eCCA should be done with multidetector multiphasic abdomen/pelvis CT or MRI. Contrast-enhanced MRI with MRCP is preferred for evaluating the extent of biliary tract involvement. Imaging with multiphasic CT or MRI with thin cuts, or multiphase CT or MRI of the liver and biliary tree should specifically address the anatomy of the biliary tree, hepatic arteries, and portal veins and their relationship to the tumor.[7]

Intrahepatic and Extrahepatic Cholangiocarcinoma (continued)
- Chest CT with or without contrast is recommended for staging.
- When biliary duct involvement is suspected, it is very important to obtain high-quality biliary protocol imaging (preferably CT) to evaluate the extent of tumor prior to stenting. Reactive changes from stenting could potentially compromise the ability to delineate the complete extent of biliary tract involvement.
- EUS or endoscopic retrograde cholangiopancreatography (ERCP) may be helpful in the setting of bile duct dilation if no mass is seen on CT or MRI. EUS or ERCP can also be used to establish tissue diagnosis and provide access to relieve biliary obstruction.
- CT of the chest with or without contrast and CT or MRI of the abdomen and pelvis with contrast may be used for follow-up.
- Delayed phase imaging is preferred when the diagnosis of iCCA is suspected or confirmed.

Biliary Drainage
- Multidisciplinary discussion of drainage is recommended, especially in patients with potentially resectable disease.
- Route (percutaneous vs. endoscopic) should be considered based on local expertise after multidisciplinary review.
- All segments that are opacified should be drained, with the aim to drain >50% of the viable liver volume, including the FLR. Atrophic liver segments, in general, should not be drained.

1 Srinivasa S, McEntee B, Koea JB. The role of PET scans in the management of cholangiocarcinoma and gallbladder cancer: a systematic review for surgeons. Int J Diagnostic Imaging 2015;2.
2 Corvera CU, Blumgart LH, Akhurst T, et al. 18F-fluorodeoxyglucose positron emission tomography influences management decisions in patients with biliary cancer. J Am Coll Surg 2008;206:57-65.
3 Brandi G, Venturi M, Pantaleo MA, Ercolani G, GICO. Cholangiocarcinoma: Current opinion on clinical practice diagnostic and therapeutic algorithms: A review of the literature and a long-standing experience of a referral center. Dig Liver Dis 2016;48:231-241.
4 Navaneethan U, Njei B, Venkatesh PG, et al. Endoscopic ultrasound in the diagnosis of cholangiocarcinoma as the etiology of biliary strictures: a systematic review and meta-analysis. Gastroenterol Rep (Oxf) 2015;3:209-215.
5 Lamarca A, Barriuso J, Chander A, et al. 18F-fluorodeoxyglucose positron emission tomography (18FDG-PET) for patients with biliary tract cancer: Systematic review and meta-analysis. J Hepatol 2019;71:115-129.
6 Sutton TL, Billingsley KG, Walker BS, et al. Detection of tumor multifocality in resectable intrahepatic cholangiocarcinoma: Defining the optimal pre-operative imaging modality. J Gastrointest Surg 2021;25:2250-2257.
7 ACR-SAR-SPR practice parameter for the performance of magnetic resonance imaging (MRI) of the liver. American College of Radiology, 2020. Available at: https://www.acr.org/-/media/ACR/Files/Practice-Parameters/MR-Liver.pdf. Accessed 01/18/22.

Note: All recommendations are category 2A unless otherwise indicated.

Version 1.2026, 03/10/26 © 2026 National Comprehensive Cancer Network® (NCCN®), All rights reserved. NCCN Guidelines® and this illustration may not be reproduced in any form without the express written permission of NCCN.

PLEASE NOTE that use of this NCCN Content is governed by the End-User License Agreement, and you MAY NOT distribute this Content or use it with any artificial intelligence model or tool.
Printed by Máximo López Chenlo on 5/4/2026 6:13:37 PM. Copyright © 2026 National Comprehensive Cancer Network, Inc. All Rights Reserved.

PRINCIPLES OF BIOMARKER TESTING

- Biliary tract cancers (BTCs) are known to harbor clinically relevant genomic alterations that are differentially expressed in gallbladder cancers, and intrahepatic and extrahepatic (perihilar and distal) CCAs. Specifically, genotyping of the tumor tissue has identified translocations in *FGFR2* and *NTRK1/2/3*, mutations in the *IDH1* and *BRAF* genes, and microsatellite instability (MSI) along with other rare genomic alterations for which specific treatments are now available.[1-22]

- Additionally, while most biliary tract carcinomas are considered sporadic, up to 10%–15% of BTCs may be associated with an inherited cancer predisposition syndrome.[23,24] Recent studies have evaluated germline testing in large cohorts of unselected patients with biliary tract carcinoma and discovered high to moderate penetrance of germline pathogenic/likely pathogenic (P/LP) variants in roughly 9% to 11% of BTCs, including intrahepatic/extrahepatic CCAs and gallbladder carcinomas.[23,25] The highest prevalence was found for *BRCA2* pathogenic variant (PV) followed by *BRCA1* and to a lesser extent *MLH1*, *MSH2*, *PALB2*, *RAD51D*, *BAP1,* and *ATM*.[23,25,26] These findings are consistent with earlier literature suggesting an increased risk of BTC in patients with *BRCA1/2* PVs and Lynch syndrome.[27,28]

Recommendations

- Biomarker testing in BTCs: MGPT and other biomarker testing is recommended for patients with unresectable or metastatic BTC who are candidates for systemic therapy (see Table 1 and Table 2). A comprehensive panel including the targets listed in Table 1 may optimize the chance of identifying biomarkers for targeted therapy. Consider tissue RNA-based MGPT to maximize detection of fusion events. If tissue is too scant or not available, consider repeat biopsy depending on tumor accessibility, safety, and clinical context. Circulating tumor DNA (ctDNA) testing may also be considered for identifying gene mutations. This technique may not reliably identify gene fusions or rearrangements depending on the panel used and the specific partner gene.

- Germline testing in hepatobiliary cancers: Evidence remains insufficient for definitive recommendations regarding specific criteria to guide genetic risk assessment in hepatobiliary cancers or for universal germline testing in these tumors. In BTCs, genetic counseling referral and potential germline testing should be considered in patients with any of the following characteristics: young age at diagnosis; a strong personal or family history of cancer; no known risk factors for liver disease; or presence of mutations identified during tumor testing that are suspected to be possible germline alterations. For patients who harbor a known germline PV associated with a cancer predisposing syndrome (ie, Lynch syndrome or hereditary breast and ovarian cancer syndrome), there is currently insufficient evidence to support screening for biliary tract malignancies. Further recommendations and a detailed discussion of genetic counseling and testing can be found in the NCCN Guidelines for Genetic/Familial High-Risk Assessment: Breast, Ovarian, Pancreatic, and Prostate and NCCN Guidelines for Genetic/Familial High-Risk Assessment: Colorectal, Endometrial, and Gastric.

Note: All recommendations are category 2A unless otherwise indicated.

References

Version 1.2026, 03/10/26 © 2026 National Comprehensive Cancer Network® (NCCN®), All rights reserved. NCCN Guidelines® and this illustration may not be reproduced in any form without the express written permission of NCCN.

PLEASE NOTE that use of this NCCN Content is governed by the End-User License Agreement, and you MAY NOT distribute this Content or use it with any artificial intelligence model or tool.
Printed by Máximo López Chenlo on 5/4/2026 6:13:37 PM. Copyright © 2026 National Comprehensive Cancer Network, Inc. All Rights Reserved.

PRINCIPLES OF BIOMARKER TESTING

Table 1: Recommendations for Biomarker Testing in Unresectable or Metastatic Biliary Tract Cancers[a-e]

Recommended Molecular Testing	Anatomic Subsite		
	Gallbladder	iCCA	eCCA
NTRK1/2/3 gene fusion	X	X	X
MSI-H/dMMR	X	X	X
TMB-H	X	X	X
BRAF V600E mutation	X	X	X
FGFR2 gene fusion or rearrangement	–	X	X
IDH1 mutation	–	X	X
HER2 *(ERBB2)* overexpression and/ or amplification	X	X	X
RET gene fusion	X	X	X
KRAS G12C mutation	X	X	X
NRG1 gene fusion	–	X	X

[a] Consider repeat biopsy or performing ctDNA analysis if initial biopsy sample yields insufficient tumor content, depending on clinical context.
[b] If unsure about the primary anatomic site within the biliary tree, biomarker testing is recommended, including consideration of *FGFR2* gene fusion or rearrangement testing and *IDH1* mutation testing in gallbladder cancer or in large tumors of uncertain anatomic origin within the biliary tree.
[c] Testing for *FGFR2* gene fusions or rearrangements and *IDH1* mutations should be considered in patients with unresectable or metastatic gallbladder cancer.
[d] Genetic counseling referral and germline testing should be considered in patients with any of the following characteristics: young age at diagnosis; a strong personal or family history of cancer; no known risk factors for liver disease; or presence of mutations identified during tumor biomarker testing that are suspected to be possible germline alterations.
[e] Consider RNA-based MGPT to maximize detection of fusion events.

Note: All recommendations are category 2A unless otherwise indicated.

Version 1.2026, 03/10/26 © 2026 National Comprehensive Cancer Network® (NCCN®), All rights reserved. NCCN Guidelines® and this illustration may not be reproduced in any form without the express written permission of NCCN.

PLEASE NOTE that use of this NCCN Content is governed by the End-User License Agreement, and you MAY NOT distribute this Content or use it with any artificial intelligence model or tool.
Printed by Máximo López Chenlo on 5/4/2026 6:13:37 PM. Copyright © 2026 National Comprehensive Cancer Network, Inc. All Rights Reserved.

PRINCIPLES OF BIOMARKER TESTING

Table 2: Incidence of Therapeutic Biomarkers in Advanced Biliary Tract Cancers

Aberration	Approximate Incidence[f]
NTRK1/2/3 gene fusion	<1%
MSI-H/dMMR	1%–3%
TMB-H	<5%
BRAF V600E mutation	1%–5%
FGFR2 gene fusion or rearrangement	9%–15% of iCCAs and rare in other subsites
IDH1 mutation	10%–20% of iCCAs and rare in other subsites
HER2 (*ERBB2*) overexpression and/or amplification	5%–20% of CCAs, 15%–30% of gallbladder cancer
RET gene fusion	<1%
KRAS G12C mutation	1%
NRG1 gene fusion	<1%

[f] The rarity of individual subgroups limits precise incidence and frequency estimates. Incidence estimates refer to BTCs across anatomic subsites, unless otherwise stated.

Note: All recommendations are category 2A unless otherwise indicated.

Version 1.2026, 03/10/26 © 2026 National Comprehensive Cancer Network® (NCCN®), All rights reserved. NCCN Guidelines® and this illustration may not be reproduced in any form without the express written permission of NCCN.

PLEASE NOTE that use of this NCCN Content is governed by the End-User License Agreement, and you MAY NOT distribute this Content or use it with any artificial intelligence model or tool.
Printed by Máximo López Chenlo on 5/4/2026 6:13:37 PM. Copyright © 2026 National Comprehensive Cancer Network, Inc. All Rights Reserved.

PRINCIPLES OF BIOMARKER TESTING

NTRK1/2/3 Gene Fusions

- Testing Modalities and Considerations: RNA-based MGPT is the preferred assay because it has higher sensitivity and accuracy than DNA-based testing for gene fusions, including *NTRK1/2/3*.
- Recommendation: Testing for *NTRK1/2/3* gene fusions is recommended for patients with unresectable or metastatic gallbladder cancer, iCCA, or eCCA. These assessments are feasible in the context of MGPT currently in clinical use, and *NTRK1/2/3* gene fusion-positive CCA have demonstrated responses in clinical trials.

Immunotherapy Biomarkers (MSI-H/dMMR, TMB-H)

- Testing Modalities and Considerations: Mismatch repair (MMR) protein expression deficiency and MSI are highly correlated. Testing for either or both can be used to guide therapy. MMR protein expression can be assessed by IHC staining for MLH1, MSH2, MSH6, and PMS2 proteins. If all 4 proteins are retained, it is unlikely the sample will display MSI. Testing for MSI may be accomplished by either clinically validated polymerase chain reaction (PCR) testing or MGPT. MGPT is preferred when other genomic alterations are assessed simultaneously, especially if tissue is limited. Tumor mutational burden (TMB) testing should be performed using clinically validated MGPT with considerations that there can be inherent platform variation.
- Recommendation: MSI or MMR testing is recommended in patients with unresectable or metastatic gallbladder cancer, iCCA, or eCCA.
- Testing for TMB is recommended for patients with unresectable or metastatic gallbladder cancer, iCCA, or eCCA based upon clinical benefit observed across advanced solid tumors.
- Further recommendations for MSI/MMR testing can be found in the NCCN Guidelines for Colon Cancer.

Note: All recommendations are category 2A unless otherwise indicated.

Version 1.2026, 03/10/26 © 2026 National Comprehensive Cancer Network® (NCCN®), All rights reserved. NCCN Guidelines® and this illustration may not be reproduced in any form without the express written permission of NCCN.

PLEASE NOTE that use of this NCCN Content is governed by the End-User License Agreement, and you MAY NOT distribute this Content or use it with any artificial intelligence model or tool.
Printed by Máximo López Chenlo on 5/4/2026 6:13:37 PM. Copyright © 2026 National Comprehensive Cancer Network, Inc. All Rights Reserved.

PRINCIPLES OF BIOMARKER TESTING

BRAF V600E Mutations

- Testing Modalities and ctDNA Considerations: MGPT or targeted testing of tumor tissue; MGPT of ctDNA can also detect tumor *BRAF* mutations.
- Recommendation: Testing for *BRAF* V600E mutations is recommended for patients with unresectable or metastatic gallbladder cancer, iCCA, or eCCA.

FGFR2 Gene Fusions/Other *FGFR* Pathway Aberrations

- Testing Modalities and Considerations: MGPT, which analyzes the *FGFR2* gene with its intronic regions, and break apart fluorescence in situ hybridization (FISH) assay, can be used to identify patients with *FGFR2* gene fusions/rearrangements in tumor tissue samples.[1,29] However, RNA-based MGPT is preferred for gene fusion detection because of improved sensitivity and the ability to predict the fusion protein. Some gene fusion breakpoints may be detectable using ctDNA assays, but sensitivity is lower than for tumor tissue testing.[30]
- Recommendation: Testing for *FGFR2* gene fusions or rearrangements is recommended for patients with unresectable or metastatic intrahepatic or eCCA and should be considered for patients with unresectable or metastatic gallbladder cancer.

IDH1 Mutations

- Testing Modalities and Considerations: *IDH1* mutations in iCCA occur most commonly at codon 132 (R132X).[9,31] Testing can be performed by targeted mutation testing or by MGPT, which is preferred when other genomic alterations are assessed simultaneously. ctDNA testing can also detect hotspot mutations in *IDH1*.
- Recommendation: Testing for *IDH1* mutations is recommended for patients with unresectable or metastatic iCCA or eCCA and should be considered for patients with unresectable or metastatic gallbladder cancer.

Note: All recommendations are category 2A unless otherwise indicated.

References

Version 1.2026, 03/10/26 © 2026 National Comprehensive Cancer Network® (NCCN®), All rights reserved. NCCN Guidelines® and this illustration may not be reproduced in any form without the express written permission of NCCN.

PLEASE NOTE that use of this NCCN Content is governed by the End-User License Agreement, and you MAY NOT distribute this Content or use it with any artificial intelligence model or tool.
Printed by Máximo López Chenlo on 5/4/2026 6:13:37 PM. Copyright © 2026 National Comprehensive Cancer Network, Inc. All Rights Reserved.

PRINCIPLES OF BIOMARKER TESTING

HER2 (*ERBB2*) Overexpression/Amplification/Activating Mutations

- Testing Modalities and Considerations: HER2 (*ERBB2*) overexpression/amplification can be detected by IHC, FISH, or next-generation sequencing (NGS) techniques. MGPT offers the ability to assess numerous genomic alterations simultaneously and has the added benefit of detecting HER2 (*ERBB2*) activating mutations. MGPT can be considered upfront when limited diagnostic tissue is available, though other methodologies such as IHC/FISH remain the most commonly utilized. However, the predominant limitation of HER2 or *ERBB2* testing in hepatobiliary tumors is the lack of specific guideline cutoff points or standardized algorithms to define HER2 positivity by protein expression or *ERBB2* amplification in hepatobiliary malignancies.[32] Various cutoff values including those described for breast and gastroesophageal junction neoplasms have been used in prior and ongoing clinical trials, making direct comparisons between studies difficult. Other challenges to be considered include the significant heterogeneity that can be seen with protein overexpression in BTCs, which may affect positivity rates when IHC is performed in biopsy specimens.[33] Lastly, while most alterations are identified through overexpression or amplification, activating missense mutations have also been shown to represent a significant subset of HER2 (*ERBB2*)-altered tumors, which will be missed with standard IHC and FISH techniques.[13,34]

- Recommendation: Testing for HER2 (*ERBB2*) overexpression/amplification or activating mutations is recommended for patients with unresectable or metastatic gallbladder cancer, iCCA, or eCCA.

NRG1 Gene Fusion

- Testing Modalities and Considerations: RNA-based MGPT of tumor tissue is the primary method for detection of *NRG1* gene fusions and is preferable to DNA-based MGPT. *NRG1* gene fusions are often not detected by DNA-based MGPT as the large introns in *NRG1* are not commonly included in targeted MGPT or whole exome sequencing.[35-37]

- Recommendation: RNA-based MGPT for *NRG1* gene fusions is recommended for patients with unresectable or metastatic iCCA or eCCA.

Other Biomarkers (*RET*, *KRAS* G12C, and Other Tumor-Agnostic Markers)

- In addition to the genomic alterations reviewed above, MGPT may uncover other potentially actionable molecular alterations that could determine eligibility for ongoing clinical trials in patients with advanced BTCs. While there is insufficient evidence to recommend universal assessment, alterations for which targeted therapies exist and have been FDA-approved in other tumor types, including *KRAS* G12C mutation,[38-40] *MET* amplification,[41-43] and *ALK*,[44] *RET*,[19] or *ROS1* gene fusions,[45] among others,[46] have been described with variable but overall rare frequency in biliary tract carcinomas and HCC.[47] However, limited data currently exist regarding the efficacy of targeted therapy in these situations, due to their rarity.

- Recommendation: Testing for *RET* gene fusions is recommended for patients with unresectable or metastatic gallbladder cancer, iCCA, or eCCA. MGPT may identify additional alterations for which biomarker-directed therapies exist and have FDA-approved treatments in other tumor types. RNA-based MGPT is the preferred approach for gene fusion detection.

- Recommendation: Testing for *KRAS* G12C mutations is recommended for patients with unresectable or metastatic gallbladder cancer, iCCA, or eCCA.

References

Note: All recommendations are category 2A unless otherwise indicated.

Version 1.2026, 03/10/26 © 2026 National Comprehensive Cancer Network® (NCCN®), All rights reserved. NCCN Guidelines® and this illustration may not be reproduced in any form without the express written permission of NCCN.

PLEASE NOTE that use of this NCCN Content is governed by the End-User License Agreement, and you MAY NOT distribute this Content or use it with any artificial intelligence model or tool.
Printed by Máximo López Chenlo on 5/4/2026 6:13:37 PM. Copyright © 2026 National Comprehensive Cancer Network, Inc. All Rights Reserved.

PRINCIPLES OF BIOMARKER TESTING
REFERENCES

[1] Graham RP, Barr Fritcher EG, Pestova E, et al. Fibroblast growth factor receptor 2 translocations in intrahepatic cholangiocarcinoma. Hum Pathol 2014;45:1630-1638.
[2] Silverman IM, Hollebecque A, Friboulet L, et al. Clinicogenomic analysis of *FGFR2*-rearranged cholangiocarcinoma identifies correlates of response and mechanisms of resistance to pemigatinib. Cancer Discov 2021;11:326-339.
[3] Abou-Alfa GK, Sahai V, Hollebecque A, et al. Pemigatinib for previously treated, locally advanced or metastatic cholangiocarcinoma: A multicentre, open-label, phase 2 study. Lancet Oncol 2020;21:671-684.
[4] Okamura R, Boichard A, Kato S, et al. Analysis of *NTRK* alterations in pan-cancer adult and pediatric malignancies: Implications for NTRK-targeted therapeutics. JCO Precis Oncol 2018;2018:PO.18.00183.
[5] Drilon A, Siena S, Ou SI, et al. Safety and antitumor activity of the multitargeted pan-TRK, ROS1, and ALK inhibitor entrectinib: Combined results from two phase I trials (ALKA-372-001 and STARTRK-1). Cancer Discov 2017;7:400-409.
[6] Doebele RC, Drilon A, Paz-Ares L, et al. Entrectinib in patients with advanced or metastatic NTRK fusion-positive solid tumours: integrated analysis of three phase 1-2 trials. Lancet Oncol 2020;21:271-282.
[7] Drilon A, Laetsch TW, Kummar S, et al. Efficacy of larotrectinib in TRK fusion-positive cancers in adults and children. N Engl J Med 2018;378:731-739.
[8] Farshidfar F, Zheng S, Gingras MC, et al. Integrative genomic analysis of cholangiocarcinoma identifies distinct IDH-mutant molecular profiles. Cell Rep 2017;18:2780-2794.
[9] Abou-Alfa GK, Macarulla T, Javle MM, et al. Ivosidenib in IDH1-mutant, chemotherapy-refractory cholangiocarcinoma (ClarIDHy): A multicentre, randomised, double-blind, placebo-controlled, phase 3 study. Lancet Oncol 2020;21:796-807.
[10] Zhu AX, Macarulla T, Javle MM, et al. Final overall survival efficacy results of ivosidenib for patients with advanced cholangiocarcinoma with IDH1 mutation: The phase 3 randomized clinical ClarIDHy trial. JAMA Oncol 2021;7:1669-1677.
[11] Subbiah V, Lassen U, Elez E, et al. Dabrafenib plus trametinib in patients with $BRAF^{V600E}$-mutated biliary tract cancer (ROAR): a phase 2, open-label, single-arm, multicentre basket trial. Lancet Oncol 2020;21:1234-1243.
[12] Salama AKS, Li S, Macrae ER, et al. Dabrafenib and trametinib in patients with tumors with $BRAF^{V600E}$ mutations: Results of the NCI-MATCH trial Subprotocol H. J Clin Oncol 2020;38:3895-3904.
[13] Jacobi O, Ross JS, Goshen-Lago T, et al. ERBB2 pathway in biliary tract carcinoma: Clinical implications of a targetable pathway. Oncol Res Treat 2021;44:20-27.
[14] Javle M, Borad MJ, Azad NS, et al. Pertuzumab and trastuzumab for HER2-positive, metastatic biliary tract cancer (MyPathway): A multicentre, open-label, phase 2a, multiple basket study. Lancet Oncol 2021;22:1290-1300.
[15] Le DT, Durham JN, Smith KN, et al. Mismatch repair deficiency predicts response of solid tumors to PD-1 blockade. Science 2017;357:409-413.
[16] Marabelle A, Le DT, Ascierto PA, et al. Efficacy of pembrolizumab in patients with noncolorectal high microsatellite instability/mismatch repair-deficient cancer: Results from the phase II KEYNOTE-158 study. J Clin Oncol 2020;38:1-10.
[17] Maio M, Ascierto PA, Manzyuk L, et al. Pembrolizumab in microsatellite instability high or mismatch repair deficient cancers: Updated analysis from the phase II KEYNOTE-158 study. Ann Oncol 2022;33:929-938.
[18] André T, Berton D, Curigliano G, et al. Antitumor activity and safety of dostarlimab monotherapy in patients with mismatch repair deficient solid tumors: a nonrandomized controlled trial. JAMA Netw Open 2023;6:e2341165.
[19] Subbiah V, Cassier PA, Siena S, et al. Pan-cancer efficacy of pralsetinib in patients with RET fusion-positive solid tumors from the phase 1/2 ARROW trial. Nat Med 2022;28:1640-1645.
[20] Merino DM, McShane LM, Fabrizio D, et al. Establishing guidelines to harmonize tumor mutational burden (TMB): in silico assessment of variation in TMB quantification across diagnostic platforms: phase I of the Friends of Cancer Research TMB Harmonization Project. J Immunother Cancer 2020;8:e000147.

Note: All recommendations are category 2A unless otherwise indicated.

Version 1.2026, 03/10/26 © 2026 National Comprehensive Cancer Network® (NCCN®), All rights reserved. NCCN Guidelines® and this illustration may not be reproduced in any form without the express written permission of NCCN.

PLEASE NOTE that use of this NCCN Content is governed by the End-User License Agreement, and you MAY NOT distribute this Content or use it with any artificial intelligence model or tool.
Printed by Máximo López Chenlo on 5/4/2026 6:13:37 PM. Copyright © 2026 National Comprehensive Cancer Network, Inc. All Rights Reserved.

PRINCIPLES OF BIOMARKER TESTING
REFERENCES

[21] Marabelle A, Fakih M, Lopez J, et al. Association of tumour mutational burden with outcomes in patients with advanced solid tumours treated with pembrolizumab: prospective biomarker analysis of the multicohort, open-label, phase 2 KEYNOTE-158 study. Lancet Oncol 2020;21:1353-1365.
[22] Nakamura Y, Mizuno N, Sunakawa Y, et al. Tucatinib and trastuzumab for previously treated human epidermal growth factor receptor 2-positive metastatic biliary tract cancer (SGNTUC-019): A phase II basket study. J Clin Oncol 2023;41:5569-5578.
[23] Maynard H, Stadler ZK, Berger MF, et al. Germline alterations in patients with biliary tract cancers: A spectrum of significant and previously underappreciated findings. Cancer 2020;126:1995-2002.
[24] Samadder NJ, Riegert-Johnson D, Boardman L, et al. Comparison of universal genetic testing vs guideline-directed targeted testing for patients with hereditary cancer syndrome. JAMA Oncol 2021;7:230-237.
[25] Wardell CP, Fujita M, Yamada T, et al. Genomic characterization of biliary tract cancers identifies driver genes and predisposing mutations. J Hepatol 2018;68:959-969.
[26] Terashima T, Umemoto K, Takahashi H, et al. Germline mutations in cancer-predisposition genes in patients with biliary tract cancer. Oncotarget 2019;10:5949-5957.
[27] Breast Cancer Linkage C. Cancer risks in BRCA2 mutation carriers. J Natl Cancer Inst 1999;91:1310-1316.
[28] Mecklin JP, Jarvinen HJ, Virolainen M. The association between cholangiocarcinoma and hereditary nonpolyposis colorectal carcinoma. Cancer 1992;69:1112-1114.
[29] Lee H, Wang K, Johnson A, et al. Comprehensive genomic profiling of extrahepatic cholangiocarcinoma reveals a long tail of therapeutic targets. J Clin Pathol 2016;69:403-408.
[30] Mody K, Kasi PM, Yang J, et al. Circulating tumor DNA profiling of advanced biliary tract cancers. JCO Precis Oncol 2019;3:1-9.
[31] Aguado-Fraile E, Tassinari A, Ishii Y, et al. Molecular and morphological changes induced by ivosidenib correlate with efficacy in mutant-*IDH1* cholangiocarcinoma. Future Oncol 2021;17:2057-2074.
[32] Harding JJ, Kim JW, Oh DY, et al. Concordance analysis between tumor tissue HER2 status by immunohistochemistry (IHC) and in situ hybridization (ISH) and a translational analysis of plasma ctDNA in patients (pts) with biliary tract cancer (BTC): An exploratory analysis from the phase 2 HERIZON-BTC-01 trial [abstract]. J Clin Oncol 2025;43(Suppl):Abstract 4102.
[33] Hiraoka N, Nitta H, Ohba A, et al. Details of human epidermal growth factor receptor 2 status in 454 cases of biliary tract cancer. Hum Pathol 2020;105:9-19.
[34] Chmielecki J, Ross JS, Wang K, et al. Oncogenic alterations in ERBB2/HER2 represent potential therapeutic targets across tumors from diverse anatomic sites of origin. Oncologist 2015;20:7-12.
[35] Jonna S, Feldman RA, Swensen J,et al. Detection of NRG1 gene fusions in solid tumors. Clin Cancer Res 2019;25:4966-4972.
[36] Schram AM, Goto K, Kim DW, et al. Efficacy of zenocutuzumab in NRG1 fusion-positive cancer. N Engl J Med 2025;392:566-576.
[37] Severson E, Achyut BR, Nesline M, et al. RNA sequencing identifies novel NRG1 fusions in solid tumors that lack co-occurring oncogenic drivers. J Mol Diagn 2023;25:454-466.
[38] Hong DS, Fakih MG, Strickler JH, et al. KRAS^{G12C} inhibition with sotorasib in advanced solid tumors. N Engl J Med 2020;383:1207-1217.
[39] Skoulidis F, Li BT, Dy GK, et al. Sotorasib for lung cancers with *KRAS* p.G12C mutation. N Engl J Med 2021;384:2371-2381.
[40] Bekaii-Saab TS, Yaeger R, Spira AI, et al. Adagrasib in advanced solid tumors harboring a *KRAS*^{G12C} mutation. J Clin Oncol 2023;41:4097-4106.
[41] Goyal L, Zheng H, Yurgelun MB, et al. A phase 2 and biomarker study of cabozantinib in patients with advanced cholangiocarcinoma. Cancer 2017;123:1979-1988.
[42] Pant S, Saleh M, Bendell J, et al. A phase I dose escalation study of oral c-MET inhibitor tivantinib (ARQ 197) in combination with gemcitabine in patients with solid tumors. Ann Oncol 2014;25:1416-1421.
[43] Abou-Alfa GK, Meyer T, Cheng AL, et al. Cabozantinib in patients with advanced and progressing hepatocellular carcinoma. N Engl J Med 2018;379:54-63.
[44] Zhou Y, Lizaso A, Mao X, et al. Novel AMBRA1-ALK fusion identified by next-generation sequencing in advanced gallbladder cancer responds to crizotinib: A case report. Ann Transl Med 2020;8:1099.
[45] Gu TL, Deng X, Huang F, et al. Survey of tyrosine kinase signaling reveals ROS kinase fusions in human cholangiocarcinoma. PLoS One 2011;6:e15640.
[46] Argani P, Palsgrove DN, Anders RA, et al. A novel NIPBL-NACC1 gene fusion is characteristic of the cholangioblastic variant of intrahepatic cholangiocarcinoma. Am J Surg Pathol 2021;45:1550-1560.
[47] Augustin J, Gabignon C, Scriva A, et al. Testing for ROS1, ALK, MET, and HER2 rearrangements and amplifications in a large series of biliary tract adenocarcinomas. Virchows Arch 2020;477:33-45.

Note: All recommendations are category 2A unless otherwise indicated.

Version 1.2026, 03/10/26 © 2026 National Comprehensive Cancer Network® (NCCN®), All rights reserved. NCCN Guidelines® and this illustration may not be reproduced in any form without the express written permission of NCCN.

PLEASE NOTE that use of this NCCN Content is governed by the End-User License Agreement, and you MAY NOT distribute this Content or use it with any artificial intelligence model or tool.
Printed by Máximo López Chenlo on 5/4/2026 6:13:37 PM. Copyright © 2026 National Comprehensive Cancer Network, Inc. All Rights Reserved.

PRINCIPLES OF SYSTEMIC THERAPY[a,b]

Neoadjuvant Therapy[c] (for gallbladder cancer only)
Other Recommended
• See Principles of Systemic Therapy, Primary Treatment for Unresectable and Metastatic Disease (BIL-C 2 of 5)

Adjuvant Therapy[d,1]	
Preferred	Other Recommended
• Capecitabine (category 1)[e,2]	• Capecitabine/Gemcitabine[f,3] • Cisplatin/Gemcitabine[g,4] • Single agents: ▸ Fluorouracil/Leucovorin ▸ Gemcitabine

Agents Used with Concurrent Radiation
• Capecitabine • Fluorouracil

[a] Order does not indicate preference.
[b] For more information regarding *DPYD* testing, see the NCCN Guidelines for Colon Cancer.
[c] The decision to use neoadjuvant therapy needs to be individualized and in close consultation with surgical oncologist and multidisciplinary team. A period of 2 to 6 months with reassessment every 2 to 3 months is reasonable. There are limited clinical trial data to define a standard regimen or definitive benefit. Clinical trial participation is encouraged.
[d] Adjuvant therapy up to 6 months. Adjuvant chemotherapy or chemoradiation has been associated with survival benefit in patients with BTC, especially in patients with lymph node-positive disease.
[e] The phase III BILCAP study shows improved overall survival for adjuvant capecitabine in the per-protocol analysis, and the overall survival did not reach statistical significance in the intent-to-treat analysis.
[f] This regimen is commonly followed by chemoradiation in instances where the combination of chemotherapy and chemoradiation is recommended.
[g] If a patient is ineligible for cisplatin, carboplatin may be used.

References

Note: All recommendations are category 2A unless otherwise indicated.

Version 1.2026, 03/10/26 © 2026 National Comprehensive Cancer Network® (NCCN®), All rights reserved. NCCN Guidelines® and this illustration may not be reproduced in any form without the express written permission of NCCN.

PLEASE NOTE that use of this NCCN Content is governed by the End-User License Agreement, and you MAY NOT distribute this Content or use it with any artificial intelligence model or tool.
Printed by Máximo López Chenlo on 5/4/2026 6:13:37 PM. Copyright © 2026 National Comprehensive Cancer Network, Inc. All Rights Reserved.

PRINCIPLES OF SYSTEMIC THERAPY[a,b]

Primary Treatment for Unresectable and Metastatic Disease		
Preferred	Other Recommended	Useful in Certain Circumstances
• Cisplatin/Gemcitabine + Durvalumab (category 1)[g-j,4,5] • Cisplatin/Gemcitabine + Pembrolizumab (category 1)[g,i,j,k,4,6]	• Cisplatin/Gemcitabine (category 1)[g,4,7] • Albumin-bound Paclitaxel/Gemcitabine • Capecitabine/Gemcitabine • Capecitabine/Oxaliplatin • FOLFOX (Leucovorin/Fluorouracil/Oxaliplatin) • Gemcitabine/Oxaliplatin • Single agents: ▸ Capecitabine ▸ Fluorouracil/Leucovorin ▸ Gemcitabine	• Targeted therapy (BIL-C 3 of 5)

Subsequent-Line Therapy for Biliary Tract Cancers if Disease Progression[l]		
Preferred	Other Recommended	Useful in Certain Circumstances
• FOLFOX[8]	• FOLFIRI (Leucovorin/Fluorouracil/Irinotecan)[9] • Fluorouracil/Leucovorin/Liposomal Irinotecan (category 2B)[10-13] • Regorafenib (category 2B)[14] • See also: Preferred and Other Recommended Regimens for Unresectable and Metastatic Disease above	• Targeted therapy (BIL-C 3 of 5) • Nivolumab (category 2B)[i,j,m,15]

[a] Order does not indicate preference.
[b] For more information regarding *DPYD* testing, see the NCCN Guidelines for Colon Cancer.
[g] If a patient is ineligible for cisplatin, carboplatin may be used.
[h] This regimen is also a recommended treatment option for patients who developed recurrent disease >6 months after surgery with curative intent and >6 months after completion of adjuvant therapy.
[i] NCCN Guidelines for Management of Immune Checkpoint Inhibitor-Related Toxicities.
[j] For patients who have not been previously treated with a checkpoint inhibitor when used as subsequent-line therapy because there is a lack of data for use of immunotherapy in patients who have previously been treated with a checkpoint inhibitor.
[k] Pembrolizumab and berahyaluronidase alfa-pmph subcutaneous injection may be substituted for IV pembrolizumab. Pembrolizumab and berahyaluronidase alfa-pmph has different dosing and administration instructions compared to IV pembrolizumab.
[l] Treatment selection depends on clinical factors including previous treatment regimen/agent, somatic molecular testing results, and extent of liver dysfunction.
[m] Nivolumab and hyaluronidase-nvhy subcutaneous injection may be substituted for IV nivolumab. Nivolumab and hyaluronidase-nvhy has different dosing and administration instructions compared to IV nivolumab.

References

Note: All recommendations are category 2A unless otherwise indicated.

Version 1.2026, 03/10/26 © 2026 National Comprehensive Cancer Network® (NCCN®), All rights reserved. NCCN Guidelines® and this illustration may not be reproduced in any form without the express written permission of NCCN.

PLEASE NOTE that use of this NCCN Content is governed by the End-User License Agreement, and you MAY NOT distribute this Content or use it with any artificial intelligence model or tool.
Printed by Máximo López Chenlo on 5/4/2026 6:13:37 PM. Copyright © 2026 National Comprehensive Cancer Network, Inc. All Rights Reserved.

PRINCIPLES OF SYSTEMIC THERAPY[a,n]
TARGETED THERAPY

Primary Treatment for Unresectable and Metastatic Disease

Useful in Certain Circumstances

- For *NTRK1/2/3* gene fusion-positive tumors:
  - Entrectinib[16,17]
  - Larotrectinib[18]
  - Repotrectinib[19]
- For MSI-H/dMMR tumors:
  - Pembrolizumab[i,k,o,20-23]
- For TMB-H tumors:
  - Ipilimumab + Nivolumab (category 2B)[i,24]
- For *RET* gene fusion-positive tumors:
  - Pralsetinib (category 2B)[25]
  - Selpercatinib (category 2B)[26]
- For CCA with *NRG1* gene fusions:
  - Zenocutuzumab-zbco (category 2B)[27,28]

Subsequent-Line Therapy for Biliary Tract Cancers if Disease Progression[l]

Useful in Certain Circumstances

- For *NTRK1/2/3* gene fusion-positive tumors[p]:
  - Entrectinib[16,17]
  - Larotrectinib[18]
  - Repotrectinib[19]
- For MSI-H/dMMR tumors:
  - Pembrolizumab[i,j,k,o,20-23]
  - Dostarlimab-gxly (category 2B)[i,j,q,29]
- For TMB-H tumors:
  - Ipilimumab + Nivolumab[i,j,r,24]
  - Pembrolizumab[i,j,k,o,20,30]
- For *BRAF* V600E-mutated tumors
  - Dabrafenib/Trametinib[31,32]
- For HER2 (*ERBB2*)-positive tumors:
  - Fam-trastuzumab deruxtecan-nxki (IHC3+)[33]
  - Pertuzumab + Trastuzumab (IHC3+/ISH+/NGS+)[34]
  - Tucatinib + Trastuzumab (IHC3+/ISH+/NGS+)[35]
  - Zanidatamab-hrii (IHC3+)[36]
- For *RET* gene fusion-positive tumors:
  - Selpercatinib[26]
  - Pralsetinib (category 2B)[25]
- For *KRAS* G12C mutation-positive tumors:
  - Adagrasib[37]
- For CCA with *FGFR2* gene fusions or rearrangements[s]:
  - Futibatinib[38]
  - Pemigatinib[39]
  - Erdafitinib[t,40]
- For CCA with *IDH1* mutations
  - Ivosidenib (category 1)[41,42]
- For CCA with *NRG1* gene fusions:
  - Zenocutuzumab-zbco[27,28]

[a] Order does not indicate preference.
[i] NCCN Guidelines for Management of Immune Checkpoint Inhibitor-Related Toxicities.
[j] For patients who have not been previously treated with a checkpoint inhibitor when used as subsequent-line therapy because there is a lack of data for use of immunotherapy in patients who have previously been treated with a checkpoint inhibitor.
[k] Pembrolizumab and berahyaluronidase alfa-pmph subcutaneous injection may be substituted for IV pembrolizumab. Pembrolizumab and berahyaluronidase alfa-pmph has different dosing and administration instructions compared to IV pembrolizumab.
[l] Treatment selection depends on clinical factors including previous treatment regimen/agent, somatic molecular testing results, and extent of liver dysfunction.
[n] An FDA-approved biosimilar is an appropriate substitute for any recommended systemic biologic therapy in the NCCN Guidelines.
[o] There are limited clinical trial data to support pembrolizumab in this setting.
[p] Repotrectinib is an option if there was progression on a prior therapy, which may include prior TRK inhibitors. Entrectinib and larotrectinib should not be used if there was progression on prior TRK inhibitors.
[q] Dostarlimab-gxly is a recommended treatment option for patients with MSI-H/dMMR recurrent or advanced tumors that have progressed on or following prior treatment and who have no satisfactory alternative treatment options.
[r] For patients with disease refractory to standard therapies or who have no standard treatment options available.
[s] Futibatinib and pemigatinib are preferred over erdafitinib.
[t] The data available for this agent are from a smaller trial.

References

Note: All recommendations are category 2A unless otherwise indicated.

Version 1.2026, 03/10/26 © 2026 National Comprehensive Cancer Network® (NCCN®), All rights reserved. NCCN Guidelines® and this illustration may not be reproduced in any form without the express written permission of NCCN.

PLEASE NOTE that use of this NCCN Content is governed by the End-User License Agreement, and you MAY NOT distribute this Content or use it with any artificial intelligence model or tool.
Printed by Máximo López Chenlo on 5/4/2026 6:13:37 PM. Copyright © 2026 National Comprehensive Cancer Network, Inc. All Rights Reserved.

PRINCIPLES OF SYSTEMIC THERAPY
REFERENCES

[1] Horgan AM, Amir E, Walter T, Knox JJ. Adjuvant therapy in the treatment of biliary tract cancer: a systemic review and meta-analysis. J Clin Oncol 2012;30:1934-1940.
[2] Primrose JN, Fox RP, Palmer DH, et al. Capecitabine compared with observation in resected biliary tract cancer (BILCAP): a randomised, controlled, multicentre, phase 3 study. Lancet Oncol 2019;20:663-673.
[3] Ben-Josef E, Guthrie KA, El-Khoueiry AB, et al. SWOG S0809: A phase II intergroup trial of adjuvant capecitabine and gemcitabine followed by radiotherapy and concurrent capecitabine in extrahepatic cholangiocarcinoma and gallbladder carcinoma. J Clin Oncol 2015;33:2617-2622.
[4] Williams KJ, Picus J, Trinkhaus K, et al. Gemcitabine with carboplatin for advanced biliary tract cancers: a phase II single institution study. HPB (Oxford) 2010;12:418-426.
[5] Oh DY, He AR, Qin S, et al. Durvalumab plus gemcitabine and cisplatin in advanced biliary tract cancer. NEJM Evid 2022;1:EVIDoa2200015.
[6] Kelley RK, Ueno M, Yoo C, et al. Pembrolizumab in combination with gemcitabine and cisplatin compared with gemcitabine and cisplatin alone for patients with advanced biliary tract cancer (KEYNOTE-966): A randomised, double-blind, placebo-controlled, phase 3 trial. Lancet 2023;401:1853-1865.
[7] Valle J, Wasan H, Palmer DH, et al. Cisplatin plus gemcitabine versus gemcitabine for biliary tract cancer. N Engl J Med 2010;362:1273-1281.
[8] Lamarca A, Palmer DH, Wasan HS, et al. Second-line FOLFOX chemotherapy versus active symptom control for advanced biliary tract cancer (ABC-06): a phase 3, open-label, randomised, controlled trial. Lancet Oncol 2021;22:690-701.
[9] Caparica R, Lengele A, Bekolo W, Hendlisz A. FOLFIRI as second-line treatment of metastatic biliary tract cancer patients. Autops Case Rep 2019;9:e2019087.
[10] Yoo C, Saborowski A, Hyung J, et al. Liposomal irinotecan for previously treated patients with biliary tract cancer: A pooled analysis of NIFTY and NALIRICC trials. J Hepatol 2025;83:909-916.
[11] Hyung J, Kim I, Kim KP, et al. Treatment with liposomal irinotecan plus fluorouracil and leucovorin for patients with previously treated metastatic biliary tract cancer: the phase 2b NIFTY randomized clinical trial. JAMA Oncol 2023;9:692-699.
[12] Vogel A, Saborowski A, Wenzel P, et al. Nanoliposomal irinotecan and fluorouracil plus leucovorin versus fluorouracil plus leucovorin in patients with cholangiocarcinoma and gallbladder carcinoma previously treated with gemcitabine-based therapies (AIO NALIRICC): A multicentre, open-label, randomised, phase 2 trial. Lancet Gastroenterol Hepatol 2024;9:734-744.
[13] Hyung J, Kim I, Kim KP, et al. Treatment with liposomal irinotecan plus fluorouracil and leucovorin for patients with previously treated metastatic biliary tract cancer: The phase 2b NIFTY randomized clinical trial. JAMA Oncol 2023:e230016.
[14] Sun W, Patel A, Normolle D, et al. A phase 2 trial of regorafenib as a single agent in patients with chemotherapy-refractory, advanced, and metastatic biliary tract adenocarcinoma. Cancer 2019;125:902-909.
[15] Kim RD, Chung V, Alese OB, et al. A Phase 2 Multi-institutional study of nivolumab for patients with advanced refractory biliary tract cancer. JAMA Oncol 2020;6:888-894.
[16] Drilon A, Siena S, Ou SI, et al. Safety and antitumor activity of the multitargeted pan-TRK, ROS1, and ALK inhibitor entrectinib: Combined results from two phase I trials (ALKA-372-001 and STARTRK-1). Cancer Discov 2017;7:400-409.
[17] Doebele RC, Drilon A, Paz-Ares L, et al. Entrectinib in patients with advanced or metastatic NTRK fusion-positive solid tumours: integrated analysis of three phase 1-2 trials. Lancet Oncol 2020;21:271-282.
[18] Drilon A, Laetsch TW, Kummar S, et al. Efficacy of larotrectinib in TRK fusion-positive cancers in adults and children. N Engl J Med 2018;378:731-739.
[19] Besse B, Lin JJ, Bazhenova L, et al. Repotrectinib in NTRK fusion–positive advanced solid tumors: a phase 1/2 trial. Nat Med 2026;32:682-689.
[20] Sicklick JK, Kato S, Okamura R, et al. Molecular profiling of cancer patients enables personalized combination therapy: the I-PREDICT study. Nat Med 2019;25:744-750.
[21] Le DT, Durham JN, Smith KN, et al. Mismatch repair deficiency predicts response of solid tumors to PD-1 blockade. Science 2017;357:409-413.
[22] Marabelle A, Le DT, Ascierto PA, et al. Efficacy of pembrolizumab in patients with noncolorectal high microsatellite instability/mismatch repair-deficient cancer: Results from the phase II KEYNOTE-158 study. J Clin Oncol 2020;38:1-10.

Note: All recommendations are category 2A unless otherwise indicated.

Version 1.2026, 03/10/26 © 2026 National Comprehensive Cancer Network® (NCCN®), All rights reserved. NCCN Guidelines® and this illustration may not be reproduced in any form without the express written permission of NCCN.

PLEASE NOTE that use of this NCCN Content is governed by the End-User License Agreement, and you MAY NOT distribute this Content or use it with any artificial intelligence model or tool.
Printed by Máximo López Chenlo on 5/4/2026 6:13:37 PM. Copyright © 2026 National Comprehensive Cancer Network, Inc. All Rights Reserved.

PRINCIPLES OF SYSTEMIC THERAPY
REFERENCES

[23] Maio M, Ascierto PA, Manzyuk L, et al. Pembrolizumab in microsatellite instability high or mismatch repair deficient cancers: Updated analysis from the phase II KEYNOTE-158 study. Ann Oncol 2022;33:929-938.
[24] Schenker M, Burotto M, Richardet M, et al. Randomized, open-label, phase 2 study of nivolumab plus ipilimumab or nivolumab monotherapy in patients with advanced or metastatic solid tumors of high tumor mutational burden. J Immunother Cancer 2024;12:e008872.
[25] Subbiah V, Cassier PA, Siena S, et al. Pan-cancer efficacy of pralsetinib in patients with RET fusion-positive solid tumors from the phase 1/2 ARROW trial. Nat Med 2022;28:1640-1645.
[26] Subbiah V, Wolf J, Konda B, et al. Tumour-agnostic efficacy and safety of selpercatinib in patients with RET fusion-positive solid tumours other than lung or thyroid tumours (LIBRETTO-001): A phase 1/2, open-label, basket trial. Lancet Oncol 2022;23:1261-1273.
[27] Schram AM, Goto K, Kim DW, et al. Efficacy of zenocutuzumab in NRG1 fusion-positive cancer. N Engl J Med 2025;392:566-576.
[28] Schram AM, Cleary JM, Arnold D, et al. Zenocutuzumab efficacy and safety in advanced NRG1+ cholangiocarcinoma: Analysis from the phase 2 eNRGy Trial [abstract]. Mol Cancer Ther 2025;24(Suppl):Abstract A102.
[29] André T, Berton D, Curigliano G, et al. Antitumor activity and safety of dostarlimab monotherapy in patients with mismatch repair deficient solid tumors: a nonrandomized controlled trial. JAMA Netw Open 2023;6:e2341165.
[30] Merino DM, McShane LM, Fabrizio D, et al. Establishing guidelines to harmonize tumor mutational burden (TMB): in silico assessment of variation in TMB quantification across diagnostic platforms: phase I of the Friends of Cancer Research TMB Harmonization Project. J Immunother Cancer 2020;8:e000147.
[31] Subbiah V, Lassen U, Élez E, et al. Dabrafenib plus trametinib in patients with BRAF^{V600E}-mutated biliary tract cancer (ROAR): a phase 2, open-label, single-arm, multicentre basket trial. Lancet Oncol 2020;21:1234-1243.
[32] Salama AKS, Li S, Macrae ER, et al. Dabrafenib and trametinib in patients with tumors with *BRAF*^{V600E} mutations: Results of the NCI-MATCH trial subprotocol H. J Clin Oncol 2020;38:3895-3904.
[33] Meric-Bernstam F, Makker V, Oaknin A, et al. Efficacy and safety of trastuzumab deruxtecan in patients with HER2-expressing solid tumors: Primary results from the DESTINY-PanTumor02 phase II trial. J Clin Oncol 2024;42:47-58.
[34] Javle M, Borad MJ, Azad NS, et al. Pertuzumab and trastuzumab for HER2-positive metastatic biliary tract cancer (MyPathway): A multicentre, open-label, phase 2a, multiple basket study. Lancet Oncol 2021;22:1290-1300.
[35] Nakamura Y, Mizuno N, Sunakawa Y, et al. Tucatinib and trastuzumab for previously treated human epidermal growth factor receptor 2-positive metastatic biliary tract cancer (SGNTUC-019): A phase II basket study. J Clin Oncol 2023;41:5569-5578.
[36] Harding JJ, Fan J, Oh DY, et al. Zanidatamab for HER2-amplified, unresectable, locally advanced or metastatic biliary tract cancer (HERIZON-BTC-01): a multicentre, single-arm, phase 2b study. Lancet Oncol 2023;24:772-782.
[37] Bekaii-Saab TS, Yaeger R, Spira AI, et al. Adagrasib in advanced solid tumors harboring a *KRAS*^{G12C} mutation. J Clin Oncol 2023;41:4097-4106.
[38] Goyal L, Meric-Bernstam F, Hollebecque A, et al. Futibatinib for *FGFR2*-rearranged intrahepatic cholangiocarcinoma. N Engl J Med 2023;388:228-239.
[39] Abou-Alfa GK, Sahai V, Hollebecque A, et al. Pemigatinib for previously treated, locally advanced or metastatic cholangiocarcinoma: a multicentre, open-label, phase 2 study. Lancet Oncol 2020;21:671-684.
[40] Pant S, Schuler M, Iyer G, et al. Erdafitinib in patients with advanced solid tumours with FGFR alterations (RAGNAR): an international, single-arm, phase 2 study. Lancet Oncol 2023;24:925-935.
[41] Abou-Alfa GK, Macarulla T, Javle MM, et al. Ivosidenib in IDH1-mutant, chemotherapy-refractory cholangiocarcinoma (ClarIDHy): a multicentre, randomised, double-blind, placebo-controlled, phase 3 study. Lancet Oncol 2020;21:796-807.
[42] Zhu AX, Macarulla T, Javle MM, et al. Final overall survival efficacy results of ivosidenib for patients with advanced cholangiocarcinoma with IDH1 mutation: The phase 3 randomized clinical ClarIDHy trial. JAMA Oncol 2021:7:1669-1677.

Note: All recommendations are category 2A unless otherwise indicated.

Version 1.2026, 03/10/26 © 2026 National Comprehensive Cancer Network® (NCCN®), All rights reserved. NCCN Guidelines® and this illustration may not be reproduced in any form without the express written permission of NCCN.

PLEASE NOTE that use of this NCCN Content is governed by the End-User License Agreement, and you MAY NOT distribute this Content or use it with any artificial intelligence model or tool.
Printed by Máximo López Chenlo on 5/4/2026 6:13:37 PM. Copyright © 2026 National Comprehensive Cancer Network, Inc. All Rights Reserved.

PRINCIPLES OF RADIATION THERAPY

General Principles

- All tumors irrespective of the location may be amenable to RT (ie, three-dimensional conformal RT [3D-CRT], intensity-modulated RT [IMRT]). Image-guided RT (IGRT) is strongly recommended when using RT, IMRT, and stereotactic body RT (SBRT) to improve treatment accuracy and reduce treatment-related toxicity.
- RT dosing is based on the ability to meet normal organ constraints and underlying liver function.[1]

- Unresectable tumors
  - SBRT: Doses ranging between 40–60 Gy (in 3–5 fractions; biologically effective dose [BED10] >100 Gy) is preferred if dose constraints can be met.[1,2]
  - Hypofractionation: Doses ranging between 58–67.5 Gy (in 15 fractions; median equivalent dose at 2 Gy $[EQD]_2$ 80.5 Gy) using photons[3] or protons[4] are recommended at centers with experience.
  - If unable to do SBRT/hypofractionation: Conventional fractionation (doses ranging from 60 Gy/30 fractions to 77 Gy/35 fractions)[5,6] or chemoradiation[a] up to 60 Gy/30 fractions[3] is recommended.

- Postoperative
  - Postoperative RT using conventional 3D-CRT or IMRT is an option for resected eCCA and gallbladder cancer.[7,8,9] Target volumes should cover the draining regional lymph nodes: porta hepatis, celiac, superior mesenteric, gastrohepatic, and para-aortic to 45 Gy at 1.8 Gy/fraction and 50–60 Gy in 1.8–2 Gy/fraction to the tumor bed depending on margin positivity.

- Palliative RT is appropriate for symptom control of primary tumor and metastatic lesions, such as bone or brain.
- Brachytherapy may be considered at experienced centers.[10]

Footnote

[a] Principles of Systemic Therapy (BIL-C).

References

[1] Apisarnthanarax S, Barry A, Cao M, et al. External beam radiation therapy for primary liver cancers: An ASTRO Clinical Practice Guideline. Pract Radiat Oncol 2022;12:28-51.
[2] Bowlus CL, Arrivé L, Bergquist A, et al. AASLD practice guidance on primary sclerosing cholangitis and cholangiocarcinoma. Hepatology 2023;77:659-702.
[3] Tao R, Krishnan S, Bhosale PR, et al. Ablative radiotherapy doses lead to a substantial prolongation of survival in patients with inoperable intrahepatic cholangiocarcinoma: a retrospective dose response analysis. J Clin Oncol 2016;34:219-226.
[4] Hong TS, Wo JY, Yeap BY, et al. Multi-institutional phase II study of high-dose hypofractionated proton beam therapy in patients with localized, unresectable hepatocellular carcinoma and intrahepatic cholangiocarcinoma. J Clin Oncol 2016;34:460-468.
[5] Fukuda K, Okumura T, Abei M, et al. Long-term outcomes of proton beam therapy in patients with previously untreated hepatocellular carcinoma. Cancer Sci 2017;108:497-503.
[6] Kim TH, Koh YH, Kim BH, et al. Proton beam radiotherapy vs. radiofrequency ablation for recurrent hepatocellular carcinoma: A randomized phase III trial. J Hepatol 2021;74:603-612.
[7] Ben-Josef E, Guthrie KA, El-Khoueiry AB, et al. SWOG S0809: A phase II intergroup trial of adjuvant capecitabine and gemcitabine followed by radiotherapy and concurrent capecitabine in extrahepatic cholangiocarcinoma and gallbladder carcinoma. J Clin Oncol 2015;33:2617-2622.
[8] Wang SJ, Lemieux A, Kalpathy-Cramer J, et al. Nomogram for predicting the benefit of adjuvant chemoradiotherapy for resected gallbladder cancer. J Clin Oncol 2011;29:4627-4632.
[9] Ostwal V, Patkar S, Engineer R, et al. Adjuvant gemcitabine plus cisplatin and chemoradiation in patients with gallbladder cancer: A randomized clinical trial. JAMA Oncol 2024;10:1116-1120.
[10] Li Z, Taner T, Eaton JE, et al. Development of the perihilar cholangiocarcinoma risk estimation of tumor recurrence after transplant (PRETREAT) score. Ann Surg 2025;282:503-514.

Note: All recommendations are category 2A unless otherwise indicated.

Version 1.2026, 03/10/26 © 2026 National Comprehensive Cancer Network® (NCCN®), All rights reserved. NCCN Guidelines® and this illustration may not be reproduced in any form without the express written permission of NCCN.

PLEASE NOTE that use of this NCCN Content is governed by the End-User License Agreement, and you MAY NOT distribute this Content or use it with any artificial intelligence model or tool.
Printed by Máximo López Chenlo on 5/4/2026 6:13:37 PM. Copyright © 2026 National Comprehensive Cancer Network, Inc. All Rights Reserved.

American Joint Committee on Cancer (AJCC)
TNM Staging for Gallbladder Carcinoma (8th ed., 2017)

Table 3. **Definitions for T, N, M**

T	**Primary Tumor**
TX	Primary tumor cannot be assessed
T0	No evidence of primary tumor
Tis	Carcinoma in *situ*
T1	Tumor invades lamina propria or muscular layer
T1a	Tumor invades lamina propria
T1b	Tumor invades muscle layer
T2	Tumor invades the perimuscular connective tissue on the peritoneal side, without involvement of the serosa (visceral peritoneum) Or tumor invades the perimuscular connective tissue on the hepatic side, with no extension into the liver
T2a	Tumor invades the perimuscular connective tissue on the peritoneal side, without involvement of the serosa (visceral peritoneum)
T2b	Tumor invades the perimuscular connective tissue on the hepatic side, with no extension into the liver
T3	Tumor perforates the serosa (visceral peritoneum) and/or directly invades the liver and/or one other adjacent organ or structure, such as the stomach, duodenum, colon, pancreas, omentum, or extrahepatic bile ducts
T4	Tumor invades main portal vein or hepatic artery or invades two or more extrahepatic organs or structures

N	**Regional Lymph Nodes**
NX	Regional lymph nodes cannot be assessed
N0	No regional lymph node metastasis
N1	Metastases to one to three regional lymph nodes
N2	Metastases to four or more regional lymph nodes

M	**Distant Metastasis**
M0	No distant metastasis
M1	Distant metastasis

Table 4. **AJCC Prognostic Groups**

	T	N	M
Stage 0	Tis	N0	M0
Stage I	T1	N0	M0
Stage IIA	T2a	N0	M0
Stage IIB	T2b	N0	M0
Stage IIIA	T3	N0	M0
Stage IIIB	T1-3	N1	M0
Stage IVA	T4	N0-1	M0
Stage IVB	Any T	N2	M0
	Any T	Any N	M1

Histologic Grade (G)

GX	Grade cannot be assessed
G1	Well differentiated
G2	Moderately differentiated
G3	Poorly differentiated

Used with permission of the American College of Surgeons, Chicago, Illinois. The original source for this information is the AJCC Cancer Staging Manual, Eighth Edition (2017) published by Springer International Publishing.

Continued

Version 1.2026, 03/10/26 © 2026 National Comprehensive Cancer Network® (NCCN®), All rights reserved. NCCN Guidelines® and this illustration may not be reproduced in any form without the express written permission of NCCN.

PLEASE NOTE that use of this NCCN Content is governed by the End-User License Agreement, and you MAY NOT distribute this Content or use it with any artificial intelligence model or tool.
Printed by Máximo López Chenlo on 5/4/2026 6:13:37 PM. Copyright © 2026 National Comprehensive Cancer Network, Inc. All Rights Reserved.

American Joint Committee on Cancer (AJCC)
TNM Staging for Intrahepatic Bile Duct Tumors (8th ed., 2017)

Table 5. **Definitions for T, N, M**

T		**Primary Tumor**
TX		Primary tumor cannot be assessed
T0		No evidence of primary tumor
Tis		Carcinoma *in situ* (intraductal tumor)
T1		Solitary tumor without vascular invasion, ≤5 cm or >5 cm
	T1a	Solitary tumor ≤5 cm without vascular invasion
	T1b	Solitary tumor >5 cm without vascular invasion
T2		Solitary tumor with intrahepatic vascular invasion or multiple tumors, with or without vascular invasion
T3		Tumor perforating the visceral peritoneum
T4		Tumor involving local extrahepatic structures by direct invasion

N	**Regional Lymph Nodes**
NX	Regional lymph nodes cannot be assessed
N0	No regional lymph node metastasis
N1	Regional lymph node metastasis present

M	**Distant Metastasis**
M0	No distant metastasis
M1	Distant metastasis present

Table 6. **AJCC Prognostic Groups**

	T	**N**	**M**
Stage 0	Tis	N0	M0
Stage IA	T1a	N0	M0
Stage IB	T1b	N0	M0
Stage II	T2	N0	M0
Stage IIIA	T3	N0	M0
Stage IIIB	T4	N0	M0
	Any T	N1	M0
Stage IV	Any T	Any N	M1

Histologic Grade (G)

GX	Grade cannot be assessed
G1	Well differentiated
G2	Moderately differentiated
G3	Poorly differentiated

Used with permission of the American College of Surgeons, Chicago, Illinois. The original source for this information is the AJCC Cancer Staging Manual, Eighth Edition (2017) published by Springer International Publishing.

Continued

Version 1.2026, 03/10/26 © 2026 National Comprehensive Cancer Network® (NCCN®), All rights reserved. NCCN Guidelines® and this illustration may not be reproduced in any form without the express written permission of NCCN.

PLEASE NOTE that use of this NCCN Content is governed by the End-User License Agreement, and you MAY NOT distribute this Content or use it with any artificial intelligence model or tool.
Printed by Máximo López Chenlo on 5/4/2026 6:13:37 PM. Copyright © 2026 National Comprehensive Cancer Network, Inc. All Rights Reserved.

American Joint Committee on Cancer (AJCC)
TNM Staging for Perihilar Bile Duct Tumors (8th ed., 2017)

Table 7. **Definitions for T, N, M**

T	**Primary Tumor**
TX	Primary tumor cannot be assessed
T0	No evidence of primary tumor
Tis	Carcinoma *in situ*/high-grade dysplasia
T1	Tumor confined to the bile duct, with extension up to the muscle layer or fibrous tissue
T2	Tumor invades beyond the wall of the bile duct to surrounding adipose tissue, or tumor invades adjacent hepatic parenchyma
T2a	Tumor invades beyond the wall of the bile duct to surrounding adipose tissue
T2b	Tumor invades adjacent hepatic parenchyma
T3	Tumor invades unilateral branches of the portal vein or hepatic artery
T4	Tumor invades main portal vein or its branches bilaterally, or the common hepatic artery; or unilateral second-order biliary radicals bilaterally with contralateral portal vein or hepatic artery involvement

N	**Regional Lymph Nodes**
NX	Regional lymph nodes cannot be assessed
N0	No regional lymph node metastasis
N1	One to three positive lymph nodes typically involving the hilar, cystic duct, common bile duct, hepatic artery, posterior pancreatoduodenal, and portal vein lymph nodes
N2	Four or more positive lymph nodes from the sites described for N1

M	**Distant Metastasis**
M0	No distant metastasis
M1	Distant metastasis

Table 8. **AJCC Prognostic Groups**

	T	**N**	**M**
Stage 0	Tis	N0	M0
Stage I	T1	N0	M0
Stage II	T2a-b	N0	M0
Stage IIIA	T3	N0	M0
Stage IIIB	T4	N0	M0
Stage IIIC	Any T	N1	M0
Stage IVA	Any T	N2	M0
Stage IVB	Any T	Any N	M1

Histologic Grade (G)

GX	Grade cannot be assessed
G1	Well differentiated
G2	Moderately differentiated
G3	Poorly differentiated

Used with permission of the American College of Surgeons, Chicago, Illinois. The original source for this information is the AJCC Cancer Staging Manual, Eighth Edition (2017) published by Springer International Publishing.

Continued

Version 1.2026, 03/10/26 © 2026 National Comprehensive Cancer Network® (NCCN®), All rights reserved. NCCN Guidelines® and this illustration may not be reproduced in any form without the express written permission of NCCN.

PLEASE NOTE that use of this NCCN Content is governed by the End-User License Agreement, and you MAY NOT distribute this Content or use it with any artificial intelligence model or tool.
Printed by Máximo López Chenlo on 5/4/2026 6:13:37 PM. Copyright © 2026 National Comprehensive Cancer Network, Inc. All Rights Reserved.

American Joint Committee on Cancer (AJCC)
TNM Staging for Distal Bile Ducts Tumors (8th ed., 2017)

Table 9. **Definitions for T, N, M**

T	**Primary Tumor**
TX	Primary tumor cannot be assessed
Tis	Carcinoma in situ/high-grade dysplasia
T1	Tumor invades the bile duct wall with a depth less than 5 mm
T2	Tumor invades the bile duct wall with a depth of 5–12 mm
T3	Tumor invades the bile duct wall with a depth greater than 12 mm
T4	Tumor involves the celiac axis, superior mesenteric artery, and/or common hepatic artery

N	**Regional Lymph Nodes**
NX	Regional lymph nodes cannot be assessed
N0	No regional lymph node metastasis
N1	Metastasis in one to three regional lymph nodes
N2	Metastasis in four or more regional lymph nodes

M	**Distant Metastasis**
M0	No distant metastasis
M1	Distant metastasis

Table 10. **AJCC Prognostic Groups**

	T	**N**	**M**
Stage 0	Tis	N0	M0
Stage I	T1	N0	M0
Stage IIA	T1	N1	M0
	T2	N0	M0
Stage IIB	T2	N1	M0
	T3	N0	M0
	T3	N1	M0
Stage IIIA	T1	N2	M0
	T2	N2	M0
	T3	N2	M0
Stage IIIB	T4	N0	M0
	T4	N1	M0
	T4	N2	M0
Stage IV	Any T	Any N	M1

Histologic Grade (G)

GX	Grade cannot be assessed
G1	Well differentiated
G2	Moderately differentiated
G3	Poorly differentiated

Used with permission of the American College of Surgeons, Chicago, Illinois. The original source for this information is the AJCC Cancer Staging Manual, Eighth Edition (2017) published by Springer International Publishing.

Version 1.2026, 03/10/26 © 2026 National Comprehensive Cancer Network® (NCCN®), All rights reserved. NCCN Guidelines® and this illustration may not be reproduced in any form without the express written permission of NCCN.

PLEASE NOTE that use of this NCCN Content is governed by the End-User License Agreement, and you MAY NOT distribute this Content or use it with any artificial intelligence model or tool.
Printed by Máximo López Chenlo on 5/4/2026 6:13:37 PM. Copyright © 2026 National Comprehensive Cancer Network, Inc. All Rights Reserved.

ABBREVIATIONS

3D-CRT	three-dimensional conformal radiation therapy
BED	biologically effective dose
BTC	biliary tract cancer
CCA	cholangiocarcinoma
CEA	carcinoembryonic antigen
CEUS	contrast-enhanced ultrasound
ctDNA	circulating tumor DNA
DEB	drug-eluting bead
dMMR	mismatch repair deficient
EQD	equivalent dose at 2 Gy
ERCP	endoscopic retrograde cholangiopancreatography
EUS	endoscopic ultrasound
FISH	fluorescence in situ hybridization
FLR	future liver remnant
FNA	fine-needle aspiration
H&P	history and physical
HBV	hepatitis B virus
HCC	hepatocellular carcinoma
HCV	hepatitis C virus
iCCA	intrahepatic cholangiocarcinoma
IGRT	image-guided radiation therapy
IHC	immunohistochemistry
IMRT	intensity-modulated radiation therapy
ISH	in situ hybridization
LFT	liver function test
MASLD	metabolic dysfunction-associated steatotic liver disease
MGPT	multigene panel testing
MMR	mismatch repair
MRCP	magnetic resonance cholangiopancreatography
MSI	microsatellite instability
MSI-H	microsatellite instability-high
NGS	next-generation sequencing
PCR	polymerase chain reaction
PD-L1	programmed death ligand 1
P/LP	pathogenic/likely pathogenic
PTC	percutaneous transhepatic cholangiography
PV	pathogenic variant
SBRT	stereotactic body radiation therapy
TACE	transarterial chemoembolization
TMB	tumor mutational burden
TMB-H	tumor mutational burden-high
UNOS	United Network for Organ Sharing

Version 1.2026, 03/10/26 © 2026 National Comprehensive Cancer Network® (NCCN®), All rights reserved. NCCN Guidelines® and this illustration may not be reproduced in any form without the express written permission of NCCN.

PLEASE NOTE that use of this NCCN Content is governed by the End-User License Agreement, and you MAY NOT distribute this Content or use it with any artificial intelligence model or tool.
Printed by Máximo López Chenlo on 5/4/2026 6:13:37 PM. Copyright © 2026 National Comprehensive Cancer Network, Inc. All Rights Reserved.

NCCN Categories of Evidence and Consensus	
Category 1	Based upon high-level evidence (≥1 randomized phase 3 trials or high-quality, robust meta-analyses), there is uniform NCCN consensus (≥85% support of the Panel) that the intervention is appropriate.
Category 2A	Based upon lower-level evidence, there is uniform NCCN consensus (≥85% support of the Panel) that the intervention is appropriate.
Category 2B	Based upon lower-level evidence, there is NCCN consensus (≥50%, but <85% support of the Panel) that the intervention is appropriate.
Category 3	Based upon any level of evidence, there is major NCCN disagreement that the intervention is appropriate.

All recommendations are category 2A unless otherwise indicated.

NCCN Categories of Preference	
Preferred	Interventions that are based on superior efficacy, safety, and evidence; and, when appropriate, affordability.
Other recommended	Other interventions that may be somewhat less efficacious, more toxic, or based on less mature data; or significantly less affordable for similar outcomes.
Useful in certain circumstances	Other interventions that may be used for selected patient populations (defined with recommendation).

All recommendations are considered appropriate.

PLEASE NOTE that use of this NCCN Content is governed by the End-User License Agreement, and you MAY NOT distribute this Content or use it with any artificial intelligence model or tool.
Printed by Máximo López Chenlo on 5/4/2026 6:13:37 PM. Copyright © 2026 National Comprehensive Cancer Network, Inc. All Rights Reserved.

Discussion

This discussion corresponds to the NCCN Guidelines for Biliary Tract Cancers. Last updated: July 2, 2025.

Table of Contents

Overview **MS-2**
Guidelines Update Methodology **MS-2**
Literature Search Criteria **MS-2**
Sensitive/Inclusive Language Usage **MS-2**
Gallbladder Cancer **MS-3**
Risk Factors MS-3
Staging and Prognosis MS-3
Diagnosis MS-4
Workup MS-4
Surgical Management MS-5
Management of Resectable Disease MS-6
Management of Unresectable or Metastatic Disease MS-8
Surveillance MS-8
Cholangiocarcinomas **MS-9**
Risk Factors MS-9
Staging and Prognosis MS-10
Diagnosis MS-11
Workup MS-11
Management of Intrahepatic Cholangiocarcinoma MS-12
Management of Extrahepatic Cholangiocarcinoma MS-17
Surveillance MS-18
Adjuvant Chemotherapy and Chemoradiation for Biliary Tract Cancers **MS-19**
Treatment for Advanced Biliary Tract Cancers **MS-21**
Immunotherapy Plus Chemotherapy MS-22
Chemotherapy Alone MS-22
Chemoradiation and Radiation Therapy MS-25
Targeted Therapy MS-25
Summary **MS-33**
Figure 1: Classification of Cholangiocarcinoma **MS-34**
References **MS-35**

Discussion update in progress

Version 1.2026 © 2026 National Comprehensive Cancer Network© (NCCN©), All rights reserved. NCCN Guidelines® and this illustration may not be reproduced in any form without the express written permission of NCCN.

PLEASE NOTE that use of this NCCN Content is governed by the End-User License Agreement, and you MAY NOT distribute this Content or use it with any artificial intelligence model or tool.
Printed by Máximo López Chenlo on 5/4/2026 6:13:37 PM. Copyright © 2026 National Comprehensive Cancer Network, Inc. All Rights Reserved.

Overview

Gallbladder cancer and bile duct cancer (intrahepatic and extrahepatic cholangiocarcinoma [CCA]) are highly lethal cancers and are collectively known as biliary tract cancers (BTCs). In 2025, it is estimated that 42,240 people in the United States will be diagnosed with liver cancer including intrahepatic bile duct cancer and an additional 12,610 people will be diagnosed with gallbladder cancer or other BTC.[1] Approximately 30,090 deaths from liver or intrahepatic bile duct cancer and 4400 deaths due to gallbladder cancer or other BTC are anticipated.

The NCCN Clinical Practice Guidelines in Oncology (NCCN Guidelines®) for Biliary Tract Cancers are the work of the members of the NCCN Biliary Tract Cancers Guidelines Panel. The types of BTCs covered in these guidelines include: gallbladder cancer, and intrahepatic and extrahepatic CCA. By definition, the NCCN Guidelines cannot incorporate all possible clinical variations and are not intended to replace good clinical judgment or individualization of treatments. Although not explicitly stated at every decision point of the guidelines, participation in prospective clinical trials is encouraged for the treatment of BTCs.

Guidelines Update Methodology

The complete details of the Development and Update of the NCCN Guidelines are available at www.NCCN.org.

Literature Search Criteria

Prior to the update of this version of the NCCN Guidelines® for Biliary Tract Cancers, an electronic search of the PubMed database was performed to obtain key literature in BTCs published since the previous Guidelines update, using the search terms: biliary tract cancer OR gallbladder cancer OR cholangiocarcinoma. The PubMed database was chosen because it remains the most widely used resource for medical literature and indexes only peer-reviewed biomedical literature.

The search results were narrowed by selecting studies in humans published in English. Results were confined to the following article types: Clinical Trial, Phase II; Clinical Trial, Phase III; Clinical Trial, Phase IV; Guideline; Practice Guideline; Randomized Controlled Trial; Meta-Analysis; Systematic Reviews; and Validation Studies. The data from key PubMed articles and articles from additional sources deemed as relevant to these Guidelines as discussed by the Panel have been included in this version of the Discussion section. Recommendations for which high-level evidence is lacking are based on the Panel's review of lower-level evidence and expert opinion.

Sensitive/Inclusive Language Usage

NCCN Guidelines strive to use language that advances the goals of equity, inclusion, and representation.[2] NCCN Guidelines endeavor to use language that is person-first; not stigmatizing; anti-racist, anti-classist, anti-misogynist, anti-ageist, anti-ableist, and anti-weight-biased; and inclusive of individuals of all sexual orientations and gender identities. NCCN Guidelines incorporate non-gendered language, instead focusing on organ-specific recommendations. This language is both more accurate and more inclusive and can help fully address the needs of individuals of all sexual orientations and gender identities. NCCN Guidelines will continue to use the terms *men*, *women*, *female*, and *male* when citing statistics, recommendations, or data from organizations or sources that do not use inclusive terms. Most studies do not report how sex and gender data are collected and use these terms interchangeably or inconsistently. If sources do not differentiate gender from sex assigned at birth or organs present, the information is presumed to predominantly represent cisgender individuals. NCCN encourages researchers to collect

Discussion update in progress

Version 1.2026 © 2026 National Comprehensive Cancer Network© (NCCN©), All rights reserved. NCCN Guidelines® and this illustration may not be reproduced in any form without the express written permission of NCCN.

PLEASE NOTE that use of this NCCN Content is governed by the End-User License Agreement, and you MAY NOT distribute this Content or use it with any artificial intelligence model or tool.
Printed by Máximo López Chenlo on 5/4/2026 6:13:37 PM. Copyright © 2026 National Comprehensive Cancer Network, Inc. All Rights Reserved.

more specific data in future studies and organizations to use more inclusive and accurate language in their future analyses.

Gallbladder Cancer

Gallbladder cancer is the most common anatomic subtype of BTC. The vast majority of gallbladder cancers are adenocarcinomas.[3] Incidence steadily increases with age, females are more likely to be diagnosed with gallbladder cancer than males, and incidence and mortality rates in the United States are highest among individuals of American Indian, Alaska Native, and Asian/Pacific Islander descent.[4,5] However, from 1973 to 2015, the incidence of gallbladder cancer has decreased in both males and females, white individuals, and individuals of American Indian/Alaskan Native and Asian/Pacific Islander descent but there was a small trend for an increase in Black individuals.[5] Globally, there are pockets of increased incidence in Korea; Japan; some areas of Eastern Europe and South America, especially Bolivia, Chile, and Spain; and in females in India, Pakistan, and Ecuador.[6-8] Gallbladder cancer is characterized by local and vascular invasion, regional lymph node metastasis, and distant metastases.

Risk Factors

Cholelithiasis with the presence of chronic inflammation is the most prevalent risk factor for gallbladder cancer, and the risk increases with stone size.[9,10] Calcification of the gallbladder wall (porcelain gallbladder), a result of chronic inflammation of the gallbladder, has also been regarded as a risk factor for gallbladder cancer, with historical estimates of cancer in up to 22% of gallbladders with calcification.[9] Subsequent reports, however, suggest that the risk of developing gallbladder cancer in patients with gallbladder calcification is lower than anticipated, with gallbladder cancer being present in 7% to 15% of these patients.[11-13] Other risk factors include anomalous pancreaticobiliary duct junction, gallbladder polyps (>1 cm), chronic typhoid infection, primary sclerosing cholangitis, and inflammatory bowel disease.[10,14-16] Adenomyomatosis of the gallbladder is also a potential, albeit somewhat controversial, risk factor. Prophylactic cholecystectomy is probably beneficial for patients who are at high risk of developing gallbladder cancer (eg, porcelain gallbladder, polyps >1 cm).[9] The Society of Radiologists in Ultrasound has proposed 3 risk categories for gallbladder polyps: extremely low risk, low risk, and indeterminate risk; and recommend a surgical consult for extremely low risk and low risk polyps ≥1.5 cm and for indeterminate risk polyps ≥0.7 cm.[17] Patients with a history of chronic cholecystitis or pancreaticobiliary maljunction have a greater prevalence of gallbladder cancers that are microsatellite instability-high (MSI-H).[18]

Staging and Prognosis

In the AJCC staging system, gallbladder cancer is classified into four stages based on the depth of invasion into the gallbladder wall and the extent of spread to surrounding organs and lymph nodes. In the revised 8th edition of the AJCC staging system, T2 gallbladder carcinoma was divided into two groups: tumors on the peritoneal side (T2a) and tumors on the hepatic side (T2b).[19] This revision is supported by two retrospective studies showing that gallbladder tumors located on the hepatic side is associated with worse prognosis, compared to tumors located on the peritoneal side.[20,21] However, it is important to note that it can be difficult to determine the location of the tumor, and gallbladder cancer can spread beyond the visible tumor, contributing to difficulty in predicting tumor location. Regional lymph node involvement is now staged according to number of positive nodes, as opposed to staging based on anatomic location of involved lymph nodes.

Tumor stage is the strongest prognostic factor for patients with gallbladder cancer.[22,23] Results from a retrospective analysis of 435 patients treated at a single center showed a median overall survival (OS) of 10.3 months for the entire cohort of patients.[23] The median survival was 12.9 and 5.8 months for those presenting with stage IA–III and stage IV disease,

Discussion update in progress

Version 1.2026 © 2026 National Comprehensive Cancer Network© (NCCN©), All rights reserved. NCCN Guidelines® and this illustration may not be reproduced in any form without the express written permission of NCCN.

PLEASE NOTE that use of this NCCN Content is governed by the End-User License Agreement, and you MAY NOT distribute this Content or use it with any artificial intelligence model or tool.
Printed by Máximo López Chenlo on 5/4/2026 6:13:37 PM. Copyright © 2026 National Comprehensive Cancer Network, Inc. All Rights Reserved.

respectively. It is important to note, however, that this retrospective analysis did not control well for treatment-related variables.[24] See the *Principles of Pathology* in the algorithm for recommendations pertaining to primary gallbladder cancer appropriate for resection.

Diagnosis

Gallbladder cancer is commonly diagnosed at an advanced stage because it is often asymptomatic in its early stages and has an aggressive nature that can spread rapidly. Another factor contributing to late diagnosis of gallbladder cancer is a clinical presentation that mimics that of biliary colic or chronic cholecystitis. Hence, it is common for a diagnosis of gallbladder cancer to be an incidental finding at cholecystectomy for presumed benign gallbladder disease or, more frequently, on pathologic review following cholecystectomy for symptomatic cholelithiasis. In a retrospective review of 435 patients diagnosed and treated with curative resection at a single center from 1995 to 2005, 123 patients (47%) were diagnosed with gallbladder cancer as an incidental finding after cholecystectomy.[23] Other possible clinical presentations of gallbladder cancer include a suspicious mass detected on ultrasound (US) or biliary tract obstruction with jaundice or chronic right upper quadrant abdominal pain. The presence of jaundice in patients with gallbladder cancer is associated with a poor prognosis; patients with jaundice are more likely to have advanced-stage disease (96% vs. 60%; $P < .001$) and significantly lower disease-specific survival (6 vs.16 months; $P < .0001$) than those without jaundice.[25] In a sample of 82 patients with gallbladder cancer who presented with jaundice, the resectability rate was low (7%), with even fewer having negative surgical margins (5%) and no disease-free survivors at 2 years.[25] In another study, 30% of patients with gallbladder cancer presenting with jaundice underwent resection with curative intent, compared to 75% of those without jaundice.[26] Jaundice also negatively impacted perioperative morbidity (69% vs. 38% in those without jaundice) and OS post-resection (median of 14 vs. 32 months in those without jaundice).

Workup

The initial workup of patients presenting with a gallbladder mass or disease suspicious for gallbladder cancer should include liver function tests and an assessment of hepatic reserve. High-quality multiphasic contrast-enhanced cross-sectional imaging (CT and/or MRI) of the chest, abdomen, and pelvis is recommended to evaluate tumor penetration through the wall of the gallbladder and the presence of nodal and distant metastases, and to detect the extent of direct tumor invasion of other organs/biliary system or major vascular invasion.[27] CT is more useful than US for the detection of lymph node involvement, adjacent organ invasion, and distant metastasis; MRI may be useful for distinguishing benign conditions from gallbladder cancer.[3] However, both techniques were unreliable in the detection of lymph node metastases that were smaller than 10 mm.[28] Although the role of PET scan has not been established in the evaluation of patients with gallbladder cancer, emerging evidence from retrospective studies indicates that it may be useful for the detection of radiologically occult regional lymph node and distant metastatic disease in patients with otherwise potentially resectable disease.[29-32] However, false positives related to an inflamed gallbladder are problematic.

For patients presenting with jaundice, additional workup should include cholangiography to evaluate for hepatic and biliary invasion of tumor. Noninvasive magnetic resonance cholangiography (MRCP) is preferred over endoscopic retrograde cholangiopancreatography (ERCP) or percutaneous transhepatic cholangiography (PTC), unless a therapeutic intervention is planned.[27]

Carcinoembryonic antigen (CEA) and CA 19-9 testing could be considered as part of initial workup (in conjunction with imaging studies). Elevated serum CEA levels or CA 19-9 levels could be suggestive of gallbladder cancer.[33] While CA 19-9 tends to have higher specificity (92.7% vs. 79.2% for CEA), its sensitivity tends to be lower (50% vs. 79.4% for CEA).

Discussion update in progress

Version 1.2026 © 2026 National Comprehensive Cancer Network© (NCCN©), All rights reserved. NCCN Guidelines® and this illustration may not be reproduced in any form without the express written permission of NCCN.

PLEASE NOTE that use of this NCCN Content is governed by the End-User License Agreement, and you MAY NOT distribute this Content or use it with any artificial intelligence model or tool.
Printed by Máximo López Chenlo on 5/4/2026 6:13:37 PM. Copyright © 2026 National Comprehensive Cancer Network, Inc. All Rights Reserved.

However, these markers are not specific for gallbladder cancer and CA 19-9 could also be elevated in patients with other cancers or jaundice from other causes. Therefore, the Panel recommends carrying out these tests as part of a baseline assessment, and not for diagnostic purposes.

Surgical Management

The surgical approach for the treatment of all patients with resectable gallbladder cancer is the same, with the exception that in patients with an incidental finding of gallbladder cancer on pathologic review, the gallbladder has been removed. Complete resection with negative margins remains the only potentially curative treatment for patients with gallbladder cancer.[34] The optimal resection consists of cholecystectomy with a limited hepatic resection (typically segments IVB and V) and portal lymphadenectomy to encompass the tumor with negative margins.[35] Lymphadenectomy should include lymph nodes in the porta hepatis, gastrohepatic ligament, and retroduodenal regions without routine resection of the bile duct. Extended hepatic resections (beyond segments IV B and V) and resection of the bile duct may be necessary in some patients to obtain negative margins, depending on the stage and location of the tumor, depth of tumor invasion, proximity to adjacent organs, and expertise of the surgeon.

A simple cholecystectomy is an adequate treatment for patients with T1a tumors, with the long-term survival rate approaching 100%.[36] Cholecystectomy combined with hepatic resection and lymphadenectomy is associated with an improved survival for patients with T2 or higher tumors. There is some controversy regarding the benefit of radical resection over simple cholecystectomy for patients with T1b tumors, and there is some risk of finding residual nodal or hepatic disease when re-resecting these patients.[37-42] Some studies have demonstrated an associated improvement in cancer-specific survival for patients with T1b and T2 tumors and no improvement in survival for patients with T3 tumors.[38-40] Other reports suggest that survival benefit associated with extended resection and lymphadenectomy is seen only in patients with T2 tumors and some T3 tumors with localized hepatic invasion and limited regional node involvement.[41,42] One meta-analysis noted that regional lymphadenectomy was associated with prolonged survival in patients with T1b, T2, and T3 tumors.[43] Vega et al[44] reported a recurrence-free survival (RFS) rate of 47% at 5 years in patients with gallbladder cancer that was T1b or greater following oncologic extended resection. T3 and T4 disease were identified as independent risk factors for recurrence at 24 months post extended resection.

Empiric major hepatic resection and bile duct resection have been shown to increase morbidity without any demonstrable difference in survival.[35,45] Bile duct resection was also not associated with a higher lymph node yield or improvements in survival.[46] A retrospective analysis of prospective data collected on 104 patients undergoing surgery for gallbladder cancer from 1990 to 2002 showed that in a multivariate analysis, higher T and N stage, poor differentiation, and common bile duct involvement were independent predictors of poor disease-specific survival.[45] Major hepatectomy and common bile duct excision significantly increased overall perioperative morbidity (53%) and were not independently associated with long-term survival. Fuks et al from the AFS-GBC-2009 study group also reported that bile duct resection resulted in a postoperative morbidity rate of 60% in patients with an incidental finding of gallbladder cancer.[35] However, for these patients, it has been suggested that common duct resection should be performed at the time of re-resection for those with positive cystic duct margins due to the presence of residual disease.[47] However, occasionally the cystic duct stump can be re-resected to a negative margin.

With these data in mind, the guidelines recommend that extended hepatic resections (beyond segments IV B and V) should be performed only when necessary to obtain negative margins (R0 resection) in well-selected

Discussion update in progress

Version 1.2026 © 2026 National Comprehensive Cancer Network© (NCCN©), All rights reserved. NCCN Guidelines® and this illustration may not be reproduced in any form without the express written permission of NCCN.

PLEASE NOTE that use of this NCCN Content is governed by the End-User License Agreement, and you MAY NOT distribute this Content or use it with any artificial intelligence model or tool.
Printed by Máximo López Chenlo on 5/4/2026 6:13:37 PM. Copyright © 2026 National Comprehensive Cancer Network, Inc. All Rights Reserved.

clinical situations as discussed above.[38,40-42] Bile duct excision should only be performed in the presence of adherent nodal disease and/or locally invasive disease or to obtain a negative cystic duct margin if necessary.[45]

Among patients with an incidental finding of gallbladder cancer, there is some evidence that a delayed resection due to referral to a tertiary cancer center or a radical resection following an initial noncurative procedure is not associated with a survival deficit compared with immediate resection.[48,49] However, these comparisons are difficult to interpret due to selection bias. Nevertheless, in all patients with convincing clinical evidence of gallbladder cancer, the guidelines recommend that surgery should be performed by an experienced surgeon who is prepared to do a definitive resection of the tumor. If malignancy is suspected or confirmed after cholecystectomy has been initiated and expertise is available, then definitive resection should be undertaken. If expertise is unavailable, patients should be referred to a center with available expertise. If the diagnosis is not clear, frozen section biopsies can be considered in selected cases before proceeding with definitive resection. The Panel is also of the opinion that surgery should not be performed in situations where the extent and resectability of the disease has not been established with good quality imaging. If malignancy is suspected before cholecystectomy has begun and there is a question of resectability (ie, locally advanced disease, possible metastatic disease, other), then definitive resection can be postponed regardless of available expertise, until complete staging and evaluation has been performed. All findings should be documented, and biopsy considered if chemotherapy is anticipated. Consultation with a pathologist with expertise in the hepatobiliary region should be considered, and careful review of the pathology report for T stage, cystic duct margin status, and other margins following surgery is crucial. If an imaging study shows a suspicious gallbladder mass, then the patient should be referred to an experienced center where they may be considered for upfront definitive resection.

Management of Resectable Disease

All patients should undergo cross-sectional imaging (CT and/or MRI) of the chest, abdomen, and pelvis prior to surgery to evaluate local extent of disease and the presence of distant metastases. Staging laparoscopy has been shown to identify radiographically occult disseminated disease in patients with primary gallbladder cancer.[50] In a prospective study that evaluated the role of staging laparoscopy in 409 patients diagnosed with primary gallbladder cancer, Agarwal et al reported a significantly higher yield in locally advanced tumors compared with early-stage tumors (25.2% vs. 10.7%; $P = .02$); the accuracy for detecting unresectable disease and a detectable lesion in locally advanced tumors (56.0% and 94.1%, respectively) was similar to that in early-stage tumors (54.6% and 100%, respectively).[50] In this study, the use of staging laparoscopy obviated the need for laparotomy in 55.9% of patients with unresectable disease. Staging laparoscopy, however, is of relatively low yield in patients with incidental finding of gallbladder cancer, since disseminated disease is relatively uncommon, and the patients have already had an assessment of their peritoneal cavity at the time of cholecystectomy.[51] Higher yields may be obtained in patients who are at higher risk for disseminated metastases (those with poorly differentiated, T3 or higher tumors or margin-positive tumors at cholecystectomy).[51]

In patients with a suspicious gallbladder mass discovered during surgery, a definitive resection with cholecystectomy and en bloc hepatic resection and lymphadenectomy is recommended when hepatobiliary surgery expertise is available. In cases where a suspicious gallbladder mass is discovered during surgery, but hepatobiliary surgery expertise is unavailable or resectability is unclear, the abdomen should be visually inspected, and all findings should be documented. Intraoperative staging, with or without biopsy, is recommended. The surgery should be ended and the patient should be referred to a specialist. Additional postoperative workup is recommended. Contraindications for resection include tumors with distant

Discussion update in progress

Version 1.2026 © 2026 National Comprehensive Cancer Network© (NCCN©), All rights reserved. NCCN Guidelines® and this illustration may not be reproduced in any form without the express written permission of NCCN.

PLEASE NOTE that use of this NCCN Content is governed by the End-User License Agreement, and you MAY NOT distribute this Content or use it with any artificial intelligence model or tool.
Printed by Máximo López Chenlo on 5/4/2026 6:13:37 PM. Copyright © 2026 National Comprehensive Cancer Network, Inc. All Rights Reserved.

lymph node metastases beyond the porta hepatis (most commonly the celiac axis or aortocaval groove [retropancreatic]) or distant metastatic disease (ie, most commonly liver and peritoneal cavity). Additionally, some tumors are unresectable based on local invasion of the porta hepatis and its vascular and biliary structures.

Among patients with an incidental finding of gallbladder cancer on pathologic review, those with T1a lesions may be observed if the tumor margins are negative since these tumors have not penetrated the muscle layer and long-term survival approaches 100% with simple cholecystectomy.[36] In a sample of 122 patients with gallbladder cancer diagnosed incidentally, identified in a prospectively maintained database, liver involvement at re-resection (after cholecystectomy) was associated with decreased RFS and disease-specific survival for patients with T2 tumors (median RFS was 12 months vs. not reached for patients without liver involvement, $P = .004$; median was 25 months vs. not reached for patients without liver involvement, $P = .003$) but not in patients with T1b tumors.[24]

As mentioned above, hepatic resection and lymphadenectomy with or without bile duct excision (for malignant involvement) is recommended for patients with T1b or greater lesions and/or with T1a lesions with positive margins.[38,40,41] Re-resection to achieve negative margins is recommended for these patients with incidental gallbladder cancer since a significant percentage of these patients have been found to harbor residual disease within the liver and common bile duct.[23,47] Furthermore, although randomized trials are lacking, re-resection is generally associated with improved OS compared to cholecystectomy alone. Port site disease is associated with disseminated peritoneal metastases, and prophylactic port site resection is not associated with improved survival or disease recurrence in patients with incidental findings of gallbladder cancer and, thus, should not be considered during definitive resection.[52,53]

For patients with a suspicious mass detected on imaging, the guidelines recommend cholecystectomy plus en bloc hepatic resection, and lymphadenectomy, with or without bile duct excision (for malignant involvement). A biopsy is not necessary in most cases and a diagnostic laparoscopy is recommended prior to definitive resection.[50] Jaundice in patients with gallbladder cancer is considered a relative contraindication to surgery, and outcomes are generally poor in these patients; only a rare group of patients with localized node-negative disease potentially benefit from complete resection.[25,54-56] In patients with jaundice, if gallbladder cancer is suspected, surgery should only be performed if a complete resection is feasible. These patients should be carefully evaluated prior to surgery and referral to an experienced center should be considered. The guidelines recommend consideration of preoperative biliary drainage for patients with jaundice. However, caution should be exercised in patients with biliary obstruction as drainage is not always feasible and can be dangerous. Decisions regarding biliary drainage should be made by an experienced multidisciplinary team.

Although there are limited clinical trial data to define a standard regimen or definitive benefit, the Panel recommends consideration of a course of neoadjuvant systemic therapy for patients with jaundice. Gallbladder cancer that is locally advanced or has lymph node involvement is associated with a poor prognosis, but neoadjuvant systemic therapy may allow the oncologist to evaluate the biology of the tumor and identify patients who are most likely to benefit from surgical intervention. A systematic review of eight studies found that approximately one third of the 474 patients achieved an R0 resection with the use of neoadjuvant chemotherapy or chemoradiotherapy.[57] In a retrospective analysis of 74 patients with locally advanced or lymph node-positive disease who received systemic therapy, 30% of patients underwent resection.[58] Out of the 22 patients who underwent resection, 45% underwent definitive resection, with OS being significantly greater for patients who underwent

Discussion update in progress

Version 1.2026 © 2026 National Comprehensive Cancer Network© (NCCN©), All rights reserved. NCCN Guidelines® and this illustration may not be reproduced in any form without the express written permission of NCCN.

PLEASE NOTE that use of this NCCN Content is governed by the End-User License Agreement, and you MAY NOT distribute this Content or use it with any artificial intelligence model or tool.
Printed by Máximo López Chenlo on 5/4/2026 6:13:37 PM. Copyright © 2026 National Comprehensive Cancer Network, Inc. All Rights Reserved.

definitive resection compared to those who did not (51 vs. 11 months, respectively; *P* = .003). Another study reported a response rate of 52.5% and a clinical benefit rate of 70% in 160 patients with gallbladder cancer treated with neoadjuvant chemotherapy. 41.2% of patients underwent resection with curative intent.[59] These patients had an associated prolonged OS (49 vs. 7 months; *P* = .0001) and event-free survival (25 vs. 5 months; *P* = .0001) compared to those who did not undergo resection. A phase III randomized study is underway to compare neoadjuvant chemotherapy versus neoadjuvant chemoradiation in patients with locally advanced gallbladder cancer (NCT02867865).[60]

In patients for whom there is evidence of locoregionally advanced disease (ie, nodal disease or evidence of other high-risk disease), neoadjuvant systemic therapy should be considered to rule out rapid progression and avoid futile surgery. The decision to use neoadjuvant therapy needs to be individualized and in close consultation with a surgical oncologist and a multidisciplinary team. A period of 2 to 6 months with reassessment every 2 to 3 months is reasonable. Neoadjuvant treatment options are included as other recommended regimens and are the same as those recommended for the primary treatment for unresectable and metastatic disease (see the *Principles of Systemic Therapy*). The Panel currently does not recommend neoadjuvant chemoradiation for these patients, although a prospective study including 28 patients with locally advanced gallbladder cancer showed that an R0 resection was achieved in 14 patients, with good local control (93%) and 5-year survival (47%), following treatment with gemcitabine with concurrent radiation therapy (RT).[61]

A combination of chemotherapy (gemcitabine-based or fluoroypyrimidine-based) and chemoradiation may be options for adjuvant treatment. See the section on *Adjuvant Chemotherapy* and *Chemoradiation for Biliary Tract Cancers*.

Management of Unresectable or Metastatic Disease

Preoperative evaluation and a biopsy to confirm the diagnosis is recommended for patients with unresectable (includes tumors with distant lymph node metastases in the celiac axis or aortocaval groove) or metastatic disease (includes distant metastases, nodal metastases beyond the porta hepatis, and extensive involvement of the porta hepatis causing jaundice or vascular encasement). Molecular testing is recommended. Primary options for these patients include: 1) systemic therapy (preferred); 2) clinical trial (preferred); or 3) best supportive care. In addition, palliative RT is included as an option for patients with unresectable disease. See sections on *Chemotherapy* and *Chemoradiation and Radiation Therapy* for *Treatment for Advanced Biliary Tract Cancers*. Following primary treatment, except for those receiving best supportive care, the disease should be assessed for response. Resection or locoregional therapy should be reconsidered. Subsequent-line systemic therapy is an option if there is progression on or after systemic therapy.

In patients with unresectable or metastatic gallbladder cancer and jaundice, biliary drainage is an appropriate palliative procedure and should be considered before instituting resection and systemic therapy if technically feasible.[54] However, caution should be exercised in patients with biliary obstruction as drainage is not always feasible and can be dangerous due to extensive segmental biliary isolation. Decisions regarding biliary drainage should be made by a multidisciplinary team and carefully planned. Biliary drainage followed by chemotherapy can result in improved quality of life. CA 19-9 testing can be considered after biliary decompression.

Surveillance

There are no data to support a specific surveillance schedule or tests following resection of gallbladder cancer; determination of appropriate follow-up schedule/imaging should include a careful patient/physician discussion. Follow-up of patients undergoing an extended cholecystectomy

Discussion update in progress

Version 1.2026 © 2026 National Comprehensive Cancer Network© (NCCN©), All rights reserved. NCCN Guidelines® and this illustration may not be reproduced in any form without the express written permission of NCCN.

PLEASE NOTE that use of this NCCN Content is governed by the End-User License Agreement, and you MAY NOT distribute this Content or use it with any artificial intelligence model or tool.
Printed by Máximo López Chenlo on 5/4/2026 6:13:37 PM. Copyright © 2026 National Comprehensive Cancer Network, Inc. All Rights Reserved.

for gallbladder cancer should include consideration of imaging studies every 3 to 6 months for 2 years, then every 6 to 12 months for up to 5 years, or as clinically indicated. Assessment of CEA and CA 19-9 may also be considered as clinically indicated. Re-evaluation according to the initial workup should be considered in the event of disease relapse or progression. In a study of 217 patients who underwent surgery with curative intent, 35.0% had a recurrence at the last follow-up, with a median time to recurrence of 9.5 months.[62] The authors note that recurrence occurred within a 2-year time-frame post-surgery in most patients.

Cholangiocarcinomas

Cholangiocarcinomas encompass tumors originating in the epithelium of the biliary tree. More than 90% of CCAs are adenocarcinomas and are broadly divided into three histologic types based on their growth patterns: mass-forming, periductal-infiltrating, and intraductal-growing.[63] CCAs are diagnosed throughout the biliary tree and are typically classified as either intrahepatic or extrahepatic CCA. Extrahepatic CCAs are more common than intrahepatic CCAs.[64] Analyses of SEER data from 2001 to 2017 showed that incidence of intrahepatic CCA increased dramatically (148.8%), while incidence of extrahepatic CCA increased at a slower rate (7.5%).[65] The increase in incidence of intrahepatic CCA may have been due to an improvement in the ability to accurately diagnose intrahepatic CCA, such as with imaging, molecular diagnostics, and pathology.[66] These cancers might have previously been diagnosed as cancers of unknown primary, for which incidence decreased from 1973 to 2012 (annual percentage change, -1.87%).[66] Five-year OS rates for CCA improved from 1973 to 2008, likely due to improvements in treatment for this disease.[67]

Intrahepatic CCAs are located within the hepatic parenchyma and have also been called “peripheral CCAs” (Figure 1). Extrahepatic CCAs occur anywhere within the extrahepatic bile duct—from the junction of the right and left hepatic ducts to the common bile duct, including the intrapancreatic portion (Figure 1)—and are further classified into hilar or distal tumors. Hilar or perihilar CCAs (also called Klatskin tumors) occur at or near the junction of the right and left hepatic ducts including the common hepatic duct; distal CCAs are extrahepatic lesions arising in the extrahepatic bile ducts above the ampulla of Vater and below the junction of the common hepatic duct and cystic duct.[64] Perihilar CCAs are the most common type of extrahepatic CCAs.

The NCCN Guidelines discuss the clinical management of intrahepatic and extrahepatic CCAs including hilar and distal subtypes. Tumors of the ampulla of Vater are not included in the NCCN Guidelines for Biliary Tract Cancers.

Risk Factors

No predisposing factors are identified in most patients diagnosed with CCA,[68] although there is evidence that particular risk factors may be associated with the disease in some patients. These risk factors, like those for gallbladder cancer, are associated with the presence of chronic inflammation. Primary sclerosing cholangitis, chronic calculi of the bile duct (hepatolithiasis), choledochal cysts, and liver fluke infections are well-established risk factors for CCA. Unlike gallbladder cancer, however, cholelithiasis is not thought to be linked with CCA.[69] Inflammatory bowel disease may also be a risk factor for CCA, although this association may be confounded by primary sclerosing cholangitis.[70] Other risk factors specific to intrahepatic CCA, which tends to be similar to hepatocellular carcinoma (HCC), have been found to include hepatitis B virus (HBV) infection, cirrhosis, diabetes, obesity, alcohol, and tobacco.[71] A systematic review and meta-analysis reported that the strongest risk factors for both intrahepatic and extrahepatic CCA included biliary cysts and stones, cirrhosis, HBV, and hepatitis C virus.[72] This may be responsible for the increased incidence of intrahepatic CCA observed at some centers, although future studies are needed to further explore this putative

Discussion update in progress

Version 1.2026 © 2026 National Comprehensive Cancer Network© (NCCN©), All rights reserved. NCCN Guidelines® and this illustration may not be reproduced in any form without the express written permission of NCCN.

PLEASE NOTE that use of this NCCN Content is governed by the End-User License Agreement, and you MAY NOT distribute this Content or use it with any artificial intelligence model or tool.
Printed by Máximo López Chenlo on 5/4/2026 6:13:37 PM. Copyright © 2026 National Comprehensive Cancer Network, Inc. All Rights Reserved.

association.[73] A systematic review including seven case-control studies (9102 patients and 129,111 controls) showed that metabolic dysfunction-associated steatotic liver disease is associated with increased incidence of both intrahepatic (pooled adjusted OR, 2.09; 95% CI, 1.49–2.91) and extrahepatic CCA (pooled adjusted OR, 2.05; 95% CI, 1.59–2.64).[74]

Staging and Prognosis

Intrahepatic Cholangiocarcinoma

In the 6th edition of the AJCC staging system, intrahepatic CCA was staged identically to HCC. However, this staging system did not include predictive clinicopathologic features (multiple hepatic tumors, regional nodal involvement, and large tumor size) that are specific to intrahepatic CCA.[75] In some reports, tumor size had no effect on survival in patients undergoing complete resection.[76,77] In a SEER database analysis of 598 patients with intrahepatic CCA who had undergone surgery, Nathan et al reported that multiple lesions and vascular invasion predicted adverse prognosis following resection; lymph node status was of prognostic significance among patients without distant metastases.[76] In this study, tumor size had no independent effect on survival. These findings were confirmed in a subsequent multi-institutional international study of 449 patients undergoing surgery for intrahepatic CCA.[77] The 5-year survival rate was higher for patients who lacked all three risk factors (multiple tumors, vascular invasion, and N1 disease) than for those with ≥1 risk factors (38.3%, 27.3%, and 18.1%, respectively) and, more importantly, tumor number and vascular invasion were of prognostic significance only in patients with N0 disease. Although tumor size was associated with survival in the univariate analysis, it was not of prognostic significance in a multivariate analysis.

In the revised 7th edition of the AJCC staging system, intrahepatic CCA had a new staging classification that was independent of the staging classification used for HCC.[78] This classification focused on multiple tumors, vascular invasion, and lymph node metastasis. Farges et al from the AFC-IHCC study group validated this staging classification in 163 patients with resectable intrahepatic CCA.[79] The revised classification was useful in predicting survival according to the TNM staging. With a median follow-up of 34 months, the median survival was not reached for patients with stage I disease, was 53 months for those with stage II disease (P = .01), and was 16 months for those with stage III disease (P < .0001).

In the revised 8th edition of the AJCC staging system, T1 disease (ie, solitary tumor without vascular invasion) should now be staged according to tumor size (ie, T1a refers to a tumor that is ≤5 cm, while T1b refers to a tumor that is >5 cm).[19] T2 disease, on the other hand, is no longer divided into T2a (solitary tumor with vascular invasion) and T2b (multiple tumors with or without vascular invasion) disease. See the *Principles of Pathology* in the algorithm for recommendations pertaining to intrahepatic CCA appropriate for biopsy and for patients undergoing resection.

Extrahepatic Cholangiocarcinoma

The 7th edition of the AJCC staging system included a separate TNM classification for hilar and distal extrahepatic CCA, based on the extent of liver involvement and distant metastatic disease.[78] In the revised 8th edition of the AJCC staging system, regional lymph node involvement is now staged according to number of positive nodes.[19] Depth of tumor invasion is an independent predictor of outcome in patients with distal as well as hilar CCAs.[80,81] In the revised 8th edition of the AJCC staging system for cancer of the distal bile duct, depth of tumor invasion has been added to the categorization of T1, T2, and T3 tumors.[19]

The modified Bismuth-Corlette staging system[82] and the Blumgart staging system[83] are used for the classification of hilar CCAs. The modified Bismuth-Corlette staging system classifies hilar CCAs into four types based on the extent of biliary involvement. However, this does not include other clinicopathologic features such as vascular encasement, lymph node

Discussion update in progress

Version 1.2026 © 2026 National Comprehensive Cancer Network© (NCCN©), All rights reserved. NCCN Guidelines® and this illustration may not be reproduced in any form without the express written permission of NCCN.

PLEASE NOTE that use of this NCCN Content is governed by the End-User License Agreement, and you MAY NOT distribute this Content or use it with any artificial intelligence model or tool.
Printed by Máximo López Chenlo on 5/4/2026 6:13:37 PM. Copyright © 2026 National Comprehensive Cancer Network, Inc. All Rights Reserved.

involvement, distant metastases, and liver atrophy. In addition, both the AJCC and the Bismuth-Corlette staging systems are not useful for predicting resectability or survival. The Blumgart staging system is a useful preoperative staging system that predicts resectability, likelihood of metastatic disease, and survival.[83,84] In this staging system, hilar CCAs are classified into three stages (T1–T3) based on the location and extent of bile duct involvement, the presence or absence of portal venous invasion, and hepatic lobar atrophy.[83] Negative histologic margins, concomitant partial hepatectomy, and well-differentiated tumor histology were associated with improved outcome after resection; increasing T stage significantly correlated with reduced R0 resection rate, distant metastatic disease, and lower median survival.[84] See the *Principles of Pathology* in the algorithm for recommendations pertaining to extrahepatic CCA appropriate for biopsy and for patients undergoing resection.

Diagnosis

Early-stage CCA may only manifest as mild changes in serum liver function tests (particularly alkaline phosphatase). Patients with intrahepatic CCA, due to their often late presentation, are more likely to present with nonspecific symptoms such as fever, weight loss, and/or abdominal pain; symptoms of biliary obstruction are uncommon because these tumors do not necessarily involve the common hepatic/bile duct. Intrahepatic CCA may be detected incidentally as an isolated intrahepatic mass on imaging.[85] In contrast, patients with extrahepatic CCA are likely to present with jaundice followed by evidence of a biliary obstruction or abnormality on subsequent imaging.

Workup

The initial workup should include liver function tests. CEA and CA 19-9 testing can be considered for baseline assessment, although these markers are not specific for CCA; they are also associated with other malignancies and benign conditions.[86] CA 19-9 may be falsely elevated due to jaundice.[87] Viral hepatitis serologies should be considered for intrahepatic CCA. If viral hepatitis is diagnosed, it needs to be monitored and managed following ASCO's guidelines.[88] Since the diagnosis of HCC versus intrahepatic CCA can be difficult, alpha-fetoprotein (AFP) testing may also be considered, especially in patients with chronic liver disease. Further, there are a number of mixed HCC/intrahepatic CCA cases in which AFP may be elevated. Liver Imaging Reporting and Data System provides some guidance in distinguishing between HCC and intrahepatic CCA lesions.[89]

Early surgical consultation (prior to drainage in patients with jaundice) with a multidisciplinary team is recommended as part of the initial workup for assessment of resectability in intrahepatic and extrahepatic CCAs. The Panel emphasizes that a multidisciplinary review of imaging studies involving experienced radiologists and surgeons is necessary to stage the disease and determine potential treatment options (ie, resection or other approach). Providers should only proceed with biopsy once transplant (for patients with extrahepatic CCA) or resectability status has been determined. For patients with hilar CCA who may be candidates for transplant, transperitoneal biopsy is contraindicated and will likely preclude transplantation based on current protocols.[90] For patients undergoing resection, biopsy is usually not necessary. However, it should be noted that approximately 5% to 10% of these cases will turn out to be benign.[91]

Tissue diagnosis from the most accessible site is necessary to document the disease, obtain genomics information, and start treatment. Multiphasic abdomen and pelvis CT/MRI IV contrast to assess the involvement of the liver, major vessels, nearby lymph nodes, and distant sites is also recommended when extrahepatic CCA is suspected.[92,93] There are no pathognomonic CT/MRI features associated with intrahepatic CCA, but CT/MRI can indicate the involvement of major vessels and the presence of vascular anomalies and satellite lesions.[92,94,95] Therefore, multiphasic

Discussion update in progress

Version 1.2026 © 2026 National Comprehensive Cancer Network© (NCCN©), All rights reserved. NCCN Guidelines® and this illustration may not be reproduced in any form without the express written permission of NCCN.

PLEASE NOTE that use of this NCCN Content is governed by the End-User License Agreement, and you MAY NOT distribute this Content or use it with any artificial intelligence model or tool.
Printed by Máximo López Chenlo on 5/4/2026 6:13:37 PM. Copyright © 2026 National Comprehensive Cancer Network, Inc. All Rights Reserved.

CT/MRI with IV contrast is used to help determine tumor resectability by characterizing the primary tumor, its relationship to nearby major vessels and the biliary tree, the presence of satellite lesions and distant metastases in the liver, and lymph node involvement.[85,92] Multiphasic abdomen/pelvis CT/MRI with IV contrast is preferred for intrahepatic CCA; however, contrast-enhanced US is also an option. In addition, chest CT (with or without contrast) should be performed, and staging laparoscopy may be considered in conjunction with surgery if no distant metastasis is found. The American College of Radiology has published recommendations for liver MRI.[96] Imaging evaluation for suspected extrahepatic CCA is ideally performed prior to biliary decompression to facilitate accurate local staging for surgical candidacy.

Endoscopic US may be useful for distal common bile duct cancers for defining a mass or abnormal thickening, which can direct biopsies. For hilar CCA, endoscopic US should only be done after surgical consultation to prevent jeopardizing a patient's candidacy for transplantation. Esophagogastroduodenoscopy and colonoscopy are recommended as part of initial workup for patients with intrahepatic CCA since a mass diagnosed as adenocarcinoma can be metastatic disease. Pathologic workup can be suggestive of CCA but is not definitive. IgG4-associated cholangitis, which presents with biliary strictures and obstructive jaundice, may mimic extrahepatic CCA.[97,98] Therefore, serum IgG4 should be considered to rule out autoimmune cholangitis in patients for whom a diagnosis of extrahepatic CCA is not clear, in order to avoid an unnecessary surgical resection.[99,100] Patients with IgG4-related cholangiopathy should be referred to an expert center.

Contrast-enhanced MRCP and/or CT as a diagnostic modality is recommended over direct cholangiography for the diagnosis of bile duct cancers.[101,102] MRCP has been shown to have a higher sensitivity, specificity, and diagnostic accuracy compared to ERCP in the diagnosis and pre-treatment staging of hilar CCAs.[103] Data also support the use of MRCP and CT as the preferred method of cholangiography for the assessment of bile duct tumors.[104] Direct cholangiography should only be performed when necessary as a diagnostic procedure in patients with unresectable disease or in patients in whom a therapeutic intervention is necessary. ERCP/PTC is not recommended for the diagnosis of extrahepatic CCA, since this is associated with complications and contamination of the biliary tree. For distal bile duct tumors in which a diagnosis is needed or where palliation is indicated, an ERCP allows for complete imaging of the bile duct and stenting of the obstruction. In addition, brush cytology of the bile duct can be obtained for pathologic evaluation. Since many of the patients with extrahepatic CCA present with jaundice, workup should include noninvasive cholangiography with cross-sectional imaging to evaluate local tumor extent.[92] Although the role of PET imaging has not been established in the evaluation of patients with CCA, emerging evidence indicates that it may be useful for the detection of regional lymph node metastases and distant metastatic disease in patients with otherwise potentially resectable disease.[29-31,105,106]

Discussion update in progress

Management of Intrahepatic Cholangiocarcinoma

Patients with intrahepatic CCA should be evaluated for potentially curative therapies (resection; and for small lesions, ablation). However, most patients are not candidates for surgery due to the presence of advanced disease at diagnosis. The optimal surgical margin associated with improved survival and reduced risk of recurrence in patients undergoing surgery remains uncertain, with some reports documenting R0 resection as a significant predictor of survival and recurrence,[107-112] while others suggest that margin status is not a significant predictor of outcome.[113,114] Ribero et al from the Italian Intrahepatic Cholangiocarcinoma Study Group reported that margin-negative resection was associated with significantly higher survival rates (the estimated 5-year survival rates were 39.8% vs. 4.7% for patients with a positive margin) and significantly lower recurrence rates

Version 1.2026 © 2026 National Comprehensive Cancer Network© (NCCN©), All rights reserved. NCCN Guidelines® and this illustration may not be reproduced in any form without the express written permission of NCCN.

PLEASE NOTE that use of this NCCN Content is governed by the End-User License Agreement, and you MAY NOT distribute this Content or use it with any artificial intelligence model or tool.
Printed by Máximo López Chenlo on 5/4/2026 6:13:37 PM. Copyright © 2026 National Comprehensive Cancer Network, Inc. All Rights Reserved.

(53.9% vs. 73.6% for those with a positive margin); however, in patients resected with negative margins, the margin width had no long-term impact on survival (*P* = .61) or recurrence (*P* > .05) following resection.[112] Farges et al from the AFC-IHCC-2009 study group reported that although R1 resection was the strongest independent predictor of poor outcome in pN0 patients undergoing surgery, its prognostic impact on survival was very low in patients with pN+ intrahepatic CCA (median survival was 18 months and 13 months, respectively, after R0 and R1 resections; *P* = .10).[114] In this study, a margin width >5 mm was an independent predictor of survival among patients with pN0 intrahepatic CCA with R0 resections, which is in contrast to the findings reported by Ribero et al.[112] A retrospective analysis of 535 patients with intrahepatic CCA who underwent resection showed that other factors associated with worse survival post-resection include multifocal disease (hazard ratio [HR], 1.49; 95% CI, 1.19–1.86; *P* = .01), lymph node metastasis (HR, 2.21; 95% CI, 1.67–2.93; *P* < .01), and vascular invasion (HR, 1.39; 95% CI, 1.10–1.75; *P* = .006).[115]

Available evidence (although not conclusive) supports the recommendation that hepatic resection with negative margins should be the goal of surgical therapy for patients with potentially resectable disease.[94] Extensive hepatic resections are often necessary to achieve clear margins since the majority of tumors present as large masses.[112]

Initial surgical exploration should include assessment of multifocal liver disease, lymph node metastases, and distant metastases.[116] Multifocal liver disease, distant (beyond the porta hepatis) nodal metastases, and distant metastases contraindicate surgery as these generally indicate advanced incurable disease. In highly selected situations, resection can be considered. A preoperative biopsy is not always necessary prior to definitive and potentially curative resection. Although limited multifocal liver tumors (including satellite lesions) and gross lymph node metastases to the porta hepatis are considered relative contraindications to surgery, surgical approaches can be considered in selected patients. Minimally invasive approaches by experienced surgeons have been proven to be safe and effective for well-selected cases.[117,118] Patient selection for surgery is facilitated by careful preoperative staging, which may include laparoscopy to identify patients with unresectable or disseminated metastatic disease.[119,120] Staging laparoscopy has been shown to identify peritoneal metastases and liver metastases with a respective yield of 36% and 67% accuracy in patients with potentially resectable intrahepatic CCA and should be considered.[119] A portal lymphadenectomy helps provide accurate staging information.[121] Lymph node metastasis is an important prognostic indicator of survival.[77,112] Therefore, resection and regional lymphadenectomy of the porta hepatis are recommended. It is important to note, however, that there are no data to support a therapeutic benefit of routine lymph node dissection in patients undergoing surgery.[122-125] Ablation may be considered in the rare patients with small single tumors <3 cm.

One study determined that neoadjuvant chemotherapy was associated with higher OS (HR, 0.16; *P* = .01) but did not impact RFS (HR, 0.54; *P* = .27) in patients undergoing hepatic resection.[126] Another study found no difference in survival both in an unadjusted analysis (*P* = .51) and in a propensity score-matched analysis (HR, 0.78; *P* = .16).[127] However, the data suggest that patients with stage II–III intrahepatic CCA may have a survival benefit from neoadjuvant therapy (unadjusted analysis, *P* = .10; propensity-score matched analysis HR, .58; *P* = .02). The optimal adjuvant treatment strategy for patients with resected intrahepatic CCA has not been determined and there are limited clinical trial data to support a standard regimen for adjuvant treatment. Lymphovascular and perineural invasion, lymph node metastasis, and tumor size ≥5 cm have been reported as independent predictors of recurrence and reduced OS following resection.[128,129] Since recurrence following resection is common, these tumor-specific risk factors could be considered as criteria for selection of

Discussion update in progress

Version 1.2026 © 2026 National Comprehensive Cancer Network© (NCCN©), All rights reserved. NCCN Guidelines® and this illustration may not be reproduced in any form without the express written permission of NCCN.

PLEASE NOTE that use of this NCCN Content is governed by the End-User License Agreement, and you MAY NOT distribute this Content or use it with any artificial intelligence model or tool.
Printed by Máximo López Chenlo on 5/4/2026 6:13:37 PM. Copyright © 2026 National Comprehensive Cancer Network, Inc. All Rights Reserved.

patients for adjuvant treatment in clinical trials. See *Adjuvant Chemotherapy and Chemoradiation for Biliary Tract Cancers* in this Discussion.

There are clinical trials investigating whether liver transplantation would be beneficial for patients with intrahepatic CCA (NCT04195503). Very highly selected candidates may meet the criteria for referral. However, these trials are only available at a small subset of centers. The results of a retrospective study showed that patients with very early intrahepatic CCA, defined as single tumors ≤2 cm, had a 5-year cumulative risk of recurrence of 18%, compared to 61% in patients with advanced intrahepatic CCA, defined as a single tumor >2 cm or with the presence of multifocal disease.[130] The 5-year actuarial survival rates were 65% in the former group compared to 45% in the advanced intrahepatic CCA cohort. In another study, researchers found that patients with intrahepatic CCA who underwent liver transplantation had an improved prognosis compared to those who underwent resection in unmatched (HR, 0.65; $P = .002$) and matched (HR, 0.62; $P = .009$) cohorts.[131] In a prospective case-series, out of 6 patients who underwent transplantation for intrahepatic CCA, 50% had RFS at 5 years.[132] OS was 83.3% at 5 years.

Primary treatment options for patients with unresectable or metastatic disease include: systemic therapy; clinical trial; or consideration of locoregional therapy (arterially directed therapies or RT); or best supportive care. In addition, the combination of chemotherapy and chemoradiation, chemoradiation alone, and consideration of referral to a transplant center are included as options for patients with unresectable disease. Systemic therapy or enrollment in a clinical trial are preferred options for patients with metastatic intrahepatic CCA. See sections on *Chemotherapy* and *Chemoradiation and Radiation Therapy* for *Treatment for Advanced Biliary Tract Cancers* in this Discussion. Following primary treatment, except for those receiving best supportive care, the disease should be assessed for response. Resection or locoregional therapy should be reconsidered. Subsequent-line systemic therapy is an option if there is progression on or after systemic therapy. Evaluation for liver transplantation should also be considered as patients who meet the following criteria will be eligible for transplant exception points: biopsy-proven intrahepatic CCA or mixed HCC-intrahepatic CCA, presence of cirrhosis, unresectable, received locoregional or systemic therapy, and 6 months from time of diagnosis or last treatment with no new lesions or extrahepatic disease.[133]

Locoregional Therapy

Locoregional therapy may be considered in patients who are not candidates for surgical curative therapies or to downstage for other treatments.[134] Locoregional therapies such as radiofrequency ablation,[135,136] transarterial chemoembolization (TACE),[137-139] TACE with drug-eluting beads (DEB-TACE), or TACE drug-eluting microspheres,[138,140,141] and radioembolization (TARE) with Y90 microspheres[139,142-147] have been shown to be safe and effective in a small retrospective series of patients with unresectable intrahepatic CCAs. For recurrent or primary small single tumors <3 cm, thermal ablation is a reasonable alternative to surgical resection, particularly in patients with high-risk disease.[148-150] Ablation options include radiofrequency ablation, microwave ablation, and irreversible electroporation. Hepatic tumors may be amenable to arterially directed therapies provided the supply to the tumor may be isolated without excessive non-target treatment. Arterially directed therapies may be considered for select patients with limited extrahepatic disease (hilar lymph node ≤3 cm or ≤ 5 lung nodules ≤1 cm each). These therapies may be used alone or followed by systemic chemotherapy with the intention to prolong survival or downstage to curative resection.[151,152]

The results of two independent prospective studies showed that the efficacy of TACE with irinotecan DEB was similar to that of gemcitabine and oxaliplatin (GEMOX), but was superior to that of TACE with mitomycin

Discussion update in progress

Version 1.2026 © 2026 National Comprehensive Cancer Network© (NCCN©), All rights reserved. NCCN Guidelines® and this illustration may not be reproduced in any form without the express written permission of NCCN.

PLEASE NOTE that use of this NCCN Content is governed by the End-User License Agreement, and you MAY NOT distribute this Content or use it with any artificial intelligence model or tool.
Printed by Máximo López Chenlo on 5/4/2026 6:13:37 PM. Copyright © 2026 National Comprehensive Cancer Network, Inc. All Rights Reserved.

in terms of progression-free survival (PFS) and OS for patients with unresectable intrahepatic CCA.[138] In a systematic review of 12 studies with 298 patients, the effects of radioembolization with Y90 microspheres in unresectable intrahepatic CCA were assessed.[153] The overall weighted median survival for this treatment was 15.5 months, partial tumor response was seen for 28% of patients, and stable disease (SD) was seen for 54% of patients. Another systematic review and meta-analysis of 21 studies with 921 patients reported an overall disease control rate of 82.3% in patients with unresectable intrahepatic CCA treated with radioembolization with Y90.[154] The median OS and PFS were 12.7 months and 7.8 months, respectively. Other smaller series have also reported favorable response rates and survival benefit for patients with unresectable intrahepatic CCA treated with TARE with Y90 microspheres.[142,145,147] Due to the rarity of this disease, none of these locoregional approaches has been evaluated in randomized controlled trials (RCTs). Personalized dosimetry/radiation segmentectomy to achieve delivery of >205 Gy to the tumor may improve outcomes in patients treated with Y90.[155] Y90 is relatively contraindicated in patients with bilirubin >3 mg/dL. In well-selected patients, grade 3–4 hepatic toxicity occurs in <10% of patients, although this may be significantly higher in patients with cirrhosis.[156] In the phase II MISPHEC trial, investigators determined that the combination of radioembolization with Y90 microspheres with chemotherapy (cisplatin and gemcitabine) as a first-line treatment option in 41 patients with unresectable intrahepatic CCA resulted in a 39% response rate, by RECIST criteria.[151] The median PFS and OS were 14 months and 22 months, respectively. Additionally, 22% of patients were downstaged to surgery.

Consideration of RT is a locoregional treatment option for unresectable intrahepatic CCA.[157] A single-institution study including 79 patients with unresectable intrahepatic CCA showed that higher doses of RT (3D conformal RT [3D-CRT] with photons or protons) were associated with better 3-year OS (73% vs. 38%, respectively; $P = .017$) and 3-year local control (78% vs. 45%, respectively; $P = .04$), compared with lower doses of RT.[158] A study using data from the National Cancer database determined that patients treated with ablative RT had improved survival outcomes (23.7 vs. 12.8 months; $P < .001$) compared to those treated with conventional RT (23.7 vs. 12.8 months).[159] Stereotactic body RT (SBRT) may also be used for patients with unresectable intrahepatic CCA.[160] A non-randomized multi-institutional trial including 39 patients with unresectable intrahepatic CCA showed that hypofractionated proton therapy resulted in a 2-year OS rate of 46.5% (median OS, 22.5 months) and a 2-year PFS rate of 25.7%.[161] Another multi-institutional trial reported a local control rate of 90.9% and an OS rate of 81.8% at 1 year for patients with intrahepatic CCA treated with hypofractionated proton beam therapy.[162]

RT dosing depends on the ability to meet normal organ constraints and underlying liver function.[163] All tumors irrespective of the tumor location may be amenable to RT using 3D-CRT and intensity-modulated RT.[164,165] The Panel strongly recommends image-guided RT when using RT, intensity-modulated radiation therapy (IMRT), and SBRT to improve treatment accuracy and reduce treatment-related toxicity. Dosing schedules may depend on margin positivity and may include up to 45 Gy at 1.8 Gy/fraction or 50 to 60 Gy at 1.8 to 2.0 Gy/fraction (to allow for an integrated boost) to the tumor bed.[166,167] RT dosing[163] is dependent on the ability to meet normal organ constraints and underlying liver function. If SBRT or hypofractionation are not options, conventional fractionation with doses ranging from 60 Gy per 30 fractions to 77 Gy per 35 fractions[168,169] or chemoradiation up to 60 Gy per 30 fractions is recommended.[158] The preferred dosing schedule for SBRT for unresectable disease is 40 to 60 Gy, typically done in 3 to 5 fractions, if dose constraints can be met.[163,170]

Data from prospective studies support the use of hepatic arterial infusion (HAI) chemotherapy in patients with advanced, liver-confined, and unresectable intrahepatic CCA.[171-175] In a phase II trial of HAI of floxuridine

Discussion update in progress

Version 1.2026 © 2026 National Comprehensive Cancer Network© (NCCN©), All rights reserved. NCCN Guidelines® and this illustration may not be reproduced in any form without the express written permission of NCCN.

PLEASE NOTE that use of this NCCN Content is governed by the End-User License Agreement, and you MAY NOT distribute this Content or use it with any artificial intelligence model or tool.
Printed by Máximo López Chenlo on 5/4/2026 6:13:37 PM. Copyright © 2026 National Comprehensive Cancer Network, Inc. All Rights Reserved.

in combination with gemcitabine and oxaliplatin in 38 patients with unresectable intrahepatic CCA, 58% of patients had an objective radiographic response and 84% of patients had disease control.[176] The median OS and median PFS were 25.5 months and 11.8 months respectively. A prospective single arm phase II trial investigated the use of gemcitabine and cisplatin along with HAI of floxuridine in 50 patients with advanced intrahepatic CCA confined to the liver.[177] At a median follow-up of 26.4 months, the median OS was 22.1 months, the median PFS was 10 months. The 1-year and 2-year OS rates were 80% and 28.6%, respectively. In a meta-analysis including 20 studies (*N* = 657), HAI was compared to TACE, DEB-TACE, and TARE with Y90 microspheres.[178] OS and tumor response were greatest for HAI, with a median tumor response rate of 57%, although grade III/IV toxicity was also highest, relative to the other arterially directed therapies. A retrospective analysis of 525 patients with intrahepatic CCA showed that patients who received a combined regimen of HAI and another chemotherapy agent (gemcitabine, irinotecan, or 5-FU) had greater OS, relative to patients receiving chemotherapy without HAI (30.8 vs. 18.4 months; $P < .001$).[179] In a retrospective analysis comparing HAI chemotherapy with modified FOLFOX (mFOLFOX; fluorouracil, leucovorin, and oxaliplatin) to first-line systemic therapy in patients with unresectable intrahepatic CCA, the median OS and PFS did not differ.[180] However, the authors note that intrahepatic PFS was improved in those receiving HAI chemotherapy ($P = .035$). Subgroup analysis revealed that HAI chemotherapy was more beneficial for patients with single tumors in terms of OS ($P = .047$) and PFS ($P = .009$).

Based on the available evidence as discussed above, the Panel has included locoregional therapy as a treatment option that may be considered for patients with unresectable disease or metastatic cancer without extrahepatic disease. HAI chemotherapy, with or without systemic chemotherapy, may be used in the context of a clinical trial or at experienced centers in carefully selected cases for patients with advanced disease confined to the liver.

Management of Mixed HCC-CCA

An estimated 1% to 10% of patients with primary liver tumors are found to have a combination of both HCC and CCA histologies on pathologic review.[181-184] Tumor molecular profiling should be considered in all patients with advanced stages of disease to identify potential targeted aberrations, which may be associated with CCA.[185] Liver resection is considered the standard treatment for resectable disease. Though prospective data are lacking, liver-directed local therapies may be appropriate for patients with a limited extent of unresectable hepatic disease. Patients with HCC-CCA that is limited in size based on center-specific criteria used should be considered for evaluation in a transplant center. In patients with metastatic or locally-advanced recurrence after a prior resection or local therapies, a repeat biopsy should be considered to ascertain the dominant histology at recurrence. If biopsy results at recurrence suggests an isolated recurrence of either the HCC or CCA component, the Panel considers a systemic therapy option appropriate for that histologic component. There are limited prospective data to guide treatment decisions for advanced disease.

A retrospective study of patients with mixed HCC-CCA treated with palliative systemic therapy demonstrated similar overall response rates (ORRs) with chemotherapy versus non-chemotherapy-based systemic therapies.[186] There was a trend towards longer median OS in patients treated with chemotherapy (15.5 vs. 5.3 months; $P = .052$). Based upon this study and the potential for activity of component parts in both histologies, gemcitabine plus cisplatin combined with either durvalumab or pembrolizumab is an appropriate choice for first-line therapy. The Panel notes that these combinations include agents with anti-tumor activity in both CCA[187-189] and HCC histologies.[190-193] Upon disease progression, molecularly-targeted therapies should be considered if the tumor harbors a

Discussion update in progress

Version 1.2026 © 2026 National Comprehensive Cancer Network© (NCCN©), All rights reserved. NCCN Guidelines® and this illustration may not be reproduced in any form without the express written permission of NCCN.

PLEASE NOTE that use of this NCCN Content is governed by the End-User License Agreement, and you MAY NOT distribute this Content or use it with any artificial intelligence model or tool.
Printed by Máximo López Chenlo on 5/4/2026 6:13:37 PM. Copyright © 2026 National Comprehensive Cancer Network, Inc. All Rights Reserved.

targetable aberration. In the absence of a targetable aberration, regimens with demonstrated activity in both HCC and CCA are reasonable options, including nivolumab plus ipilimumab[194,195] or regorafenib.[196,197]

Management of Extrahepatic Cholangiocarcinoma

Complete resection with negative margins is the only potentially curative treatment for patients with resectable disease. The reported 5-year survival rates following complete resection are in the range of 20% to 42% and 16% to 52%, respectively, for patients with hilar and distal CCAs.[198,199]

Surgical margin status and lymph node metastases are independent predictors of survival following resection.[111,200,201] Regional lymphadenectomy of the porta hepatis (hilar CCA) or in the area of the head of the pancreas (distal CCA) are considered standard parts of curative resections.[202,203] Since these surgical procedures are associated with postoperative morbidity, they should be carried out in patients who are medically fit for a major operation. Surgery is contraindicated in patients with distant metastatic disease to the liver, peritoneum, or distant lymph nodes beyond the porta hepatis (or head of the pancreas for distal tumors).

The type of surgical procedure for a resectable tumor is based on its anatomic location in the biliary tract. Resection of the involved biliary tract and en bloc liver resection (typically a major hepatectomy involving the right or left liver with the caudate lobe) is recommended for hilar tumors. Bile duct excision with frozen section assessment of proximal and distal bile duct margins. Pancreaticoduodenectomy can be attempted for mid bile duct tumors not involving the liver or pancreas. However, mid bile duct tumors that can be completely resected with an isolated bile duct resection are uncommon. A combined pancreaticoduodenectomy and hepatic resection is required, in rare instances, for a bile duct tumor with extensive biliary tract involvement. This operation, however, is associated with high morbidity and should only be considered in well-selected cases.[204,205]

Combined hepatic and pancreatic resections to clear distant nodal disease (as opposed to biliary extent) are not recommended, as these are highly morbid procedures with no obvious associated survival advantage. The guidelines recommend consideration of biliary drainage prior to definitive resection for patients with jaundice prior to instituting systemic therapy. However, caution should be exercised in patients with hilar biliary obstruction as drainage is not always simple and can be associated with significant morbidity.[206] Decisions about whether preoperative biliary drainage is appropriate (and the type of drainage) should be made by a multidisciplinary team at an experienced high-volume center.

In patients with hilar CCA, extended hepatic resection (to encompass the biliary confluence) (usually with caudate lobectomy) is recommended, since hilar tumors, by definition, abut or invade the central portion of the liver. The recommendation for extended liver resection is supported by retrospective analyses showing a higher rate of R0 resection, prolonged survival, and decreased hepatic recurrence associated with extended hepatic resections as compared to bile duct resections.[207-211] Resection and reconstruction of the portal vein and/or hepatic artery may be necessary for complete resection, especially in patients with more advanced disease. This approach requires substantial experience and appropriate surgical support for such technical operations.[212,213] For adjuvant treatment of resected hilar CCA, see the section on *Adjuvant Chemotherapy and Chemoradiation for Biliary Tract Cancers*.

Patient selection for surgery is facilitated by careful preoperative staging, surgical exploration, biopsy, and consideration of diagnostic laparoscopy to identify patients with unresectable or distant metastatic disease. A preoperative biopsy is not necessary if the index of suspicion is high. Laparoscopy can identify the majority of patients with occult metastatic hilar CCA, albeit with a lower yield. A review including six studies of staging laparoscopy in patients with hilar CCA showed a yield of 14% to 45% and

Discussion update in progress

Version 1.2026 © 2026 National Comprehensive Cancer Network© (NCCN©), All rights reserved. NCCN Guidelines® and this illustration may not be reproduced in any form without the express written permission of NCCN.

PLEASE NOTE that use of this NCCN Content is governed by the End-User License Agreement, and you MAY NOT distribute this Content or use it with any artificial intelligence model or tool.
Printed by Máximo López Chenlo on 5/4/2026 6:13:37 PM. Copyright © 2026 National Comprehensive Cancer Network, Inc. All Rights Reserved.

an accuracy of 32% to 71%.[214] The decreasing yield of staging laparoscopy over time may be due to improvements in imaging techniques.[215]

While not routinely used in all patients undergoing resection, the consensus of the Panel is that in patients with hilar CCA, preoperative treatments including biliary drainage targeted to the future liver remnant (FLR) (using ERCP or PTC)[216-219] and contralateral portal vein embolization[220,221] should be considered for patients with low FLR volumes. Patients with unresectable or metastatic disease should be considered for biliary drainage using either surgical bypass (although rarely used) or ERCP or PTC, most often involving biliary stent placement.[222-225]

In patients with unresectable or metastatic disease, biopsy is recommended to confirm the diagnosis prior to the initiation of further treatment. For patients with unresectable disease, biopsy is recommended only after determining transplant status as transperitoneal and surgical biopsy may be contraindicated in transplant candidates. Molecular testing is recommended to potentially guide targeted treatment. Primary treatment options for these patients include: systemic therapy, clinical trial, or best supportive care. In addition, combination of chemotherapy and chemoradiation, chemoradiation, and palliative RT are also included as options for patients with unresectable disease. Data to support particular chemoradiation and chemotherapy regimens are limited. See sections on *Chemotherapy* and *Chemoradiation and Radiation Therapy* for *Treatment of Advanced Biliary Tract Cancers*. Following primary treatment, except for those receiving best supportive care, the disease should be assessed for response. Resection or locoregional therapy should be reconsidered. Subsequent-line systemic therapy is an option if there is progression on or after systemic therapy.

Liver transplantation is a potentially curative option for selected patients with lymph node-negative, non-disseminated, locally advanced hilar CCAs.[226-229] There is retrospective evidence suggesting that neoadjuvant chemoradiation followed by liver transplantation is effective for selected patients with hilar CCA; particularly in patients with primary sclerosing cholangitis.[230-232] Results from two studies suggest that the combination of liver transplantation and neoadjuvant and/or adjuvant chemoradiation is associated with higher RFS than a potentially curative resection.[233,234] However, in one of these studies, there were substantial differences in the characteristics of patients in the two treatment groups.[233] It is important to note that many of these reports include patients with primary sclerosing cholangitis, and some have not had a definitive histologic cancer diagnosis. Liver transplantation should be considered only for highly selected patients (ie, tumor ≤3 cm in radial diameter, no intrahepatic or extrahepatic metastases, no nodal disease) with either unresectable disease with otherwise normal biliary and hepatic function or underlying chronic liver disease precluding surgery. The Panel encourages continuation of clinical research in this area, and referral of patients with unresectable disease to a transplant center with a United Network for Organ Sharing-approved protocol for transplant of CCA should be considered.

Photodynamic therapy (PDT) is an ablative therapy that involves intravenous injection of a photosensitizing drug followed by selective irradiation with light of a specific wavelength to initiate localized drug activation, and has been used for palliation in patients with extrahepatic CCA. The combination of PDT with biliary stenting was reported to be associated with prolonged OS in patients with unresectable CCA in two small RCTs.[235,236]

Surveillance

There are no data to support a specific surveillance schedule or tests in patients undergoing resection of CCA; determination of appropriate follow-up schedule/imaging should include a careful patient/physician discussion. It is recommended that follow-up of patients undergoing resection of CCA should include consideration of imaging studies every 3

Discussion update in progress

Version 1.2026 © 2026 National Comprehensive Cancer Network© (NCCN©), All rights reserved. NCCN Guidelines® and this illustration may not be reproduced in any form without the express written permission of NCCN.

PLEASE NOTE that use of this NCCN Content is governed by the End-User License Agreement, and you MAY NOT distribute this Content or use it with any artificial intelligence model or tool.
Printed by Máximo López Chenlo on 5/4/2026 6:13:37 PM. Copyright © 2026 National Comprehensive Cancer Network, Inc. All Rights Reserved.

to 6 months for 2 years, then every 6 to 12 months for up to 5 years, or as clinically indicated. Re-evaluation according to the initial workup should be considered in the event of disease progression. One study reported a cumulative recurrence rate of 44%, 65%, and 70% at 1, 3, and 5 years, respectively, post resection for patients with intrahepatic CCA.[237] Another study reported that among patients with intrahepatic CCA with disease recurrence, almost all instances of recurrence were observed within 5 years; the highest risk was within 2 years of resection.[238] In a sample of 80 patients with extrahepatic CCA who underwent resection, 48.8% died of disease by 28 months, while 11.3% died of other causes.[83]

Adjuvant Chemotherapy and Chemoradiation for Biliary Tract Cancers

Recurrence following surgery is a primary limitation for cure in patients with BTCs and provides an important justification for the use of adjuvant therapy, which is recommended for up to 6 months. The role of adjuvant chemotherapy or chemoradiation therapy in patients with resected BTCs is poorly defined, with a lack of data from multiple phase III randomized controlled trials.[166,239] Due to the low incidence of BTCs, the efficacy and safety of adjuvant chemotherapy or chemoradiation therapy in these patients have been primarily evaluated in retrospective studies that have included only a small number of patients. Further, these studies often combined patients with gallbladder and bile duct cancers (with a few exceptions), which may be problematic since the biology of these tumors is completely different. Despite the challenges associated with the accrual of large numbers of patients with BTC for randomized phase III trials, it is widely recognized that efforts should be made to conduct such studies in which the individual disease entities are evaluated separately.

Data supporting adjuvant chemotherapy in patients with resected BTC have come from two randomized phase III trials. In the phase III BILCAP study, 447 patients with R0/R1 resected CCA or gallbladder cancer were randomized to receive either adjuvant capecitabine or observation.[240] RFS was significantly greater for patients in the capecitabine arm in both the intent-to-treat analysis (24.4 vs. 17.5 months; HR, 0.75; 95% CI, 0.58–0.98; $P = .033$) and in the per-protocol analysis ($N = 430$; HR, 0.70; 95% CI, 0.54–0.92; $P = .009$). The primary endpoint of median OS was 51.1 months for the capecitabine arm and 36.4 months for the observation arm. This difference was statistically significant in the per-protocol analysis (HR, 0.75; 95% CI, 0.58–0.97; $P = .028$) but not in the primary intent-to-treat analysis. Data from a long-term analysis in the intent-to-treat population determined a median OS of 49.6 months for the capecitabine arm and 36.1 months for the observation arm (adjusted HR, 0.84; 95% CI, 0.67–1.06).[241] A hazard ratio of 0.74 (95% CI, 0.59–0.94) was reported in the protocol-specified sensitivity analysis. In the STAMP randomized study from South Korea, adjuvant gemcitabine and capecitabine did not improve disease-free survival at 2 years and median OS, when compared to capecitabine, in patients with lymph node-positive extrahepatic CCA following resection.[242]

In a phase III randomized trial reported in 2002, 508 patients with resected pancreaticobiliary cancer (139 patients had CCA and 140 patients had gallbladder cancer) were randomly assigned to adjuvant chemotherapy with fluorouracil and mitomycin C or to a control arm.[243] Results from unplanned subgroup analyses showed a significantly better 5-year disease-free survival for patients with gallbladder cancer treated with chemotherapy (20.3% compared to 11.6% in the control group; $P = .021$), although no significant differences between the two treatment arms were observed for all patients with biliary tract cancers. Results from this trial suggested that patients with gallbladder cancer undergoing resection may derive survival benefit with adjuvant chemotherapy but the gallbladder cohort on the BILCAP trial did not see a similar benefit on exploratory analysis.[241,243]

Discussion update in progress

Version 1.2026 © 2026 National Comprehensive Cancer Network© (NCCN©), All rights reserved. NCCN Guidelines® and this illustration may not be reproduced in any form without the express written permission of NCCN.

PLEASE NOTE that use of this NCCN Content is governed by the End-User License Agreement, and you MAY NOT distribute this Content or use it with any artificial intelligence model or tool.
Printed by Máximo López Chenlo on 5/4/2026 6:13:37 PM. Copyright © 2026 National Comprehensive Cancer Network, Inc. All Rights Reserved.

A randomized phase III trial from Japan investigated whether S-1, an oral fluoropyrimidine derivative given as adjuvant therapy, benefited patients with BTCs who underwent R0/R1 resection.[244] Compared to patients treated with surgery alone, patients treated with adjuvant S-1 had a significantly improved 3-year OS (adjusted HR, 0.69; 95% CI, 0.51–0.94; *P* = .008). However, the 3-year RFS rate was not significantly higher (HR, 0.80; 95% CI, 0.61–1.04; *P* = .088). Furthermore, S-1 is not available in the United States.

Negative results were reported from gemcitabine-based regimens in two randomized phase III trials. In the phase III PRODIGE 12-ACCORD 18 trial, 196 patients with R0/R1 resected BTC were randomized to receive GEMOX or surveillance alone.[245] No statistically significant differences were found between the study arms for RFS and OS. In another phase III trial from Japan, adjuvant gemcitabine monotherapy (compared to observation) in 226 patients with resected extrahepatic CCA reported no difference in survival.[246]

Retrospective studies that have combined patients with gallbladder cancer and CCAs provide conflicting evidence regarding the role of adjuvant therapy.[247-249] It should be noted that the majority of recurrences after resection of gallbladder cancer involve distant sites, supporting the idea of developing effective adjuvant systemic therapies.[247]

In a systematic review and meta-analysis of 6712 patients with BTCs, Horgan et al reported an associated improvement in OS (although nonsignificant) with adjuvant therapy compared with surgery alone, with no difference between patients with gallbladder cancer and bile duct cancers.[250] Chemotherapy or chemoradiation therapy was associated with statistically greater benefit than RT alone, with the greatest benefit observed in patients with lymph node-positive disease and macroscopic residual disease (R1 resection). Another systematic review and meta-analysis of 42,917 patients found a significantly higher OS with adjuvant therapy after surgery compared with surgery alone.[251] Ren et al reported a higher 5-year OS with adjuvant RT compared to surgery only in patients with gallbladder cancer or extrahepatic CCA in a meta-analysis of 21 clinical trials.[252]

In studies that included only patients with gallbladder cancer, a meta-analysis of 10 retrospective studies with 3191 patients showed that adjuvant chemotherapy was associated with improved OS, compared to resection alone (HR, 0.42; 95% CI, 0.22–0.80).[253] Subgroup analyses showed that the patients who are most likely to benefit from adjuvant therapy include those with a positive margin, nodal disease, or at least stage II disease. Retrospective studies have concluded that adjuvant chemotherapy or chemoradiation following R0 resection might improve OS in selected patients with T2 or T3 tumors and lymph node-positive gallbladder cancer.[254-257]

Retrospective studies that included only patients with resected extrahepatic CCA suggest that adjuvant chemoradiation may improve local control and survival, although distant metastases was the most common pattern of recurrence.[258-261] Other studies have suggested that adjuvant chemoradiation may have a significant survival benefit only in a subgroup of patients with T3 or T4 tumors or those with a high risk of locoregional recurrence (R1 resection or positive lymph nodes).[260,262,263]

Most of the collective experience of chemoradiation in BTCs involves concurrent chemoradiation and fluorouracil. The phase II SWOG S0809 trial, which enrolled patients with extrahepatic CCA or gallbladder cancer (*N* = 79), provided prospective data on adjuvant chemotherapy/chemoradiation (ie, capecitabine/gemcitabine followed by concurrent capecitabine and RT).[164] Two-year OS was 65%, and median survival was 35 months. A majority of patients enrolled in the trial (86%) completed therapy, and the regimen was generally tolerable. The results from a large national database also support the use of adjuvant

Discussion update in progress

Version 1.2026 © 2026 National Comprehensive Cancer Network© (NCCN©), All rights reserved. NCCN Guidelines® and this illustration may not be reproduced in any form without the express written permission of NCCN.

PLEASE NOTE that use of this NCCN Content is governed by the End-User License Agreement, and you MAY NOT distribute this Content or use it with any artificial intelligence model or tool.
Printed by Máximo López Chenlo on 5/4/2026 6:13:37 PM. Copyright © 2026 National Comprehensive Cancer Network, Inc. All Rights Reserved.

chemoradiation (HR, 0.86; *P* = .004) over adjuvant chemotherapy only.[264] Confirmatory phase III trial data are needed. Concurrent chemoradiation with capecitabine has been used in other studies.[260,265] Concurrent chemoradiation with gemcitabine is not recommended due to the limited experience and toxicity associated with this treatment.[266]

Among patients with cancer of the gallbladder or extrahepatic bile duct, those who have undergone an R0 resection and who have negative regional nodes or those with carcinoma in situ at margin may be followed with systemic therapy (preferred), clinical trial (preferred), observation alone, or chemoradiation (category 2B for patients with gallbladder cancer). Patients with intrahepatic CCA who have undergone an R0 resection may be followed with systemic therapy (preferred), clinical trial (preferred), or observation.

Patients with gallbladder cancer or extrahepatic CCA with resected, positive margins (R1) or gross residual disease (R2) or those with intrahepatic CCA with gross residual disease (R2) after resection should be evaluated by a multidisciplinary team to review the available treatment options on a case-by-case basis. Evaluation and treatment of gross residual disease (R2) should be consistent with evaluation and treatment for unresectable disease. For patients with R1 margins or positive regional nodes, the optimal treatment strategy has not been established but options are systemic therapy (preferred), clinical trial (preferred), combination of chemotherapy and chemoradiation, or chemoradiation.

There are limited data to support a specific chemoradiation regimen or definitive benefit. If RT is used, then RT using 3D conformal RT and intensity-modulated RT are options.[164,165] Dosing schedules may depend on margin positivity and may include up to 45 Gy at 1.8 Gy/fraction or 50 to 60 Gy at 1.8 to 2.0 Gy/fraction (to allow for an integrated boost) to the tumor bed.[166,167] RT dosing[163] is dependent on the ability to meet normal organ constraints and underlying liver function. If SBRT or hypofractionation are not options, conventional fractionation with doses ranging from 60 Gy per 30 fractions to 77 Gy per 35 fractions[168,169] or chemoradiation up to 60 Gy per 30 fractions is recommended.[158] The preferred dosing schedule for SBRT for unresectable disease is 40 to 60 Gy, typically done in 3 to 5 fractions, if dose constraints can be met.[163,170]

Recommended adjuvant chemotherapy regimens include capecitabine monotherapy (category 1); gemcitabine monotherapy or combined with cisplatin or capecitabine; and 5-fluoououracil monotherapy. Capecitabine monotherapy is preferred while all other options are included as other recommended regimens. If a patient is ineligible for cisplatin, carboplatin may be used.[267] Besides capecitabine monotherapy, whose use in this setting is supported by the pre-specified secondary endpoint of the phase III BILCAP study,[240] data to support particular chemotherapy regimens for adjuvant treatment of resected BTC are limited and are based on the extrapolation of data from studies of patients with advanced disease. Additionally, some of the recommendations are based on practice patterns at NCCN Member Institutions and retrospective studies from single-center experiences. The recommendations in the NCCN Guidelines on the use of adjuvant chemotherapy are not specific to the particular type of BTC, due to the limited data and the heterogeneity of patient populations included in many of the published studies.

Treatment for Advanced Biliary Tract Cancers

The prognosis of patients with advanced BTCs is poor and the median survival for those undergoing supportive care alone is short.[268] Treatment options for advanced BTCs may include systemic therapy, enrollment in a clinical trial, combination of chemotherapy and chemoradiation, chemoradiation, palliative RT, consideration of locoregional therapy (arterially directed therapies or RT), consideration of referral to a transplant center, and best supportive care, depending on the disease stage and specific disease subtype. Following primary treatment, except for those

Discussion update in progress

Version 1.2026 © 2026 National Comprehensive Cancer Network© (NCCN©), All rights reserved. NCCN Guidelines® and this illustration may not be reproduced in any form without the express written permission of NCCN.

PLEASE NOTE that use of this NCCN Content is governed by the End-User License Agreement, and you MAY NOT distribute this Content or use it with any artificial intelligence model or tool.
Printed by Máximo López Chenlo on 5/4/2026 6:13:37 PM. Copyright © 2026 National Comprehensive Cancer Network, Inc. All Rights Reserved.

receiving best supportive care, the disease should be assessed for response. Resection or locoregional therapy should be reconsidered. Subsequent-line systemic therapy is an option if there is progression on or after systemic therapy. Selection of subsequent-line systemic therapy for progressive disease depends on clinical factors including previous treatment regimen/agent, somatic molecular testing results, and extent of liver dysfunction. A U.S. Food and Drug Administration (FDA)-approved biosimilar is an appropriate substitute for any recommended systemic biologic therapy in the NCCN Guidelines.

Immunotherapy Plus Chemotherapy

The phase III TOPAZ-1 trial, which randomized 685 patients with unresectable or metastatic BTC with no prior systemic treatment 1:1, demonstrated that treatment with durvalumab in combination with gemcitabine plus cisplatin significantly improved the primary endpoint of OS (HR, 0.80; 95% CI, 0.66–0.97; *P* = .021) along with the secondary endpoint of PFS (HR, 0.75; 95% CI, 0.63–0.89; *P* = .001) compared to placebo in combination with gemcitabine plus cisplatin.[188] The overall response rate (ORR) was 26.7% and 18.7%, respectively. Following an updated analysis, the authors report an updated median OS of 12.9 months for patients treated with durvalumab in combination with gemcitabine and cisplatin, compared to 11.3 months for those treated with placebo in combination with gemcitabine and cisplatin (HR, 0.76; 95% CI, 0.64–0.91).[269] Decreased neutrophil count (treatment group, 21%; control group, 25%), anemia (19% in both groups), and neutropenia (treatment group, 19%; control group, 20%) were the most frequent grade 3 or 4 treatment-related adverse events.

The phase III randomized KEYNOTE-966 trial investigated the combination of pembrolizumab with gemcitabine and cisplatin compared to the combination of placebo with gemcitabine and cisplatin in 1069 patients with unresectable, locally advanced, or metastatic BTC with no prior treatment.[187] In the intention-to-treat population, there was a significant improvement in the primary endpoint of OS, with a median OS of 12.7 months in the treatment group and a median OS of 10.9 months in the control group (HR, 0.83; 95% CI, 0.72–0.95; *P* = .0034). At the first interim analysis, treatment with pembrolizumab/gemcitabine/cisplatin did not result in a statistically significant benefit in PFS (HR, 0.86; 95% CI, 0.75–1.00; *P* = .023). Similar results were obtained in the final analysis for PFS. Both groups had an ORR of 29% at the first interim analysis. 70% of patients treated with pembrolizumab in combination with gemcitabine and cisplatin experienced a grade 3 or 4 treatment-related adverse event compared to 69% of patients treated with placebo in combination with gemcitabine and cisplatin.

Based on these data, the Panel has included combination therapy with durvalumab plus gemcitabine plus cisplatin, as well as combination therapy with pembrolizumab plus gemcitabine plus cisplatin, as category 1 preferred recommendations for the first-line systemic treatment of unresectable or metastatic BTCs. Durvalumab in combination with gemcitabine and cisplatin is also a recommended treatment option for patients who developed recurrent disease >6 months after surgery with curative intent and >6 months after completion of adjuvant therapy. These combinations are also recommended as subsequent-line systemic therapy options (other recommended regimens) for progressive disease in patients who have not been previously treated with a checkpoint inhibitor. If a patient is ineligible for cisplatin, carboplatin may be used.[267]

Chemotherapy Alone

The survival benefit of chemotherapy (fluorouracil, leucovorin, and etoposide) over best supportive care for patients with advanced BTCs was initially suggested in a phase III trial of 90 patients with advanced pancreatic and BTCs, 37 of whom had advanced BTCs.[270] In a single-center randomized study of 81 patients with unresectable gallbladder

Discussion update in progress

Version 1.2026 © 2026 National Comprehensive Cancer Network© (NCCN©), All rights reserved. NCCN Guidelines® and this illustration may not be reproduced in any form without the express written permission of NCCN.

PLEASE NOTE that use of this NCCN Content is governed by the End-User License Agreement, and you MAY NOT distribute this Content or use it with any artificial intelligence model or tool.
Printed by Máximo López Chenlo on 5/4/2026 6:13:37 PM. Copyright © 2026 National Comprehensive Cancer Network, Inc. All Rights Reserved.

cancer, Sharma et al reported that modified GEMOX improved PFS and OS compared to best supportive care or fluorouracil.[271] Median OS was 4.5, 4.6, and 9.5 months, respectively, for the best supportive care, fluorouracil, and modified GEMOX arms (P = .039). The corresponding PFS was 2.8, 3.5, and 8.5 months (P < .001).

Several phase II studies have also demonstrated the efficacy of chemotherapy for the treatment of patients with advanced BTCs.[272,273] The results of a pooled analysis of 104 trials that have included 2810 patients with advanced BTCs showed that response rates and tumor control were higher for the subgroup of patients receiving a combination of gemcitabine and platinum-based agents.[274] In a retrospective study of 304 patients with unresectable BTCs who were treated with gemcitabine alone, a cisplatin-based regimen, or a fluoropyrimidine-based regimen, patients receiving gemcitabine were shown to have a lower risk of death.[275] Most importantly, the support for the use of gemcitabine-based or fluoropyrimidine-based chemotherapy for patients with advanced BTCs comes from four randomized studies.[189,276-278] A phase II study comparing modified FOLFIRINOX (mFOLFIRINOX; fluorouracil, leucovorin, irinotecan and oxaliplatin) to gemcitabine plus cisplatin in patients with locally advanced or metastatic BTCs did not achieve its primary endpoint of PFS at 6 months in the modified intention-to-treat population.[279]

The randomized, controlled, phase III ABC-02 study, which enrolled 410 patients with locally advanced or metastatic CCA, gallbladder cancer, or ampullary cancer, demonstrated that the combination of gemcitabine and cisplatin improved OS and PFS by 30% over gemcitabine alone.[189] Median OS was 11.7 months and 8.1 months (HR, 0.64; 95% CI, 0.52–0.80; P < .001), and median PFS was 8.0 months versus 5.0 months (HR, 0.63; 95% CI, 0.51–0.77; P < .001), both in favor of the combination arm. Although the rate of neutropenia was higher in the group receiving gemcitabine and cisplatin, there was no significant difference in the rate of neutropenia-associated infections between the two arms. Okusaka et al also reported similar findings in a phase II randomized study of 84 patients with advanced BTCs.[278] If a patient is ineligible for cisplatin, carboplatin may be used. A phase II study with 48 patients with advanced BTCs revealed that 31.1% of evaluable patients treated with gemcitabine plus carboplatin had an overall response, with a median OS and PFS of 10.6 and 7.8 months, respectively.[267]

Results from the randomized phase III ABC-06 study showed that compared to active symptom control alone, active symptom control combined with FOLFOX in patients previously treated with combined cisplatin and gemcitabine improved the primary endpoint of median OS (6.2 vs. 5.3 months; adjusted HR, 0.69; P = .031).[280] FOLFOX is a preferred subsequent-line systemic therapy option for unresectable or metastatic progressive disease. Second-line treatment with fluorouracil and irinotecan (FOLFIRI) also provided some benefits to patients (median PFS, 1.7 months [95% CI, 0.66–2.67 months]; median OS, 5 months [95% CI, 2.77–7.20 months]).[281] A retrospective analysis of patients with advanced BTCs treated with FOLFIRI also demonstrated some efficacy (median OS, 6.6 months [95% CI, 4.7–8.4 months]; median PFS, 2.4 months [95% CI, 1.7–3.1 months]).[282] Patients treated with concurrent bevacizumab or EGFR-targeted therapy had a median PFS of 2.7 months. A randomized phase II trial comparing mFOLFOX (leucovorin, fluorouracil, and oxaliplatin) with mFOLFIRI in patients with locally advanced or metastatic BTCs previously treated with gemcitabine and cisplatin reported similar efficacy between the two regimens.[283] The median OS and PFS were 6.3 months (95% CI, 4.4–8.2 months) and 2.8 months (95% CI, 2.3–3.3 months), respectively, in the mFOLFOX group and 5.7 months (95% CI, 4.7%–6.7%; P =.677) and 2.1 months (95% CI, 1.1–3.1 months; P = .974) in the mFOLFIRI group, respectively. An ORR of 5.9% and 4.0% (P = .663) was achieved in the mFOLFOX and mFOLFIRI groups, respectively, and the disease control rate was 66.7% and 64.0% (P = .778), respectively. FOLFIRI is a

Discussion update in progress

Version 1.2026 © 2026 National Comprehensive Cancer Network© (NCCN©), All rights reserved. NCCN Guidelines® and this illustration may not be reproduced in any form without the express written permission of NCCN.

PLEASE NOTE that use of this NCCN Content is governed by the End-User License Agreement, and you MAY NOT distribute this Content or use it with any artificial intelligence model or tool.
Printed by Máximo López Chenlo on 5/4/2026 6:13:37 PM. Copyright © 2026 National Comprehensive Cancer Network, Inc. All Rights Reserved.

subsequent-line systemic therapy option (other recommended regimen) for unresectable or metastatic progressive disease.

The phase IIb NIFTY trial from South Korea showed that treatment with liposomal irinotecan with fluorouracil and leucovorin in patients with confirmed metastatic BTC with disease progression on gemcitabine and cisplatin significantly improved median PFS (7.1 months; 95% CI, 3.6–8.8 months) compared to treatment with fluorouracil and leucovorin (1.4 months; 95% CI, 1.2–1.5 months; HR, 0.56; 95% CI, 0.39–0.81; *P* = .0019) on a blinded independent central review.[284] In an updated analysis, the median PFS, as assessed by a different blinded independent central review, was 4.2 months for patients treated with the former compared to 1.7 months (HR, 0.61; *P* = .004) for patients treated with fluorouracil and leucovorin.[285] Unfortunately, a similar randomized phase II AIO NALIRICC trial from Europe showed no difference in median overall survival with 6.9 months (95% CI, 5.3–10.6 months) in the liposomal irinotecan plus fluorouracil and leucovorin arm and 8.2 months (5.4–11.9 months) in the fluorouracil plus leucovorin arm (HR, 1.08; 95% CI, 0.68–1.72; *P* = .74].[286] There was also no difference in the primary endpoint of PFS (HR, 0.87; 95% CI, 0.56–1.35; *P* = .52). Liposomal irinotecan plus fluorouracil plus leucovorin is a category 2B subsequent-line systemic therapy option (other recommended regimen) for unresectable or metastatic progressive disease.

Examples of other gemcitabine-based or fluoropyrimidine (fluorouracil or capecitabine)-based regimens with demonstrated activity in phase II trials include: gemcitabine and cisplatin or oxaliplatin[287-295]; gemcitabine and fluoropyrimidine[296-300]; gemcitabine and albumin-bound paclitaxel (for CCA)[301]; gemcitabine and cetuximab[302]; and fluoropyrimidine and oxaliplatin or cisplatin.[303-306] A phase III study showed that the combination of capecitabine and oxaliplatin was noninferior to the GEMOX combination in terms of the 6-month PFS.[307] Triple-drug chemotherapy regimens have also been shown to be effective in patients with advanced BTCs, albeit in a very small number of patients.[308-310] The phase III trial that evaluated fluorouracil, leucovorin, and etoposide versus fluorouracil, cisplatin, and epirubicin did not show one regimen to be significantly superior with respect to OS (12 vs. 9 months, respectively) in patients with advanced BTCs, although the trial was underpowered to detect such a difference.[308] In a phase II trial, the combination of panitumumab, a monoclonal anti-EGFR antibody, with gemcitabine and irinotecan showed encouraging efficacy with good tolerability in patients with advanced CCA, with a 5-month PFS rate of 69%.[311] The median PFS and OS were 9.7 months and 12.9 months, respectively.

The effects of other gemcitabine combination therapies have been examined in phase II trials. In a randomized phase II study of 51 patients, Kornek et al established the efficacy and tolerance of mitomycin in combination with gemcitabine or capecitabine in previously untreated patients with advanced BTCs.[276] Mitomycin and capecitabine were associated with superior complete response (CR) rate (31% vs. 20%), median PFS (5.3 vs. 4.2 months), and OS (9.25 vs. 6.7 months). The results of the 40955 EORTC trial showed that cisplatin and fluorouracil was more active than high-dose fluorouracil in terms of ORRs (19% and 7.1%, respectively) and OS (8 and 5 months, respectively), but the PFS was similar in both treatment arms (3.3 months).[277] In a randomized phase II trial, the combination of gemcitabine and sorafenib was compared to gemcitabine with a placebo in 102 patients with unresectable or metastatic BTC.[312] There were no significant between-group differences for OS and PFS rates, but patients who developed liver metastases following resection survived longer if they received sorafenib, relative to patients who received the placebo (*P* = .019). Data from the randomized phase II NIFE trial showed that in the intention-to-treat population, 51% of patients receiving nanoliposomal irinotecan in combination with fluorouracil and leucovorin achieved PFS at 4 months compared to 59.5% in the gemcitabine and

Discussion update in progress

Version 1.2026 © 2026 National Comprehensive Cancer Network© (NCCN©), All rights reserved. NCCN Guidelines® and this illustration may not be reproduced in any form without the express written permission of NCCN.

PLEASE NOTE that use of this NCCN Content is governed by the End-User License Agreement, and you MAY NOT distribute this Content or use it with any artificial intelligence model or tool.
Printed by Máximo López Chenlo on 5/4/2026 6:13:37 PM. Copyright © 2026 National Comprehensive Cancer Network, Inc. All Rights Reserved.

cisplatin arm.[313] The OS and PFS data suggest that the combination regimen may be particularly beneficial for extrahepatic CCA; however gemcitabine plus cisplatin may be more beneficial for intrahepatic CCA. Additional data from phase III trials are needed.

A phase II trial in India randomized patients with advanced BTC with SD after 6 months of gemcitabine-based chemotherapy to either active surveillance or switch maintenance.[314] The latter consisted of bevacizumab every 21 days and erlotinib once a day. The results showed that switch maintenance improved PFS (median PFS of 3.1 months for the active surveillance group vs. 5.3 months for the switch maintenance group; HR, 0.51; $P = .0013$).

Based on the experiences from phase II or phase III studies, the following gemcitabine-based and fluoropyrimidine-based combination chemotherapy regimens are included as other recommended options for the treatment of patients with advanced BTCs: gemcitabine with cisplatin (category 1 in the first-line setting), capecitabine with oxaliplatin; FOLFOX (preferred regimen in the subsequent-line setting); gemcitabine combined with albumin-bound paclitaxel; gemcitabine with capecitabine or oxaliplatin; and single-agent fluorouracil, capecitabine, and gemcitabine. If a patient is ineligible for cisplatin, carboplatin may be used.[267] The combination of gemcitabine and fluorouracil is not included due to the increased toxicity and decreased efficacy observed with this regimen[296] when compared with results of studies of the gemcitabine and capecitabine regimen in the setting of advanced BTC.

Chemoradiation and Radiation Therapy

Chemoradiation in the setting of advanced BTCs can provide control of symptoms due to local tumor effects and may prolong OS. However, there are limited clinical trial data to define a standard regimen or definitive benefit. In a retrospective analysis of 37 patients treated with chemoradiation for unresectable extrahepatic CCA, the actuarial OS rates at 1 and 2 years were 59% and 22%, respectively, although effective local control was observed in the majority of patients during this time period (actuarial local control rates of 90% and 71% at 1 and 2 years, respectively).[315] The most extensively investigated chemotherapeutic agent for use in concurrent chemoradiation in the treatment of BTCs has been fluorouracil,[316,317] although capecitabine has been substituted for fluorouracil in some studies.[265] The Panel recommends that concurrent chemoradiation (RT guided by imaging) should be limited to either 5-fluorouracil or capecitabine, and that such treatment should be restricted to patients without evidence of metastatic disease. Concurrent chemoradiation with gemcitabine is not recommended due to the limited experience and toxicity associated with this treatment.

Evidence supports the consideration of RT for treatment of unresectable and metastatic intrahepatic CCA,[158,160,161,318] but there is little evidence to support this treatment option for gallbladder cancer and extrahepatic CCA without concurrent chemotherapy and in patients with unresected disease.[319,320]

Targeted Therapy

BTCs are known to harbor clinically relevant molecular alterations that are differentially expressed in gallbladder cancer and intrahepatic and extrahepatic CCAs. The rarity of individual subgroups limits precise incidence and frequency estimates. Given emerging evidence regarding actionable targets for treating BTCs, comprehensive molecular profiling is recommended for patients with unresectable or metastatic BTC who are candidates for systemic therapy (see *Principles of Molecular Testing* in the algorithm for additional information regarding testing modalities and considerations).[321] While most BTCs are considered sporadic, up to 10% to 15% of BTCs may be associated with an inherited cancer predisposition syndrome.[322,323] As evidence remains insufficient for definitive

Discussion update in progress

Version 1.2026 © 2026 National Comprehensive Cancer Network© (NCCN©), All rights reserved. NCCN Guidelines® and this illustration may not be reproduced in any form without the express written permission of NCCN.

PLEASE NOTE that use of this NCCN Content is governed by the End-User License Agreement, and you MAY NOT distribute this Content or use it with any artificial intelligence model or tool.
Printed by Máximo López Chenlo on 5/4/2026 6:13:37 PM. Copyright © 2026 National Comprehensive Cancer Network, Inc. All Rights Reserved.

recommendations regarding specific criteria to guide genetic risk assessment in hepatobiliary cancers or for universal germline testing, genetic counselling referral and potential germline testing should be considered in patients with BTCs with any of the following: young age at diagnosis; a strong personal or family history of cancer; no known risk factors for liver disease; or the presence of mutations identified during tumor testing that are suspected to be possible germline alterations. For patients who harbor a known germline mutation associated with a cancer predisposing syndrome (ie, Lynch syndrome or hereditary breast and ovarian cancer syndrome), there is currently insufficient evidence to support screening for biliary tract malignancies.

NTRK Fusions

NTRK is a membrane-bound receptor that autophosphorylates and activates downstream pathways that drive oncogenesis. *NTRK1/NTRK2/NTRK3* fusions are estimated to occur at <1% prevalence in BTCs.[324,325] Three NTRK inhibitors have been approved by the FDA for a tumor agnostic indication in *NTRK* fusion-positive solid tumors: larotrectinib[326] in 2018, entrectinib[327] in 2019, and repotrectinib[328] in 2024. Studies with entrectinib and larotrectinib have demonstrated response rates in the 57% to 75% range in pre-treated *NTRK* fusion-positive tumors.[325-327] These studies included small numbers of patients with CCA and demonstrated evidence of clinical benefit. Abstract data for repotrectinib showed a confirmed ORR of 50% in patients with tyrosine kinase inhibitor-pretreated *NTRK* fusion-positive solid tumors.[328] Entrectinib, larotrectinib, and repotrectinib are useful in certain circumstances first-line or subsequent-line (for progressive disease) systemic therapy options for unresectable or metastatic *NTRK* gene fusion-positive tumors. In the subsequent-line setting, repotrectinib is an option if there was progression on a prior therapy, which may include prior NTRK inhibitors; entrectinib and larotrectinib should not be used if there was progression on prior NTRK inhibitors.

Testing for *NTRK* fusions is recommended for patients with unresectable or metastatic gallbladder cancer, intrahepatic CCA, or extrahepatic CCA. These assessments are feasible in the context of multi-target assessment in next-generation sequencing (NGS) gene panels currently in clinical use and *NTRK* fusion-positive CCAs have demonstrated responses in clinical trials.

Immunotherapy Biomarkers (MSI-H/dMMR/TMB-H/PD-L1)

Mismatch repair (MMR) deficiency results from somatic alterations in *MLH1, MSH2, MSH6,* and *PMS2,* which are genes encoding proteins that regulate DNA repair. MMR deficiency results in a unique genetic signature characterized by high rates of mutations, particularly in repetitive DNA sequences called microsatellites that occur throughout the genome. This signature is referred to as MSI or MSI-H. MSI-H or mismatch repair deficient (dMMR) status is rare in BTCs and has an approximate incidence of 1% to 3%.[329-331]

Tumor mutational burden (TMB) is defined as the total number of somatic mutations per coding area of a tumor's genome. Higher rates of tumor mutation may result in increased production of immunogenic mutant proteins or neoantigens.[331-336] The incidence of TMB-high (TMB-H) has been shown to be <5% across studies.[321,337]

The programmed cell death ligand 1 (PD-L1) system functions to inhibit T cell functions. PD-L1 protein expression on malignant or inflammatory associated tumor cells generally indicates active tumor immunity suppressed by the programmed cell death protein 1 (PD-1)/PD-L1 system. In BTCs, PD-L1 high status ranges from around 45% to 65% for combined tumor plus immune cell PD-L1 expression ≥1%, and 10% to 70% for tumor cell PD-L1 expression ≥1%.[331,333]

Discussion update in progress

Version 1.2026 © 2026 National Comprehensive Cancer Network© (NCCN©), All rights reserved. NCCN Guidelines® and this illustration may not be reproduced in any form without the express written permission of NCCN.

PLEASE NOTE that use of this NCCN Content is governed by the End-User License Agreement, and you MAY NOT distribute this Content or use it with any artificial intelligence model or tool.
Printed by Máximo López Chenlo on 5/4/2026 6:13:37 PM. Copyright © 2026 National Comprehensive Cancer Network, Inc. All Rights Reserved.

MSI-H or MMR deficiency are predictive of substantially higher rates of durable, objective response to immune checkpoint inhibition in patients across a range of solid tumor types in studies that have included patients with BTCs.[329,333,338,339] In the KEYNOTE-158 trial, 233 patients with MSI-H or dMMR non-colorectal solid tumor types after failure of standard therapy, including 22 patients with CCA, demonstrated an ORR of 34.3% (95% CI, 28.3%–40.8%) with median PFS of 4.1 months (95% CI, 2.4–4.9 months) and median OS of 23.5 months (95% CI, 13.5 months–not reached).[338] Grade 3–5 treatment-related adverse events were observed in 14.6% of patients. Analyses of a CCA subgroup (*N* = 22) revealed an ORR of 40.9% (95% CI, 20.7%–63.6%) with a median PFS and OS of 4.2 months (95% CI, 2.1 months–not reached) and 24.3 months (95% CI, 6.5 months–not reached), respectively. The results from an updated analysis showed that out of 351 patients with advanced MSI-H/dMMR noncolorectal solid tumors who received prior treatment, 30.8% (95% CI, 25.8%–36.2% achieved an overall response.[339] The median PFS, median OS, and median duration of response (DOR) were 3.5 months (95% CI, 2.3–4.2 months), 20.1 months (95% CI, 14.1–27.1 months), and 47.5 months (95% CI, 2.1+ to 51.1+ months), respectively. Twelve percent of patients experienced a grade 3–5 treatment-related adverse event. In the CCA/biliary tract subgroup, the ORR was the same as previously reported. The median PFS was 4.2 months (95% CI, 2.1–24.9 months) and the median OS was 19.4 months (95% CI, 6.5 months–not reached). These findings contributed to the FDA approval of pembrolizumab for patients with unresectable or metastatic MSI-H or dMMR solid tumors, as determined by an FDA-approved test, which have progressed following prior treatment and who have no satisfactory alternative treatment options, agnostic to tumor histology.

In the KEYNOTE-158 trial, 102 of 805 evaluable patients were found to have tumors with TMB-H status, defined as ≥10 mutations/megabase of DNA based upon the platform used; objective radiographic responses occurred in 29% of patients (95% CI, 21%–39%) by comparison with only 6% of patients (95% CI, 5%–8%) in the non-TMB-H group.[332] These findings led to a histology-agnostic FDA approval of pembrolizumab for patients with TMB-H advanced solid tumors that have progressed following prior treatment and who have no satisfactory alternative treatment options. Though none of the 63 BTC patients in the KEYNOTE-158 TMB cohort were found to harbor TMB-H tumors, other studies have shown that approximately 4% of advanced BTCs have TMB-H tumors, supporting testing for TMB in this population.[331,334]

Pembrolizumab is a useful in certain circumstances first-line or subsequent-line (for progressive disease and with no prior treatment with a checkpoint inhibitor) systemic therapy option for unresectable or metastatic MSI-H, dMMR, or TMB-H (for subsequent-line therapy only) BTCs, though the Panel cautions that data to support this recommendation are limited, particularly in the first-line setting.[340]

Dostarlimab-gxly, another anti-PD-1 antibody, was assessed in the open-label phase I GARNET study with 2 cohorts.[341] One cohort had patients with advanced or recurrent MSI-H/dMMR endometrial cancer and another had patients with advanced or recurrent MSI-H/dMMR or POLE-mutated non-endometrial solid tumors. The ORR for the cohort with non-endometrial cancer was 43.1% (95% CI, 36.2%–50.2%). The median DOR and median OS were not reached at the time of follow up and the median PFS was 7.1 months. The most frequent grade 3 or higher treatment-emergent adverse events were anemia (2.5%), increased lipase (1.3%), and increased alanine aminotransferase (1.9%). Dostarlimab-gxly is a category 2B useful in certain circumstances subsequent-line systemic therapy option for patients with MSI-H/dMMR recurrent or advanced tumors that have progressed on or following prior treatment, who have no satisfactory alternative treatment options, and who have not been previously treated with a checkpoint inhibitor.

Discussion update in progress

Version 1.2026 © 2026 National Comprehensive Cancer Network© (NCCN©), All rights reserved. NCCN Guidelines® and this illustration may not be reproduced in any form without the express written permission of NCCN.

PLEASE NOTE that use of this NCCN Content is governed by the End-User License Agreement, and you MAY NOT distribute this Content or use it with any artificial intelligence model or tool.
Printed by Máximo López Chenlo on 5/4/2026 6:13:37 PM. Copyright © 2026 National Comprehensive Cancer Network, Inc. All Rights Reserved.

The phase II CheckMate 848 trial randomized patients with unresectable or metastatic TMB-H solid tumors with no prior immunotherapy and who had disease refractory to standard local therapies 2:1 to receive the combination of nivolumab and ipilimumab or nivolumab monotherapy.[342] TMB status was assessed using tumor tissue (tTMB) or circulating tumor DNA in the blood (bTMB). The data revealed an ORR of 38.6% (95% CI, 28.4%–49.6%) (vs. 29.8% for nivolumab [95% CI, 17.3%–44.9%]), a median OS of 15.0 months (95% CI, 10.2–29.8 months) (vs. 14.6 months for nivolumab [95% CI, 7.7–20.7 months]), and a median PFS of 5.7 months (95% CI, 3.2–11.6 months) (vs. 2.8 months for nivolumab [95% CI, 2.7–5.7 months]) in patients with tTMB-H tumors treated with nivolumab plus ipilimumab. In patients with bTMB-H tumors treated with nivolumab plus ipilimumab, the ORR, median OS, and median PFS were 22.5% (95% CI, 13.9%–33.2%) (vs. 15.6% for nivolumab [95% CI, 6.5%–29.5%]), 8.1 months (95% CI, 5.8–10.5 months) (vs. 11.2 months for nivolumab [95% CI, 5.3–19.0 months]), and 2.8 months (95% CI, 2.3–3.0 months) (vs. 2.8 months for nivolumab [95% CI, 2.6–3.3 months]), respectively. Treatment-related adverse events occurred in 28.7% of patients with tTMB-H tumors (vs. 8.0% for nivolumab) and in 37.3% of patients with bTMB-H tumors (vs. 2.1% for nivolumab) treated with the combination therapy. Nivolumab plus ipilimumab is a useful in certain circumstances first-line (category 2B) or subsequent-line (for progressive disease and with no prior treatment with a checkpoint inhibitor) systemic therapy option for patients with unresectable or metastatic TMB-H tumors. In the subsequent-line setting, the recommendation is for patients with disease refractory to standard therapies or who have no standard treatment options available.

Testing for MSI or MMR deficiency is recommended in patients with unresectable or metastatic gallbladder cancer, intrahepatic CCA, or extrahepatic CCA. Further recommendations for MSI/MMR testing can be found in the NCCN Guidelines for Colon Cancer (available at www.NCCN.org). Testing for TMB is recommended for patients with unresectable or metastatic gallbladder cancer, intrahepatic CCA, or extrahepatic CCA based upon clinical benefit observed across advanced solid tumors.

In advanced BTCs, tumor or tumor plus immune cell PD-L1 expression has shown trends towards higher rates of objective radiographic response in single-arm phase 2 studies of pembrolizumab or nivolumab as monotherapy.[333,343] However, ORR rates are low overall and data from these small, uncontrolled studies are insufficient to warrant a recommendation for testing. PD-L1 testing is not used as PD-L1 negative disease can still respond to anti-PD-1/PD-L1 drugs, albeit at a lower rate than PD-L1 positive disease.[344]

In a phase II trial with 46 evaluable patients with advanced BTCs, an ORR of 22% and a disease control rate of 59% were obtained, upon investigator assessment, with the use of nivolumab, another anti-PD1 drug.[343] With blinded independent central review, the ORR was 11% and the disease control rate was 50%. In the intention-to-treat cohort, the median PFS and median OS were 3.7 months (95% CI, 2.3–5.7 months) and 14.2 months (95% CI, 6.0 months–not reached), respectively. Nivolumab is a category 2B useful in certain circumstances subsequent-line systemic therapy option for patients with unresectable or metastatic progressive disease who have not been previously treated with a checkpoint inhibitor. Nivolumab and hyaluronidase-nvhy subcutaneous injection may be substituted for intravenous nivolumab. Nivolumab and hyaluronidase-nvhy has different dosing and administration instructions compared to intravenous nivolumab.

BRAF V600E Mutations

Mutation in the *BRAF* gene may lead to constitutive activation of the MAPK pathway. The most common *BRAF* mutation is type 1 alteration, which results in a single amino acid substitution of valine at residue 600 typically with glutamic acid (V600E). *BRAF* mutations have been reported in around 1% to 5% of BTCs.[325,345-348] The phase II, open-label, single-arm,

Discussion update in progress

Version 1.2026 © 2026 National Comprehensive Cancer Network© (NCCN©), All rights reserved. NCCN Guidelines® and this illustration may not be reproduced in any form without the express written permission of NCCN.

multicenter, Rare Oncology Agnostic Research (ROAR) basket trial enrolled 43 patients with *BRAF* V600E-mutated BTC, who had previously received systemic therapy.[345] The primary endpoint of an ORR was achieved by 22 patients (ORR, 51%; 95% CI, 36%–67%). Median PFS and OS were 9 months (95% CI, 5–10 months) and 14 months (95% CI, 10–33 months), respectively. Results from the Subprotocol H trial, which enrolled patients with solid tumors (except for melanoma, thyroid, colorectal cancer, and later non-small cell lung cancer) with a BRAF *V600E* mutation, revealed an ORR of 38% (90% CI, 22.9%–54.9%; $P < .0001$) and a PFS of 11.4 months (90% CI, 8.4–16.3 months) in 29 patients.[349] Dabrafenib plus trametinib received accelerated FDA approval for *BRAF* V600E advanced solid tumors. The oral combination of dabrafenib and trametinib is a useful in certain circumstances subsequent-line systemic therapy option for unresectable or metastatic progressive *BRAF* V600E-mutated tumors.

Testing for *BRAF* V600E mutations is recommended for patients with unresectable or metastatic gallbladder cancer, intrahepatic CCA, or extrahepatic CCA.

FGFR2 Fusions/Other FGFR Pathway Aberrations

FGFR2 is a member of the *FGFR* family of receptor tyrosine kinases that activate a variety of downstream signaling cascades leading to cell proliferation and tumorigenesis. *FGFR2* fusions or rearrangements occur at ~9% to 15% prevalence in intrahepatic CCAs and are rare in other subsites.[337,350,351] Pan-FGFR inhibitors have received accelerated approval from the FDA for the treatment of pre-treated, locally advanced or metastatic *FGFR2*-fusion/rearranged CCA. Results from the phase II FOENIX-CA2 trial demonstrated an ORR of 42% (95% CI, 32%–52%) with futibatinib in patients with previously unresectable or metastatic intrahepatic CCA with *FGFR2* fusions/rearrangements.[352] The median OS, median PFS, median DOR, and disease control rate were 21.7 months (95% CI, 14.5 months–not reached), 9.0 months (95% CI, 6.9–13.1 months), 9.7 months (95% CI, 7.6–17.0 months), and 83% (95% CI, 74%–89%), respectively. Studies are ongoing to determine the activity of individual FGFR inhibitors for specific *FGFR* kinase domain activating mutations or other *FGFR* aberrations. Pemigatinib FDA approval in 2020 was based on the FIGHT-202 study, an open-label study including 108 patients with advanced, pre-treated *FGFR2*-fusion-positive or *FGFR2*-rearranged CCA.[353,354] The ORR was 37.0% (95% CI, 27.9%–46.9%), with a median PFS of 7.0 months (95% CI, 6.1–10.5 months), a median OS of 17.5 months (95% CI, 14.4–22.9 months), and median DOR of 9.1 months (95% CI, 6.0–14.5 months).[354]

The phase II RAGNAR study investigated the efficacy of erdafitinib, a selective pan-FGFR tyrosine kinase inhibitor, in patients with advanced or metastatic tumors of any histology (except urothelial cancer) with *FGFR*1-4 alterations and disease progression on a prior systemic therapy and with no alternative standard therapies.[355] An objective response was achieved in 30% (95% CI, 24%–36%) of patients. The median DOR, median OS, and median PFS were 6.9 months (95% CI, 4.4–7.1 months), 10.7 months (95% CI, 8.7–12.1 months), and 4.2 months (95% CI, 4.1–5.5 months), respectively. Fourteen percent of patients had CCA. For this subset of patients, the ORR was 52% (95% CI, 33%–70%). The median DOR, median OS, and median PFS were 5.5 months (95% CI, 2.9–not evaluable), 14.7 months (95% CI, 12.1–24.3 months), and 8.3 months (95% CI, 6.4–9.7 months), respectively. In addition, interim results from the phase II FIDES-01 study were reported in a published abstract.[356] Treatment with derazantinib, an FGFR 1-3 inhibitor, resulted in an ORR of 8.7%, as determined by the investigator, a median PFS of 7.3 months (95% CI, 3.5–16.7 months), and a disease control rate of 73.9% (95% CI, 51.6%–89.8%) in patients with advanced intrahepatic CCA with *FGFR2* mutations or amplifications who received prior chemotherapy treatment.

Discussion update in progress

Version 1.2026 © 2026 National Comprehensive Cancer Network© (NCCN©), All rights reserved. NCCN Guidelines® and this illustration may not be reproduced in any form without the express written permission of NCCN.

PLEASE NOTE that use of this NCCN Content is governed by the End-User License Agreement, and you MAY NOT distribute this Content or use it with any artificial intelligence model or tool.
Printed by Máximo López Chenlo on 5/4/2026 6:13:37 PM. Copyright © 2026 National Comprehensive Cancer Network, Inc. All Rights Reserved.

Futibatinib, pemigatinib, and erdafitinib are useful in certain circumstances subsequent-line systemic therapy options for unresectable or metastatic progressive CCA with *FGFR2* fusions or rearrangements. Futibatinib and pemigatinib are preferred over erdafitinib.

Testing for *FGFR2* fusions or rearrangements is recommended for patients with unresectable or metastatic intrahepatic or extrahepatic CCA and should be considered for patients with unresectable or metastatic gallbladder cancer.

IDH1 Mutations

The isocitrate dehydrogenase-1 (IDH-1) enzyme catalyzes the conversion of alpha-ketoglutarate to D-2-hydroxyglutarate (2-HG), an aberrant metabolite that impacts chromatin regulation and cellular differentiation. Activating mutations in the *IDH1* gene lead to high levels of 2-HG accumulation and impairment of normal differentiation, accumulation of hepatic progenitor cells, and malignant transformation to intrahepatic CCA.[357] *IDH1* mutations have been reported in approximately 10% to 20% of intrahepatic CCAs and are rare in other subsites.[350,358,359] In a randomized phase III study with 185 patients with *IDH1*-mutated CCA that progressed on standard chemotherapy, ivosidenib resulted in prolongation of PFS over placebo, with a median PFS of 2.7 versus 1.4 months (HR, 0.37; $P < .0001$).[360] Patients with ivosidenib had significantly less decline in physical functioning scores than those treated with placebo. In the intention-to-treat population, the median OS for the ivosidenib and placebo arms were 10.3 months (95% CI, 7.8–12.4 months; HR, 0.79 [95% CI, 0.56–1.12]; $P = .09$) and 7.5 months (95% CI, 4.8–11.1 months), respectively.[361] After taking into account 43 patients who crossed from the placebo arm to the ivosidenib arm, the median OS for the placebo arm was 5.1 months (95% CI, 3.8–7.6 months; HR, .49 [95% CI, 0.34–0.70]; $P < .001$). Ascites was the most frequently reported grade 3 or higher treatment-emergent adverse event in both groups. Ivosidenib has been approved by the FDA for previously treated, locally advanced or metastatic CCA harboring *IDH1* mutations. Ivosidenib is a category 1 useful in certain circumstances subsequent-line systemic therapy option for unresectable or metastatic progressive CCA with *IDH1* mutations. Clinical trials of next-generation IDH1 inhibitors are ongoing.

Testing for *IDH1* mutations is recommended for patients with unresectable or metastatic intrahepatic CCA or extrahepatic CCA and should be considered for patients with unresectable or metastatic gallbladder cancer.

HER2/ERBB2 Overexpression/Amplification/Activating Mutations

HER2 (*ERBB2*) is a member of the *ErbB/EGFR* family of receptor tyrosine kinases that functions as both a homodimer and heterodimer with other family members to activate a variety of downstream signaling cascades leading to cell proliferation and tumorigenesis. HER2 overexpression or pathway activation is present in around 5% to 20% of CCAs, and 15% to 30% of gallbladder cancer.[351,359,362-368] Early clinical trials of HER2-targeted therapy in BTCs failed to show efficacy[369,370] but these studies were unselected for HER2 overexpression/amplification or mutation.

Several studies have reported promising results of HER2-targeted therapy in BTCs.[371-373] In the phase II DESTINY-PanTumor02 trial, treatment with trastuzumab deruxtecan, a HER2 targeted antibody-drug conjugate, in 267 patients with locally advanced or metastatic HER2 overexpressing tumors after prior systemic treatment or without alternative treatments, resulted in improved outcomes.[374] With an ORR of 61.3% (95% CI, 49.4%–72.4%), median OS, median PFS, and median DOR of 21.1 months (95% CI, 15.3–29.6 months), 11.9 months (95% CI, 8.2–13.0 months), and 22.1 months (95% CI, 9.6 months–not reached), respectively, clinical benefit was more pronounced in patients with HER2 IHC3+ expression. Of 16 patients with BTCs with HER IHC3+ expression, the investigator-assessed ORR, median OS, and median PFS were 56.3%, 12.4 months, and 7.4 months,

Discussion update in progress

Version 1.2026 © 2026 National Comprehensive Cancer Network© (NCCN©), All rights reserved. NCCN Guidelines® and this illustration may not be reproduced in any form without the express written permission of NCCN.

PLEASE NOTE that use of this NCCN Content is governed by the End-User License Agreement, and you MAY NOT distribute this Content or use it with any artificial intelligence model or tool.
Printed by Máximo López Chenlo on 5/4/2026 6:13:37 PM. Copyright © 2026 National Comprehensive Cancer Network, Inc. All Rights Reserved.

respectively. The results of the phase II HERB trial from Japan showed that out of 22 evaluable patients with HER2-positive BTCs refractory or intolerant to a gemcitabine-based regimen, 36.4% (95% CI, 19.6%–56.1%) achieved a significantly improved confirmed ORR (*P* = .01) following treatment with trastuzumab deruxtecan.[375] The median OS, PFS, and disease control rate were 7.1 months (95% CI, 4.7%–14.6%), 5.1 months (95% CI, 3.0%–7.3%), and 81.8% (95% CI, 59.7%–94.8%), respectively. Encouraging data were also reported in patients with HER2-low disease (ORR, 12.5%; median OS, 8.9 months; median PFS, 3.5 months; disease control rate, 75.0%).

Javle et al[376] retrospectively reported 8 patients with advanced gallbladder carcinoma harboring HER2 overexpression or amplification treated with trastuzumab (alone or in combination with pertuzumab or chemotherapy); all patients experienced disease stability (3), partial response (PR) (4), or CR (1). The MyPathway study included 39 patients with HER2 amplified and/or overexpressed previously treated, metastatic BTCs.[377] Patients received pertuzumab plus trastuzumab, and 9 patients achieved a PR (ORR, 23%; 95% CI, 11%–39%) with an additional 11 patients showing SD for >4 months. In the TAPUR study, out of 28 evaluable patients with advanced BTC with an *ERBB2/3* alteration treated with pertuzumab plus trastuzumab, 32% (95% CI, 16%–52%) had an objective response.[378] The disease control rate was 40% (90% CI, 27%–100%). Additionally, a prospective pilot study of a trastuzumab biosimilar (trastuzumab-pkrb) in combination with chemotherapy (gemcitabine plus cisplatin) included 4 patients with BTC and identified a PR in 2 patients and SD in 2 patients.[379]

In the phase II SGNTUC-019 study, 46.7% (90% CI, 30.8%–63.0%) of patients with HER2-positive metastatic BTCs treated with tucatinib and trastuzumab as subsequent therapy achieved the primary endpoint (confirmed ORR).[380] The disease control rate was 76.7% (90% CI, 60.6%–88.5%), with a median DOR and PFS of 6.0 months (90% CI, 5.5–6.9 months) and 5.5 months (90% CI, 3.9–8.1 months), respectively.

The phase IIb HERIZON-BTC-01 trial investigated the efficacy of zanidatamab, a HER2-targeted bispecific antibody, in patients with *HER2*-amplified unresectable, locally advanced, or metastatic BTC whose disease progressed following prior treatment with a gemcitabine-based therapy.[381] Patient were assigned to 2 cohorts: cohort 1 (IHC2+ or IHC3+) and cohort 2(IHC0 or IHC1+). In cohort 1, 41.3% (95% CI. 30.4%–52.8%) of patients achieved the primary endpoint of confirmed ORR, as assessed by independent central review. The disease control rate was 68.8% (95% CI, 57.4%–78.7%), and the median DOR and median PFS were 12.9 months (95% CI, 6.0 months–not estimable) and 5.5 months (3.7–7.2 months), respectively. A subgroup analysis of cohort 1 showed responses in all 3 subtypes examined (gallbladder cancer ORR, 46.3%; intrahepatic CCA ORR, 30.4%; extrahepatic CCA, 43.8%). Additionally, the response was more pronounced in patients with IHC3+ tumors (51.6%) compared to those with IHC2+ tumors (5.6%).

Of 25 patients with BTCs in the SUMMIT trial, a phase II basket trial including patients with tumors with HER2 mutations treated with neratinib, 16% had a confirmed objective response.[382] First-line treatment of patients with HER2-positive BTC (96% of whom had gallbladder cancer and 78% of whom had ≥2 metastatic sites) with gemcitabine and cisplatin plus trastuzumab yielded a median PFS of 7 months (95% CI, 6.2–7.8 months) and a PFS rate of 75.6% (95% CI, 66.6%–84.6%) at 6 months.[383]

Fam-trastuzumab deruxtecan-nxki (for IHC3+ tumors), trastuzumab plus pertuzumab (for IHC3+/ISH+/NGS amplification tumors), tucatinib plus trastuzumab (for IHC3+/ISH+/NGS amplification tumors), and zanidatamab-hrii (for IHC3+ tumors) are useful in certain circumstances subsequent-line systemic therapy options for unresectable or metastatic progressive HER2-positive tumors.

Discussion update in progress

Version 1.2026 © 2026 National Comprehensive Cancer Network© (NCCN©), All rights reserved. NCCN Guidelines® and this illustration may not be reproduced in any form without the express written permission of NCCN.

PLEASE NOTE that use of this NCCN Content is governed by the End-User License Agreement, and you MAY NOT distribute this Content or use it with any artificial intelligence model or tool.
Printed by Máximo López Chenlo on 5/4/2026 6:13:37 PM. Copyright © 2026 National Comprehensive Cancer Network, Inc. All Rights Reserved.

Testing for HER2 (*ERBB2*) overexpression/amplification is recommended for patients with unresectable or metastatic gallbladder cancer, intrahepatic CCA, or extrahepatic CCA.

Other Biomarkers (RET/ROS1, KRAS G12C/Other KRAS, Other Tumor-Agnostic Markers)

In addition to the genomic alterations described in the previous sections, NGS testing may uncover other potentially actionable molecular alterations that could help determine eligibility for ongoing clinical trials in patients with advanced BTCs. While there is insufficient evidence to recommend universal assessment, alterations for which targeted therapies exist and have been FDA-approved in other tumor types, including *KRAS* G12C mutation,[384-386] *MET* amplification,[387-389] *ALK*,[390] *RET*,[391] or *ROS1* fusions,[392] among others,[393] have been described with variable but overall rare frequency in biliary tract carcinomas and HCC.[394] *RET* fusions have been reported to occur in approximately <1% of patients with BTCs, while *KRAS* G12C mutations have been reported in about 1% of patients.[395,396] Limited data currently exist regarding the efficacy of targeted therapy in these situations, due to their rarity.

In the phase I/II ARROW study, pralsetinib, a selective RET inhibitor, demonstrated an ORR of 57% (95% CI, 35%–77%) in patients with *RET* fusion-positive tumors other than non-small cell lung cancer and thyroid cancer and who received prior treatment or were ineligible for standard therapies.[391] The median OS, median PFS, and median DOR were 14 months, 7 months, and 12 months, respectively. A response was observed in two out of three patients who had CCA. However, *RET* mutations in CCA are rare.[397] Pralsetinib is a category 2B useful in certain circumstances first-line or subsequent-line (for progressive disease) systemic therapy option for unresectable or metastatic *RET* gene fusion-positive tumors.

Selpercatinib, a selective RET kinase inhibitor, was investigated in the phase 1/2 LIBRETTO-001 clinical trial in patients with *RET* fusion-positive tumors.[398] Of 41 patients evaluable for efficacy and with tumors other than lung or thyroid, the ORR, as assessed by an independent review committee, was 43.9% (95% CI, 28.5%–60.3%). An objective response was obtained in the one patient who had CCA. Selpercatinib is a useful in certain circumstances first-line (category 2B) or subsequent-line (for progressive disease) systemic therapy option for unresectable or metastatic *RET* gene fusion-positive tumors.

Testing for *RET* fusions is recommended for patients with unresectable or metastatic gallbladder cancer, intrahepatic CCA, or extrahepatic CCA. A comprehensive NGS panel may identify additional alterations for which targeted therapies exist and have FDA-approved treatments in other tumor types.

The phase II KRYSTAL-1 trial investigated adagrasib, a KRAS inhibitor, in patients with unresectable or solid tumors with a *KRAS* G12C mutation.[386] 35.1% (95% CI, 22.9%–48.9%) of patients had an objective response, with a median DOR of 5.3 months, a median OS of 14.0 months, and a median PFS of 7.4 months. In patients with BTCs, the ORR was 41.7% (50.0% of 8 patients with CCA, 33.3% of 3 patients with ampullary cancer, and 0% of 1 patient with gallbladder cancer), with a median OS of 15.1 months and a median PFS of 6.9 months. Adagrasib is a useful in certain circumstances subsequent-line systemic therapy option for unresectable or metastatic progressive *KRAS* G12C mutation-positive tumors.

Testing for *KRAS* G12C mutations is recommended for patients with unresectable or metastatic gallbladder cancer, intrahepatic CCA, or extrahepatic CCA.

Other Targeted Therapies

In a phase II trial, regorafenib was found to have a disease control rate of 56% and could thus be useful in patients with disease refractory to chemotherapy.[197] Another phase II trial reported an ORR of 9.1% and a

Discussion update in progress

Version 1.2026 © 2026 National Comprehensive Cancer Network© (NCCN©), All rights reserved. NCCN Guidelines® and this illustration may not be reproduced in any form without the express written permission of NCCN.

PLEASE NOTE that use of this NCCN Content is governed by the End-User License Agreement, and you MAY NOT distribute this Content or use it with any artificial intelligence model or tool.
Printed by Máximo López Chenlo on 5/4/2026 6:13:37 PM. Copyright © 2026 National Comprehensive Cancer Network, Inc. All Rights Reserved.

disease control rate of 64%.[399] In the phase II REACHIN trial, patients with BTCs were randomized to receive best supportive care along with either regorafenib or placebo.[400] The median PFS for patients in the regorafenib arm was 3.0 months compared to 1.5 months for those in the placebo arm. The median OS was 5.3 months for the regorafenib group compared to 5.1 months for the placebo group. Regorafenib is a category 2B subsequent-line systemic therapy option (other recommended regimen) for unresectable or metastatic progressive disease.

Summary

BTCs are associated with a poor prognosis and patients with BTCs commonly present with advanced disease. In the past few years, several advances have been made in the therapeutic approaches. Complete resection of the tumor in well-selected patients is currently the best available potentially curative treatment. Ablation is potentially curative for small intrahepatic CCAs. Consideration of locoregional therapy is included as an option for patients with unresectable or metastatic intrahepatic CCA. The combination of chemotherapy and chemoradiation, chemoradiation alone, and consideration of referral to a transplant center are options for unresectable intrahepatic or extrahepatic CCA. Palliative RT may be used in patients with unresectable gallbladder cancer or extrahepatic CCA. Systemic therapy is also an option for patients with unresectable or metastatic BTCs.

The combination of durvalumab/gemcitabine/cisplatin, pembrolizumab/gemcitabine/cisplatin, as well as the combination of gemcitabine/cisplatin, are included as category 1 first-line systemic therapy recommendations for patients with unresectable or metastatic BTCs. Drugs such as entrectinib, larotrectinib, repotrectinib, pembrolizumab, dostarlimab-gxly, nivolumab plus ipilimumab, dabrafenib plus trametinib, futibatinib, pemigatinib, erdafitinib, ivosidenib, fam-trastuzumab deruxtecan-nxki, trastuzumab plus pertuzumab, tucatinib plus trastuzumab, zanidatamab-hrii, pralsetinib, selpercatinib, and adagrasib, may benefit certain patients with advanced disease harboring specific genomic mutations.

A multidisciplinary team consultation is recommended for the assessment of resectability for patients with gallbladder cancer presenting with jaundice and for intrahepatic and extrahepatic CCAs. Careful patient selection for treatment and patient engagement are essential. Patient participation in prospective clinical trials is encouraged for the treatment of patients with all stages of disease.

Discussion update in progress

Version 1.2026 © 2026 National Comprehensive Cancer Network© (NCCN©), All rights reserved. NCCN Guidelines® and this illustration may not be reproduced in any form without the express written permission of NCCN.

PLEASE NOTE that use of this NCCN Content is governed by the End-User License Agreement, and you MAY NOT distribute this Content or use it with any artificial intelligence model or tool.
Printed by Máximo López Chenlo on 5/4/2026 6:13:37 PM. Copyright © 2026 National Comprehensive Cancer Network, Inc. All Rights Reserved.

Figure 1: Classification of Cholangiocarcinoma

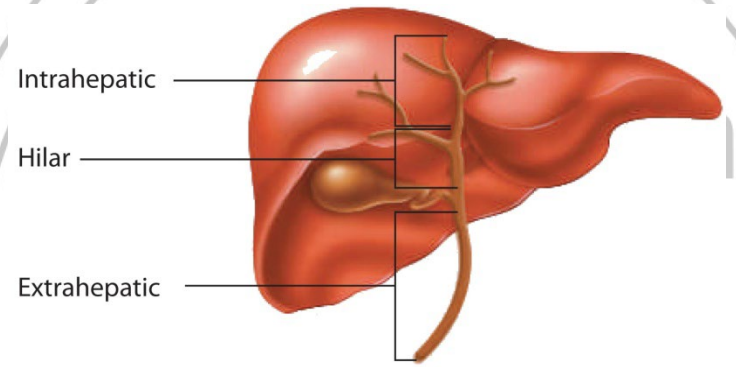

Reproduced with permission from Patel T. Cholangiocarcinoma. Nat Clin Pract Gastroenterol Hepatol 2006;3:33-42.

progress

Version 1.2026 © 2026 National Comprehensive Cancer Network© (NCCN©), All rights reserved. NCCN Guidelines® and this illustration may not be reproduced in any form without the express written permission of NCCN.

PLEASE NOTE that use of this NCCN Content is governed by the End-User License Agreement, and you MAY NOT distribute this Content or use it with any artificial intelligence model or tool.
Printed by Máximo López Chenlo on 5/4/2026 6:13:37 PM. Copyright © 2026 National Comprehensive Cancer Network, Inc. All Rights Reserved.

References

1. Siegel RL, Kratzer TB, Giaquinto AN, et al. Cancer statistics, 2025. CA Cancer J Clin 2025;75:10-45. Available at: https://www.ncbi.nlm.nih.gov/pubmed/39817679.

2. Freedman-Cass DA, Fischer T, Alpert AB, et al. The value and process of inclusion: using sensitive, respectful, and inclusive language and images in NCCN content. J Natl Compr Canc Netw 2023;21:434-441. Available at: https://www.ncbi.nlm.nih.gov/pubmed/37156485.

3. Levy AD, Murakata LA, Rohrmann CA, Jr. Gallbladder carcinoma: radiologic-pathologic correlation. Radiographics 2001;21:295-314; questionnaire, 549-555. Available at: http://www.ncbi.nlm.nih.gov/pubmed/11259693.

4. Jiang Y, Jiang L, Li F, et al. The epidemiological trends of biliary tract cancers in the United States of America. BMC Gastroenterol 2022;22:546. Available at: https://www.ncbi.nlm.nih.gov/pubmed/36581813.

5. Low SK, Giannis D, Thuong ND, et al. Trends in primary gallbladder cancer incidence and incidence-based mortality in the United States, 1973 to 2015. Am J Clin Oncol 2022;45:306-315. Available at: https://www.ncbi.nlm.nih.gov/pubmed/35700074.

6. Randi G, Franceschi S, La Vecchia C. Gallbladder cancer worldwide: geographical distribution and risk factors. Int J Cancer 2006;118:1591-1602. Available at: http://www.ncbi.nlm.nih.gov/pubmed/16397865.

7. Lazcano-Ponce EC, Miquel JF, Munoz N, et al. Epidemiology and molecular pathology of gallbladder cancer. CA Cancer J Clin 2001;51:349-364. Available at: http://www.ncbi.nlm.nih.gov/pubmed/11760569.

8. Miranda-Filho A, Pineros M, Ferreccio C, et al. Gallbladder and extrahepatic bile duct cancers in the Americas: Incidence and mortality patterns and trends. Int J Cancer 2020;147:978-989. Available at: https://www.ncbi.nlm.nih.gov/pubmed/31922259.

9. Sheth S, Bedford A, Chopra S. Primary gallbladder cancer: recognition of risk factors and the role of prophylactic cholecystectomy. Am J Gastroenterol 2000;95:1402-1410. Available at: http://www.ncbi.nlm.nih.gov/pubmed/10894571.

10. Tazuma S, Kajiyama G. Carcinogenesis of malignant lesions of the gall bladder. The impact of chronic inflammation and gallstones. Langenbecks Arch Surg 2001;386:224-229. Available at: http://www.ncbi.nlm.nih.gov/pubmed/11382326.

11. Khan ZS, Livingston EH, Huerta S. Reassessing the need for prophylactic surgery in patients with porcelain gallbladder: case series and systematic review of the literature. Arch Surg 2011;146:1143-1147. Available at: http://www.ncbi.nlm.nih.gov/pubmed/22006872.

12. Schnelldorfer T. Porcelain gallbladder: a benign process or concern for malignancy? J Gastrointest Surg 2013;17:1161-1168. Available at: http://www.ncbi.nlm.nih.gov/pubmed/23423431.

13. Stephen AE, Berger DL. Carcinoma in the porcelain gallbladder: a relationship revisited. Surgery 2001;129:699-703. Available at: http://www.ncbi.nlm.nih.gov/pubmed/11391368.

14. Elnemr A, Ohta T, Kayahara M, et al. Anomalous pancreaticobiliary ductal junction without bile duct dilatation in gallbladder cancer. Hepatogastroenterology 2001;48:382-386. Available at: http://www.ncbi.nlm.nih.gov/pubmed/11379314.

15. Reid KM, Ramos-De la Medina A, Donohue JH. Diagnosis and surgical management of gallbladder cancer: a review. J Gastrointest Surg 2007;11:671-681. Available at: http://www.ncbi.nlm.nih.gov/pubmed/17468929.

16. Hundal R, Shaffer EA. Gallbladder cancer: epidemiology and outcome. Clin Epidemiol 2014;6:99-109. Available at: https://www.ncbi.nlm.nih.gov/pubmed/24634588.

17. Kamaya A, Fung C, Szpakowski JL, et al. Management of incidentally detected gallbladder polyps: Society of Radiologists in Ultrasound consensus conference recommendations. Radiology 2022;305:277-289. Available at: https://www.ncbi.nlm.nih.gov/pubmed/35787200.

Discussion update in progress

Version 1.2026 © 2026 National Comprehensive Cancer Network© (NCCN©), All rights reserved. NCCN Guidelines® and this illustration may not be reproduced in any form without the express written permission of NCCN.

PLEASE NOTE that use of this NCCN Content is governed by the End-User License Agreement, and you MAY NOT distribute this Content or use it with any artificial intelligence model or tool.
Printed by Máximo López Chenlo on 5/4/2026 6:13:37 PM. Copyright © 2026 National Comprehensive Cancer Network, Inc. All Rights Reserved.

18. Williams AS, Huang WY. The analysis of microsatellite instability in extracolonic gastrointestinal malignancy. Pathology 2013;45:540-552. Available at: https://www.ncbi.nlm.nih.gov/pubmed/24018804.

19. Amin MB, ed AJCC Cancer Staging Manual. In: Cancer AJCo, ed (ed 8th). Chicago, IL: Springer; 2017.

20. Shindoh J, de Aretxabala X, Aloia TA, et al. Tumor location is a strong predictor of tumor progression and survival in T2 gallbladder cancer: an international multicenter study. Ann Surg 2015;261:733-739. Available at: https://www.ncbi.nlm.nih.gov/pubmed/24854451.

21. Lee H, Choi DW, Park JY, et al. Surgical strategy for T2 gallbladder cancer according to tumor location. Ann Surg Oncol 2015;22:2779-2786. Available at: https://www.ncbi.nlm.nih.gov/pubmed/25519930.

22. Donohue JH, Stewart AK, Menck HR. The National Cancer Data Base report on carcinoma of the gallbladder, 1989-1995. Cancer 1998;83:2618-2628. Available at: http://www.ncbi.nlm.nih.gov/pubmed/9874470.

23. Duffy A, Capanu M, Abou-Alfa GK, et al. Gallbladder cancer (GBC): 10-year experience at Memorial Sloan-Kettering Cancer Centre (MSKCC). J Surg Oncol 2008;98:485-489. Available at: http://www.ncbi.nlm.nih.gov/pubmed/18802958.

24. Ito H, Ito K, D'Angelica M, et al. Accurate staging for gallbladder cancer: implications for surgical therapy and pathological assessment. Ann Surg 2011;254:320-325. Available at: http://www.ncbi.nlm.nih.gov/pubmed/21617582.

25. Hawkins WG, DeMatteo RP, Jarnagin WR, et al. Jaundice predicts advanced disease and early mortality in patients with gallbladder cancer. Ann Surg Oncol 2004;11:310-315. Available at: http://www.ncbi.nlm.nih.gov/pubmed/14993027.

26. Tran TB, Norton JA, Ethun CG, et al. Gallbladder cancer presenting with jaundice: Uniformly fatal or still potentially curable? J Gastrointest Surg 2017;21:1245-1253. Available at: https://www.ncbi.nlm.nih.gov/pubmed/28497252.

27. Furlan A, Ferris JV, Hosseinzadeh K, Borhani AA. Gallbladder carcinoma update: multimodality imaging evaluation, staging, and treatment options. AJR Am J Roentgenol 2008;191:1440-1447. Available at: http://www.ncbi.nlm.nih.gov/pubmed/18941083.

28. de Savornin Lohman EAJ, de Bitter TJJ, van Laarhoven C, et al. The diagnostic accuracy of CT and MRI for the detection of lymph node metastases in gallbladder cancer: A systematic review and meta-analysis. Eur J Radiol 2019;110:156-162. Available at: https://www.ncbi.nlm.nih.gov/pubmed/30599854.

29. Petrowsky H, Wildbrett P, Husarik DB, et al. Impact of integrated positron emission tomography and computed tomography on staging and management of gallbladder cancer and cholangiocarcinoma. J Hepatol 2006;45:43-50. Available at: http://www.ncbi.nlm.nih.gov/pubmed/16690156.

30. Corvera CU, Blumgart LH, Akhurst T, et al. 18F-fluorodeoxyglucose positron emission tomography influences management decisions in patients with biliary cancer. J Am Coll Surg 2008;206:57-65. Available at: http://www.ncbi.nlm.nih.gov/pubmed/18155569.

31. Lee SW, Kim HJ, Park JH, et al. Clinical usefulness of 18F-FDG PET-CT for patients with gallbladder cancer and cholangiocarcinoma. J Gastroenterol 2010;45:560-566. Available at: http://www.ncbi.nlm.nih.gov/pubmed/20035356.

32. Lamarca A, Barriuso J, Chander A, et al. (18)F-fluorodeoxyglucose positron emission tomography ((18)FDG-PET) for patients with biliary tract cancer: Systematic review and meta-analysis. J Hepatol 2019;71:115-129. Available at: https://www.ncbi.nlm.nih.gov/pubmed/30797051.

33. Strom BL, Maislin G, West SL, et al. Serum CEA and CA 19-9: potential future diagnostic or screening tests for gallbladder cancer? Int J Cancer 1990;45:821-824. Available at: http://www.ncbi.nlm.nih.gov/pubmed/2335386.

34. Dixon E, Vollmer CM, Jr., Sahajpal A, et al. An aggressive surgical approach leads to improved survival in patients with gallbladder cancer: a

Discussion update in progress

Version 1.2026 © 2026 National Comprehensive Cancer Network© (NCCN©), All rights reserved. NCCN Guidelines® and this illustration may not be reproduced in any form without the express written permission of NCCN.

PLEASE NOTE that use of this NCCN Content is governed by the End-User License Agreement, and you MAY NOT distribute this Content or use it with any artificial intelligence model or tool.
Printed by Máximo López Chenlo on 5/4/2026 6:13:37 PM. Copyright © 2026 National Comprehensive Cancer Network, Inc. All Rights Reserved.

12-year study at a North American Center. Ann Surg 2005;241:385-394. Available at: http://www.ncbi.nlm.nih.gov/pubmed/15729060.

35. Fuks D, Regimbeau JM, Le Treut YP, et al. Incidental gallbladder cancer by the AFC-GBC-2009 Study Group. World J Surg 2011;35:1887-1897. Available at: http://www.ncbi.nlm.nih.gov/pubmed/21547420.

36. Lee SE, Jang JY, Lim CS, et al. Systematic review on the surgical treatment for T1 gallbladder cancer. World J Gastroenterol 2011;17:174-180. Available at: http://www.ncbi.nlm.nih.gov/pubmed/21245989.

37. Foster JM, Hoshi H, Gibbs JF, et al. Gallbladder cancer: Defining the indications for primary radical resection and radical re-resection. Ann Surg Oncol 2007;14:833-840. Available at: http://www.ncbi.nlm.nih.gov/pubmed/17103074.

38. Coburn NG, Cleary SP, Tan JC, Law CH. Surgery for gallbladder cancer: a population-based analysis. J Am Coll Surg 2008;207:371-382. Available at: http://www.ncbi.nlm.nih.gov/pubmed/18722943.

39. You DD, Lee HG, Paik KY, et al. What is an adequate extent of resection for T1 gallbladder cancers? Ann Surg 2008;247:835-838. Available at: http://www.ncbi.nlm.nih.gov/pubmed/18438121.

40. Jensen EH, Abraham A, Habermann EB, et al. A critical analysis of the surgical management of early-stage gallbladder cancer in the United States. J Gastrointest Surg 2009;13:722-727. Available at: http://www.ncbi.nlm.nih.gov/pubmed/19083068.

41. Downing SR, Cadogan KA, Ortega G, et al. Early-stage gallbladder cancer in the Surveillance, Epidemiology, and End Results database: effect of extended surgical resection. Arch Surg 2011;146:734-748. Available at: https://www.ncbi.nlm.nih.gov/pubmed/21690451.

42. Shirai Y, Sakata J, Wakai T, et al. "Extended" radical cholecystectomy for gallbladder cancer: long-term outcomes, indications and limitations. World J Gastroenterol 2012;18:4736-4743. Available at: http://www.ncbi.nlm.nih.gov/pubmed/23002343.

43. Widmann B, Warschkow R, Beutner U, et al. Effect of lymphadenectomy in curative gallbladder cancer treatment: a systematic review and meta-analysis. Langenbecks Arch Surg 2020;405:573-584. Available at: https://www.ncbi.nlm.nih.gov/pubmed/32458141.

44. Vega EA, Newhook TE, Kawaguchi Y, et al. Conditional recurrence-free survival after oncologic extended resection for gallbladder cancer: An international multicenter analysis. Ann Surg Oncol 2021;28:2675-2682. Available at: https://www.ncbi.nlm.nih.gov/pubmed/33666814.

45. D'Angelica M, Dalal KM, DeMatteo RP, et al. Analysis of the extent of resection for adenocarcinoma of the gallbladder. Ann Surg Oncol 2009;16:806-816. Available at: http://www.ncbi.nlm.nih.gov/pubmed/18985272.

46. Gani F, Buettner S, Margonis GA, et al. Assessing the impact of common bile duct resection in the surgical management of gallbladder cancer. J Surg Oncol 2016;114:176-180. Available at: https://www.ncbi.nlm.nih.gov/pubmed/27198742.

47. Pawlik TM, Gleisner AL, Vigano L, et al. Incidence of finding residual disease for incidental gallbladder carcinoma: implications for re-resection. J Gastrointest Surg 2007;11:1478-1486; discussion 1486-1487. Available at: http://www.ncbi.nlm.nih.gov/pubmed/17846848.

48. Fong Y, Jarnagin W, Blumgart LH. Gallbladder cancer: comparison of patients presenting initially for definitive operation with those presenting after prior noncurative intervention. Ann Surg 2000;232:557-569. Available at: http://www.ncbi.nlm.nih.gov/pubmed/10998654.

49. Shih SP, Schulick RD, Cameron JL, et al. Gallbladder cancer: the role of laparoscopy and radical resection. Ann Surg 2007;245:893-901. Available at: http://www.ncbi.nlm.nih.gov/pubmed/17522515.

50. Agarwal AK, Kalayarasan R, Javed A, et al. The role of staging laparoscopy in primary gall bladder cancer--an analysis of 409 patients: a prospective study to evaluate the role of staging laparoscopy in the management of gallbladder cancer. Ann Surg 2013;258:318-323. Available at: https://www.ncbi.nlm.nih.gov/pubmed/23059504.

Discussion update in progress

Version 1.2026 © 2026 National Comprehensive Cancer Network© (NCCN©), All rights reserved. NCCN Guidelines® and this illustration may not be reproduced in any form without the express written permission of NCCN.

PLEASE NOTE that use of this NCCN Content is governed by the End-User License Agreement, and you MAY NOT distribute this Content or use it with any artificial intelligence model or tool.
Printed by Máximo López Chenlo on 5/4/2026 6:13:37 PM. Copyright © 2026 National Comprehensive Cancer Network, Inc. All Rights Reserved.

51. Butte JM, Gonen M, Allen PJ, et al. The role of laparoscopic staging in patients with incidental gallbladder cancer. HPB (Oxford) 2011;13:463-472. Available at: http://www.ncbi.nlm.nih.gov/pubmed/21689230.

52. Maker AV, Butte JM, Oxenberg J, et al. Is port site resection necessary in the surgical management of gallbladder cancer? Ann Surg Oncol 2012;19:409-417. Available at: http://www.ncbi.nlm.nih.gov/pubmed/21698501.

53. Fuks D, Regimbeau JM, Pessaux P, et al. Is port-site resection necessary in the surgical management of gallbladder cancer? J Visc Surg 2013;150:277-284. Available at: http://www.ncbi.nlm.nih.gov/pubmed/23665059.

54. Regimbeau JM, Fuks D, Bachellier P, et al. Prognostic value of jaundice in patients with gallbladder cancer by the AFC-GBC-2009 study group. Eur J Surg Oncol 2011;37:505-512. Available at: http://www.ncbi.nlm.nih.gov/pubmed/21514090.

55. Nishio H, Ebata T, Yokoyama Y, et al. Gallbladder cancer involving the extrahepatic bile duct is worthy of resection. Ann Surg 2011;253:953-960. Available at: https://www.ncbi.nlm.nih.gov/pubmed/21490453.

56. Dasari BVM, Ionescu MI, Pawlik TM, et al. Outcomes of surgical resection of gallbladder cancer in patients presenting with jaundice: A systematic review and meta-analysis. J Surg Oncol 2018;118:477-485. Available at: https://www.ncbi.nlm.nih.gov/pubmed/30259519.

57. Hakeem AR, Papoulas M, Menon KV. The role of neoadjuvant chemotherapy or chemoradiotherapy for advanced gallbladder cancer - A systematic review. Eur J Surg Oncol 2019;45:83-91. Available at: https://www.ncbi.nlm.nih.gov/pubmed/30287098.

58. Creasy JM, Goldman DA, Dudeja V, et al. Systemic chemotherapy combined with resection for locally advanced gallbladder carcinoma: surgical and survival outcomes. J Am Coll Surg 2017;224:906-916. Available at: https://www.ncbi.nlm.nih.gov/pubmed/28216422.

59. Chaudhari VA, Ostwal V, Patkar S, et al. Outcome of neoadjuvant chemotherapy in "locally advanced/borderline resectable" gallbladder cancer: The need to define indications. HPB (Oxford) 2018;20:841-847. Available at: https://www.ncbi.nlm.nih.gov/pubmed/29706425.

60. Engineer R, Patkar S, Lewis SC, et al. A phase III randomised clinical trial of perioperative therapy (neoadjuvant chemotherapy versus chemoradiotherapy) in locally advanced gallbladder cancers (POLCAGB): Study protocol. BMJ Open 2019;9:e028147. Available at: https://www.ncbi.nlm.nih.gov/pubmed/31253621.

61. Engineer R, Goel M, Chopra S, et al. Neoadjuvant chemoradiation followed by surgery for locally advanced gallbladder cancers: a new paradigm. Ann Surg Oncol 2016;23:3009-3015. Available at: https://www.ncbi.nlm.nih.gov/pubmed/27075323.

62. Margonis GA, Gani F, Buettner S, et al. Rates and patterns of recurrence after curative intent resection for gallbladder cancer: A multi-institution analysis from the US Extra-hepatic Biliary Malignancy Consortium. HPB (Oxford) 2016;18:872-878. Available at: https://www.ncbi.nlm.nih.gov/pubmed/27527802.

63. Lim JH. Cholangiocarcinoma: morphologic classification according to growth pattern and imaging findings. AJR Am J Roentgenol 2003;181:819-827. Available at: http://www.ncbi.nlm.nih.gov/pubmed/12933488.

64. Banales JM, Marin JJG, Lamarca A, et al. Cholangiocarcinoma 2020: The next horizon in mechanisms and management. Nat Rev Gastroenterol Hepatol 2020;17:557-588. Available at: https://www.ncbi.nlm.nih.gov/pubmed/32606456.

65. Javle M, Lee S, Azad NS, et al. Temporal changes in cholangiocarcinoma incidence and mortality in the United States from 2001 to 2017. Oncologist 2022;27:874-883. Available at: https://www.ncbi.nlm.nih.gov/pubmed/35972334.

66. Saha SK, Zhu AX, Fuchs CS, Brooks GA. Forty-year trends in cholangiocarcinoma incidence in the U.S.: intrahepatic disease on the rise.

Discussion Update in Progress

Version 1.2026 © 2026 National Comprehensive Cancer Network© (NCCN©), All rights reserved. NCCN Guidelines® and this illustration may not be reproduced in any form without the express written permission of NCCN.

PLEASE NOTE that use of this NCCN Content is governed by the End-User License Agreement, and you MAY NOT distribute this Content or use it with any artificial intelligence model or tool.
Printed by Máximo López Chenlo on 5/4/2026 6:13:37 PM. Copyright © 2026 National Comprehensive Cancer Network, Inc. All Rights Reserved.

Oncologist 2016;21:594-599. Available at: https://www.ncbi.nlm.nih.gov/pubmed/27000463.

67. Mukkamalla SKR, Naseri HM, Kim BM, et al. Trends in incidence and factors affecting survival of patients with cholangiocarcinoma in the United States. J Natl Compr Canc Netw 2018;16:370-376. Available at: https://www.ncbi.nlm.nih.gov/pubmed/29632056.

68. Chapman RW. Risk factors for biliary tract carcinogenesis. Ann Oncol 1999;10 Suppl 4:308-311. Available at: http://www.ncbi.nlm.nih.gov/pubmed/10436847.

69. Tyson GL, El-Serag HB. Risk factors for cholangiocarcinoma. Hepatology 2011;54:173-184. Available at: http://www.ncbi.nlm.nih.gov/pubmed/21488076.

70. Huai JP, Ding J, Ye XH, Chen YP. Inflammatory bowel disease and risk of cholangiocarcinoma: evidence from a meta-analysis of population-based studies. Asian Pac J Cancer Prev 2014;15:3477-3482. Available at: https://www.ncbi.nlm.nih.gov/pubmed/24870743.

71. Welzel TM, Graubard BI, El-Serag HB, et al. Risk factors for intrahepatic and extrahepatic cholangiocarcinoma in the United States: a population-based case-control study. Clin Gastroenterol Hepatol 2007;5:1221-1228. Available at: http://www.ncbi.nlm.nih.gov/pubmed/17689296.

72. Clements O, Eliahoo J, Kim JU, et al. Risk factors for intrahepatic and extrahepatic cholangiocarcinoma: A systematic review and meta-analysis. J Hepatol 2020;72:95-103. Available at: https://www.ncbi.nlm.nih.gov/pubmed/31536748.

73. Chang K-Y, Chang J-Y, Yen Y. Increasing incidence of intrahepatic cholangiocarcinoma and its relationship to chronic viral hepatitis. J Natl Compr Canc Netw 2009;7:423-427. Available at: http://www.ncbi.nlm.nih.gov/pubmed/19406042.

74. Wongjarupong N, Assavapongpaiboon B, Susantitaphong P, et al. Non-alcoholic fatty liver disease as a risk factor for cholangiocarcinoma: a systematic review and meta-analysis. BMC Gastroenterol 2017;17:149. Available at: https://www.ncbi.nlm.nih.gov/pubmed/29216833.

75. Endo I, Gonen M, Yopp AC, et al. Intrahepatic cholangiocarcinoma: rising frequency, improved survival, and determinants of outcome after resection. Ann Surg 2008;248:84-96. Available at: http://www.ncbi.nlm.nih.gov/pubmed/18580211.

76. Nathan H, Aloia TA, Vauthey J-N, et al. A proposed staging system for intrahepatic cholangiocarcinoma. Ann Surg Oncol 2009;16:14-22. Available at: http://www.ncbi.nlm.nih.gov/pubmed/18987916.

77. de Jong MC, Nathan H, Sotiropoulos GC, et al. Intrahepatic cholangiocarcinoma: an international multi-institutional analysis of prognostic factors and lymph node assessment. J Clin Oncol 2011;29:3140-3145. Available at: http://www.ncbi.nlm.nih.gov/pubmed/21730269.

78. Edge SB, Byrd DR, Compton CC, et al. AJCC Cancer Staging Manual (ed 7). New York, NY: Springer; 2010.

79. Farges O, Fuks D, Le Treut Y-P, et al. AJCC 7th edition of TNM staging accurately discriminates outcomes of patients with resectable intrahepatic cholangiocarcinoma. Cancer 2011;117:2170-2177. Available at: http://www.ncbi.nlm.nih.gov/pubmed/21523730.

80. de Jong MC, Hong S-M, Augustine MM, et al. Hilar cholangiocarcinoma: tumor depth as a predictor of outcome. Arch Surg 2011;146:697-703. Available at: http://www.ncbi.nlm.nih.gov/pubmed/21690446.

81. Hong S-M, Pawlik TM, Cho H, et al. Depth of tumor invasion better predicts prognosis than the current American Joint Committee on Cancer T classification for distal bile duct carcinoma. Surgery 2009;146:250-257. Available at: http://www.ncbi.nlm.nih.gov/pubmed/19628081.

82. Bismuth H, Nakache R, Diamond T. Management strategies in resection for hilar cholangiocarcinoma. Ann Surg 1992;215:31-38. Available at: http://www.ncbi.nlm.nih.gov/pubmed/1309988.

Discussion update in progress

Version 1.2026 © 2026 National Comprehensive Cancer Network© (NCCN©), All rights reserved. NCCN Guidelines® and this illustration may not be reproduced in any form without the express written permission of NCCN.

PLEASE NOTE that use of this NCCN Content is governed by the End-User License Agreement, and you MAY NOT distribute this Content or use it with any artificial intelligence model or tool.
Printed by Máximo López Chenlo on 5/4/2026 6:13:37 PM. Copyright © 2026 National Comprehensive Cancer Network, Inc. All Rights Reserved.

83. Jarnagin WR, Fong Y, DeMatteo RP, et al. Staging, resectability, and outcome in 225 patients with hilar cholangiocarcinoma. Ann Surg 2001;234:507-517; discussion 517-519. Available at: http://www.ncbi.nlm.nih.gov/pubmed/11573044.

84. Matsuo K, Rocha FG, Ito K, et al. The Blumgart preoperative staging system for hilar cholangiocarcinoma: analysis of resectability and outcomes in 380 patients. J Am Coll Surg 2012;215:343-355. Available at: http://www.ncbi.nlm.nih.gov/pubmed/22749003.

85. Miller G, Schwartz LH, D'Angelica M. The use of imaging in the diagnosis and staging of hepatobiliary malignancies. Surg Oncol Clin N Am 2007;16:343-368. Available at: http://www.ncbi.nlm.nih.gov/pubmed/17560517.

86. Aljiffry M, Walsh MJ, Molinari M. Advances in diagnosis, treatment and palliation of cholangiocarcinoma: 1990-2009. World J Gastroenterol 2009;15:4240-4262. Available at: http://www.ncbi.nlm.nih.gov/pubmed/19750567.

87. Mann DV, Edwards R, Ho S, et al. Elevated tumour marker CA19-9: clinical interpretation and influence of obstructive jaundice. Eur J Surg Oncol 2000;26:474-479. Available at: http://www.ncbi.nlm.nih.gov/pubmed/11016469.

88. Hwang JP, Feld JJ, Hammond SP, et al. Hepatitis B virus screening and management for patients with cancer prior to therapy: ASCO provisional clinical opinion update. J Clin Oncol 2020;38:3698-3715. Available at: https://ascopubs.org/doi/pdf/10.1200/JCO.20.01757.

89. Fowler KJ, Potretzke TA, Hope TA, et al. LI-RADS M (LR-M): definite or probable malignancy, not specific for hepatocellular carcinoma. Abdom Radiol (NY) 2018;43:149-157. Available at: https://www.ncbi.nlm.nih.gov/pubmed/28580538.

90. Heimbach JK, Sanchez W, Rosen CB, Gores GJ. Trans-peritoneal fine needle aspiration biopsy of hilar cholangiocarcinoma is associated with disease dissemination. HPB (Oxford) 2011;13:356-360. Available at: https://www.ncbi.nlm.nih.gov/pubmed/21492336.

91. Corvera CU, Blumgart LH, Darvishian F, et al. Clinical and pathologic features of proximal biliary strictures masquerading as hilar cholangiocarcinoma. J Am Coll Surg 2005;201:862-869. Available at: https://www.ncbi.nlm.nih.gov/pubmed/16310689.

92. Sainani NI, Catalano OA, Holalkere NS, et al. Cholangiocarcinoma: current and novel imaging techniques. Radiographics 2008;28:1263-1287. Available at: http://www.ncbi.nlm.nih.gov/pubmed/18794305.

93. Zhang H, Zhu J, Ke F, et al. Radiological imaging for assessing the respectability of hilar cholangiocarcinoma: a systematic review and meta-analysis. Biomed Res Int 2015;2015:497942. Available at: https://www.ncbi.nlm.nih.gov/pubmed/26448940.

94. Carpizo DR, D'Angelica M. Management and extent of resection for intrahepatic cholangiocarcinoma. Surg Oncol Clin N Am 2009;18:289-305, viii-ix. Available at: http://www.ncbi.nlm.nih.gov/pubmed/19306813.

95. Kierans AS, Costello J, Qayyum A, et al. Imaging cholangiocarcinoma: CT and MRI techniques. Abdom Radiol (NY) 2025;50:94-108. Available at: https://www.ncbi.nlm.nih.gov/pubmed/38916614.

96. ACR-SAR-SPR practice parameter for the performance of magnetic resonance (MR) enterography. 2020. Available at: https://www.acr.org/-/media/ACR/Files/Practice-Parameters/MR-Liver.pdf. Accessed October 4, 2022.

97. Zaydfudim VM, Wang AY, de Lange EE, et al. IgG4-associated cholangitis can mimic hilar cholangiocarcinoma. Gut Liver 2015;9:556-560. Available at: https://www.ncbi.nlm.nih.gov/pubmed/26033685.

98. Oh HC, Kim MH, Lee KT, et al. Clinical clues to suspicion of IgG4-associated sclerosing cholangitis disguised as primary sclerosing cholangitis or hilar cholangiocarcinoma. J Gastroenterol Hepatol 2010;25:1831-1837. Available at: https://www.ncbi.nlm.nih.gov/pubmed/21091993.

99. Oseini AM, Chaiteerakij R, Shire AM, et al. Utility of serum immunoglobulin G4 in distinguishing immunoglobulin G4-associated

Discussion update in progress

Version 1.2026 © 2026 National Comprehensive Cancer Network© (NCCN©), All rights reserved. NCCN Guidelines® and this illustration may not be reproduced in any form without the express written permission of NCCN.

PLEASE NOTE that use of this NCCN Content is governed by the End-User License Agreement, and you MAY NOT distribute this Content or use it with any artificial intelligence model or tool.
Printed by Máximo López Chenlo on 5/4/2026 6:13:37 PM. Copyright © 2026 National Comprehensive Cancer Network, Inc. All Rights Reserved.

cholangitis from cholangiocarcinoma. Hepatology 2011;54:940-948. Available at: https://www.ncbi.nlm.nih.gov/pubmed/21674559.

100. Xu WL, Ling YC, Wang ZK, Deng F. Diagnostic performance of serum IgG4 level for IgG4-related disease: a meta-analysis. Sci Rep 2016;6:32035. Available at: https://www.ncbi.nlm.nih.gov/pubmed/27558881.

101. Halefoglu AM. Magnetic resonance cholangiopancreatography: a useful tool in the evaluation of pancreatic and biliary disorders. World J Gastroenterol 2007;13:2529-2534. Available at: http://www.ncbi.nlm.nih.gov/pubmed/17551999.

102. Hekimoglu K, Ustundag Y, Dusak A, et al. MRCP vs. ERCP in the evaluation of biliary pathologies: review of current literature. J Dig Dis 2008;9:162-169. Available at: http://www.ncbi.nlm.nih.gov/pubmed/18956595.

103. Vogl TJ, Schwarz WO, Heller M, et al. Staging of Klatskin tumours (hilar cholangiocarcinomas): comparison of MR cholangiography, MR imaging, and endoscopic retrograde cholangiography. Eur Radiol 2006;16:2317-2325. Available at: http://www.ncbi.nlm.nih.gov/pubmed/16622690.

104. Hyodo T, Kumano S, Kushihata F, et al. CT and MR cholangiography: advantages and pitfalls in perioperative evaluation of biliary tree. Br J Radiol 2012;85:887-896. Available at: http://www.ncbi.nlm.nih.gov/pubmed/22422383.

105. Kim JY, Kim M-H, Lee TY, et al. Clinical role of 18F-FDG PET-CT in suspected and potentially operable cholangiocarcinoma: a prospective study compared with conventional imaging. Am J Gastroenterol 2008;103:1145-1151. Available at: http://www.ncbi.nlm.nih.gov/pubmed/18177454.

106. Ruys AT, Bennink RJ, van Westreenen HL, et al. FDG-positron emission tomography/computed tomography and standardized uptake value in the primary diagnosis and staging of hilar cholangiocarcinoma. HPB (Oxford) 2011;13:256-262. Available at: http://www.ncbi.nlm.nih.gov/pubmed/21418131.

107. Nakagohri T, Asano T, Kinoshita H, et al. Aggressive surgical resection for hilar-invasive and peripheral intrahepatic cholangiocarcinoma. World J Surg 2003;27:289-293. Available at: http://www.ncbi.nlm.nih.gov/pubmed/12607053.

108. Konstadoulakis MM, Roayaie S, Gomatos IP, et al. Fifteen-year, single-center experience with the surgical management of intrahepatic cholangiocarcinoma: operative results and long-term outcome. Surgery 2008;143:366-374. Available at: http://www.ncbi.nlm.nih.gov/pubmed/18291258.

109. Paik KY, Jung JC, Heo JS, et al. What prognostic factors are important for resected intrahepatic cholangiocarcinoma? J Gastroenterol Hepatol 2008;23:766-770. Available at: http://www.ncbi.nlm.nih.gov/pubmed/17868336.

110. Lang H, Sotiropoulos GC, Sgourakis G, et al. Operations for intrahepatic cholangiocarcinoma: single-institution experience of 158 patients. J Am Coll Surg 2009;208:218-228. Available at: http://www.ncbi.nlm.nih.gov/pubmed/19228533.

111. Murakami Y, Uemura K, Sudo T, et al. Prognostic factors after surgical resection for intrahepatic, hilar, and distal cholangiocarcinoma. Ann Surg Oncol 2011;18:651-658. Available at: http://www.ncbi.nlm.nih.gov/pubmed/20945107.

112. Ribero D, Pinna AD, Guglielmi A, et al. Surgical approach for long-term survival of patients with intrahepatic cholangiocarcinoma: a multi-institutional analysis of 434 patients. Arch Surg 2012;147:1107-1113. Available at: http://www.ncbi.nlm.nih.gov/pubmed/22910846.

113. Tamandl D, Herberger B, Gruenberger B, et al. Influence of hepatic resection margin on recurrence and survival in intrahepatic cholangiocarcinoma. Ann Surg Oncol 2008;15:2787-2794. Available at: http://www.ncbi.nlm.nih.gov/pubmed/18685896.

Discussion update in progress

Version 1.2026 © 2026 National Comprehensive Cancer Network© (NCCN©), All rights reserved. NCCN Guidelines® and this illustration may not be reproduced in any form without the express written permission of NCCN.

PLEASE NOTE that use of this NCCN Content is governed by the End-User License Agreement, and you MAY NOT distribute this Content or use it with any artificial intelligence model or tool.
Printed by Máximo López Chenlo on 5/4/2026 6:13:37 PM. Copyright © 2026 National Comprehensive Cancer Network, Inc. All Rights Reserved.

114. Farges O, Fuks D, Boleslawski E, et al. Influence of surgical margins on outcome in patients with intrahepatic cholangiocarcinoma: a multicenter study by the AFC-IHCC-2009 study group. Ann Surg 2011;254:824-829; discussion 830. Available at: http://www.ncbi.nlm.nih.gov/pubmed/22042474.

115. Spolverato G, Kim Y, Ejaz A, et al. Conditional probability of long-term survival after liver resection for intrahepatic cholangiocarcinoma: a multi-institutional analysis of 535 patients. JAMA Surg 2015;150:538-545. Available at: https://www.ncbi.nlm.nih.gov/pubmed/25831462.

116. Sutton TL, Billingsley KG, Walker BS, et al. Detection of tumor multifocality in resectable intrahepatic cholangiocarcinoma: Defining the optimal pre-operative imaging modality. J Gastrointest Surg 2021;25:2250-2257. Available at: https://www.ncbi.nlm.nih.gov/pubmed/33565011.

117. Ziogas IA, Esagian SM, Giannis D, et al. Laparoscopic versus open hepatectomy for intrahepatic cholangiocarcinoma: An individual patient data survival meta-analysis. Am J Surg 2021;222:731-738. Available at: https://www.ncbi.nlm.nih.gov/pubmed/33840443.

118. Owen ML, Beal EW. Minimally invasive surgery for intrahepatic cholangiocarcinoma: Patient selection and special considerations. Hepat Med 2021;13:137-143. Available at: https://www.ncbi.nlm.nih.gov/pubmed/35221734.

119. Goere D, Wagholikar GD, Pessaux P, et al. Utility of staging laparoscopy in subsets of biliary cancers : laparoscopy is a powerful diagnostic tool in patients with intrahepatic and gallbladder carcinoma. Surg Endosc 2006;20:721-725. Available at: http://www.ncbi.nlm.nih.gov/pubmed/16508808.

120. Joseph S, Connor S, Garden OJ. Staging laparoscopy for cholangiocarcinoma. HPB (Oxford) 2008;10:116-119. Available at: http://www.ncbi.nlm.nih.gov/pubmed/18773068.

121. Weber SM, Ribero D, O'Reilly EM, et al. Intrahepatic cholangiocarcinoma: expert consensus statement. HPB (Oxford) 2015;17:669-680. Available at: https://www.ncbi.nlm.nih.gov/pubmed/26172134.

122. Shimada M, Yamashita Y, Aishima S, et al. Value of lymph node dissection during resection of intrahepatic cholangiocarcinoma. Br J Surg 2001;88:1463-1466. Available at: http://www.ncbi.nlm.nih.gov/pubmed/11683741.

123. Choi S-B, Kim K-S, Choi J-Y, et al. The prognosis and survival outcome of intrahepatic cholangiocarcinoma following surgical resection: association of lymph node metastasis and lymph node dissection with survival. Ann Surg Oncol 2009;16:3048-3056. Available at: http://www.ncbi.nlm.nih.gov/pubmed/19626372.

124. Clark CJ, Wood-Wentz CM, Reid-Lombardo KM, et al. Lymphadenectomy in the staging and treatment of intrahepatic cholangiocarcinoma: a population-based study using the National Cancer Institute SEER database. HPB (Oxford) 2011;13:612-620. Available at: http://www.ncbi.nlm.nih.gov/pubmed/21843261.

125. Morine Y, Shimada M, Utsunomiya T, et al. Clinical impact of lymph node dissection in surgery for peripheral-type intrahepatic cholangiocarcinoma. Surg Today 2012;42:147-151. Available at: https://www.ncbi.nlm.nih.gov/pubmed/22124809.

126. Sutton TL, Billingsley KG, Walker BS, et al. Neoadjuvant chemotherapy is associated with improved survival in patients undergoing hepatic resection for intrahepatic cholangiocarcinoma. Am J Surg 2021;221:1182-1187. Available at: https://www.ncbi.nlm.nih.gov/pubmed/33707077.

127. Utuama O, Permuth JB, Dagne G, et al. Neoadjuvant chemotherapy for intrahepatic cholangiocarcinoma: A propensity score survival analysis supporting use in patients with high-risk disease. Ann Surg Oncol 2021;28:1939-1949. Available at: https://www.ncbi.nlm.nih.gov/pubmed/33415559.

128. Fisher SB, Patel SH, Kooby DA, et al. Lymphovascular and perineural invasion as selection criteria for adjuvant therapy in intrahepatic

Discussion update in progress

Version 1.2026 © 2026 National Comprehensive Cancer Network© (NCCN©), All rights reserved. NCCN Guidelines® and this illustration may not be reproduced in any form without the express written permission of NCCN.

PLEASE NOTE that use of this NCCN Content is governed by the End-User License Agreement, and you MAY NOT distribute this Content or use it with any artificial intelligence model or tool.
Printed by Máximo López Chenlo on 5/4/2026 6:13:37 PM. Copyright © 2026 National Comprehensive Cancer Network, Inc. All Rights Reserved.

cholangiocarcinoma: a multi-institution analysis. HPB (Oxford) 2012;14:514-522. Available at: http://www.ncbi.nlm.nih.gov/pubmed/22762399.

129. Hyder O, Hatzaras I, Sotiropoulos GC, et al. Recurrence after operative management of intrahepatic cholangiocarcinoma. Surgery 2013;153:811-818. Available at: http://www.ncbi.nlm.nih.gov/pubmed/23499016.

130. Sapisochin G, Facciuto M, Rubbia-Brandt L, et al. Liver transplantation for "very early" intrahepatic cholangiocarcinoma: International retrospective study supporting a prospective assessment. Hepatology 2016;64:1178-1188. Available at: https://www.ncbi.nlm.nih.gov/pubmed/27481548.

131. Huang G, Song W, Zhang Y, et al. Liver transplantation for intrahepatic cholangiocarcinoma: A propensity score-matched analysis. Sci Rep 2023;13:10630. Available at: https://www.ncbi.nlm.nih.gov/pubmed/37391482.

132. Lunsford KE, Javle M, Heyne K, et al. Liver transplantation for locally advanced intrahepatic cholangiocarcinoma treated with neoadjuvant therapy: A prospective case-series. Lancet Gastroenterol Hepatol 2018;3:337-348. Available at: https://www.ncbi.nlm.nih.gov/pubmed/29548617.

133. Guidance to liver transplant programs and the National Liver Review Board for: Adult MELD exceptions for transplant oncology. 2025. Available at: https://optn.transplant.hrsa.gov/media/xpdfswdv/nlrb-guidance_adult-transplant-oncology_feb-2025.pdf. Accessed March 10, 2025.

134. Bridgewater J, Galle PR, Khan SA, et al. Guidelines for the diagnosis and management of intrahepatic cholangiocarcinoma. J Hepatol 2014;60:1268-1289. Available at: https://www.ncbi.nlm.nih.gov/pubmed/24681130.

135. Carrafiello G, Lagana D, Cotta E, et al. Radiofrequency ablation of intrahepatic cholangiocarcinoma: preliminary experience. Cardiovasc Intervent Radiol 2010;33:835-839. Available at: http://www.ncbi.nlm.nih.gov/pubmed/20411389.

136. Kim JH, Won HJ, Shin YM, et al. Radiofrequency ablation for the treatment of primary intrahepatic cholangiocarcinoma. AJR Am J Roentgenol 2011;196:W205-209. Available at: http://www.ncbi.nlm.nih.gov/pubmed/21257864.

137. Kiefer MV, Albert M, McNally M, et al. Chemoembolization of intrahepatic cholangiocarcinoma with cisplatinum, doxorubicin, mitomycin C, ethiodol, and polyvinyl alcohol: a 2-center study. Cancer 2011;117:1498-1505. Available at: http://www.ncbi.nlm.nih.gov/pubmed/21425151.

138. Kuhlmann JB, Euringer W, Spangenberg HC, et al. Treatment of unresectable cholangiocarcinoma: conventional transarterial chemoembolization compared with drug eluting bead-transarterial chemoembolization and systemic chemotherapy. Eur J Gastroenterol Hepatol 2012;24:437-443. Available at: http://www.ncbi.nlm.nih.gov/pubmed/22261548.

139. Hyder O, Marsh JW, Salem R, et al. Intra-arterial therapy for advanced intrahepatic cholangiocarcinoma: a multi-institutional analysis. Ann Surg Oncol 2013;20:3779-3786. Available at: http://www.ncbi.nlm.nih.gov/pubmed/23846786.

140. Poggi G, Quaretti P, Minoia C, et al. Transhepatic arterial chemoembolization with oxaliplatin-eluting microspheres (OEM-TACE) for unresectable hepatic tumors. Anticancer Res 2008;28:3835-3842. Available at: http://www.ncbi.nlm.nih.gov/pubmed/19192637.

141. Schiffman SC, Metzger T, Dubel G, et al. Precision hepatic arterial irinotecan therapy in the treatment of unresectable intrahepatic cholangiocellular carcinoma: optimal tolerance and prolonged overall survival. Ann Surg Oncol 2011;18:431-438. Available at: http://www.ncbi.nlm.nih.gov/pubmed/20862554.

142. Ibrahim SM, Mulcahy MF, Lewandowski RJ, et al. Treatment of unresectable cholangiocarcinoma using yttrium-90 microspheres: results

Discussion update in progress

Version 1.2026 © 2026 National Comprehensive Cancer Network© (NCCN©), All rights reserved. NCCN Guidelines® and this illustration may not be reproduced in any form without the express written permission of NCCN.

PLEASE NOTE that use of this NCCN Content is governed by the End-User License Agreement, and you MAY NOT distribute this Content or use it with any artificial intelligence model or tool.
Printed by Máximo López Chenlo on 5/4/2026 6:13:37 PM. Copyright © 2026 National Comprehensive Cancer Network, Inc. All Rights Reserved.

from a pilot study. Cancer 2008;113:2119-2128. Available at: http://www.ncbi.nlm.nih.gov/pubmed/18759346.

143. Saxena A, Bester L, Chua TC, et al. Yttrium-90 radiotherapy for unresectable intrahepatic cholangiocarcinoma: a preliminary assessment of this novel treatment option. Ann Surg Oncol 2010;17:484-491. Available at: http://www.ncbi.nlm.nih.gov/pubmed/19876691.

144. Wijlemans JW, Van Erpecum KJ, Lam MG, et al. Trans-arterial (90)yttrium radioembolization for patients with unresectable tumors originating from the biliary tree. Ann Hepatol 2011;10:349-354. Available at: http://www.ncbi.nlm.nih.gov/pubmed/21677339.

145. Hoffmann R-T, Paprottka PM, Schon A, et al. Transarterial hepatic yttrium-90 radioembolization in patients with unresectable intrahepatic cholangiocarcinoma: factors associated with prolonged survival. Cardiovasc Intervent Radiol 2012;35:105-116. Available at: http://www.ncbi.nlm.nih.gov/pubmed/21431970.

146. Rafi S, Piduru SM, El-Rayes B, et al. Yttrium-90 radioembolization for unresectable standard-chemorefractory intrahepatic cholangiocarcinoma: survival, efficacy, and safety study. Cardiovasc Intervent Radiol 2013;36:440-448. Available at: http://www.ncbi.nlm.nih.gov/pubmed/22956045.

147. Mouli S, Memon K, Baker T, et al. Yttrium-90 radioembolization for intrahepatic cholangiocarcinoma: safety, response, and survival analysis. J Vasc Interv Radiol 2013;24:1227-1234. Available at: http://www.ncbi.nlm.nih.gov/pubmed/23602420.

148. Kim GH, Kim PH, Kim JH, et al. Thermal ablation in the treatment of intrahepatic cholangiocarcinoma: A systematic review and meta-analysis. Eur Radiol 2022;32:1205-1215. Available at: https://www.ncbi.nlm.nih.gov/pubmed/34347159.

149. Edeline J, Lamarca A, McNamara MG, et al. Locoregional therapies in patients with intrahepatic cholangiocarcinoma: A systematic review and pooled analysis. Cancer Treat Rev 2021;99:102258. Available at: https://www.ncbi.nlm.nih.gov/pubmed/34252720.

150. Han K, Ko HK, Kim KW, et al. Radiofrequency ablation in the treatment of unresectable intrahepatic cholangiocarcinoma: Systematic review and meta-analysis. J Vasc Interv Radiol 2015;26:943-948. Available at: https://www.ncbi.nlm.nih.gov/pubmed/25899049.

151. Edeline J, Touchefeu Y, Guiu B, et al. Radioembolization plus chemotherapy for first-line treatment of locally advanced intrahepatic cholangiocarcinoma: A phase 2 clinical trial. JAMA Oncol 2020;6:51-59. Available at: https://www.ncbi.nlm.nih.gov/pubmed/31670746.

152. Ahmed O, Yu Q, Patel M, et al. Yttrium-90 radioembolization and concomitant systemic gemcitabine, cisplatin, and capecitabine as the first-line therapy for locally advanced intrahepatic cholangiocarcinoma. J Vasc Interv Radiol 2023;34:702-709. Available at: https://www.ncbi.nlm.nih.gov/pubmed/36521794.

153. Al-Adra DP, Gill RS, Axford SJ, et al. Treatment of unresectable intrahepatic cholangiocarcinoma with yttrium-90 radioembolization: a systematic review and pooled analysis. Eur J Surg Oncol 2015;41:120-127. Available at: https://www.ncbi.nlm.nih.gov/pubmed/25449754.

154. Schartz DA, Porter M, Schartz E, et al. Transarterial yttrium-90 radioembolization for unresectable intrahepatic cholangiocarcinoma: A systematic review and meta-analysis. J Vasc Interv Radiol 2022;33:679-686. Available at: https://www.ncbi.nlm.nih.gov/pubmed/35219834.

155. Paz-Fumagalli R, Core J, Padula C, et al. Safety and initial efficacy of ablative radioembolization for the treatment of unresectable intrahepatic cholangiocarcinoma. Oncotarget 2021;12:2075-2088. Available at: https://www.ncbi.nlm.nih.gov/pubmed/34611481.

156. Robinson TJ, Du L, Matsuoka L, et al. Survival and toxicities after yttrium-90 transarterial radioembolization of cholangiocarcinoma in the RESiN registry. J Vasc Interv Radiol 2023;34:694-701 e693. Available at: https://www.ncbi.nlm.nih.gov/pubmed/36509236.

157. Shinohara ET, Mitra N, Guo M, Metz JM. Radiation therapy is associated with improved survival in the adjuvant and definitive treatment of intrahepatic cholangiocarcinoma. Int J Radiat Oncol Biol Phys

Discussion update in progress

Version 1.2026 © 2026 National Comprehensive Cancer Network© (NCCN©), All rights reserved. NCCN Guidelines® and this illustration may not be reproduced in any form without the express written permission of NCCN.

PLEASE NOTE that use of this NCCN Content is governed by the End-User License Agreement, and you MAY NOT distribute this Content or use it with any artificial intelligence model or tool.
Printed by Máximo López Chenlo on 5/4/2026 6:13:37 PM. Copyright © 2026 National Comprehensive Cancer Network, Inc. All Rights Reserved.

2008;72:1495-1501. Available at: http://www.ncbi.nlm.nih.gov/pubmed/18472359.

158. Tao R, Krishnan S, Bhosale PR, et al. Ablative radiotherapy doses lead to a substantial prolongation of survival in patients with inoperable intrahepatic cholangiocarcinoma: a retrospective dose response analysis. J Clin Oncol 2016;34:219-226. Available at: https://www.ncbi.nlm.nih.gov/pubmed/26503201.

159. De B, Tran Cao HS, Vauthey JN, et al. Ablative liver radiotherapy for unresected intrahepatic cholangiocarcinoma: Patterns of care and survival in the United States. Cancer 2022;128:2529-2539. Available at: https://www.ncbi.nlm.nih.gov/pubmed/35417569.

160. Tse RV, Hawkins M, Lockwood G, et al. Phase I study of individualized stereotactic body radiotherapy for hepatocellular carcinoma and intrahepatic cholangiocarcinoma. J Clin Oncol 2008;26:657-664. Available at: http://www.ncbi.nlm.nih.gov/pubmed/18172187.

161. Hong TS, Wo JY, Yeap BY, et al. Multi-institutional phase II study of high-dose hypofractionated proton beam therapy in patients with localized, unresectable hepatocellular carcinoma and intrahepatic cholangiocarcinoma. J Clin Oncol 2016;34:460-468. Available at: https://www.ncbi.nlm.nih.gov/pubmed/26668346.

162. Parzen JS, Hartsell W, Chang J, et al. Hypofractionated proton beam radiotherapy in patients with unresectable liver tumors: Multi-institutional prospective results from the Proton Collaborative Group. Radiat Oncol 2020;15:255. Available at: https://www.ncbi.nlm.nih.gov/pubmed/33148296.

163. Apisarnthanarax S, Barry A, Cao M, et al. External beam radiation therapy for primary liver cancers: An ASTRO Clinical Practice Guideline. Pract Radiat Oncol 2022;12:28-51. Available at: https://www.ncbi.nlm.nih.gov/pubmed/34688956.

164. Ben-Josef E, Guthrie KA, El-Khoueiry AB, et al. SWOG S0809: a phase II intergroup trial of adjuvant capecitabine and gemcitabine followed by radiotherapy and concurrent capecitabine in extrahepatic cholangiocarcinoma and gallbladder carcinoma. J Clin Oncol 2015;33:2617-2622. Available at: http://www.ncbi.nlm.nih.gov/pubmed/25964250.

165. Wang SJ, Lemieux A, Kalpathy-Cramer J, et al. Nomogram for predicting the benefit of adjuvant chemoradiotherapy for resected gallbladder cancer. J Clin Oncol 2011;29:4627-4632. Available at: http://www.ncbi.nlm.nih.gov/pubmed/22067404.

166. Mallick S, Benson R, Haresh KP, et al. Adjuvant radiotherapy in the treatment of gall bladder carcinoma: What is the current evidence. J Egypt Natl Canc Inst 2016;28:1-6. Available at: https://www.ncbi.nlm.nih.gov/pubmed/26265290.

167. Jeong Y, Park JH, Lee YJ, et al. Postoperative radiotherapy for gallbladder cancer. Anticancer Res 2014;34:5621-5629. Available at: https://www.ncbi.nlm.nih.gov/pubmed/25275065.

168. Fukuda K, Okumura T, Abei M, et al. Long-term outcomes of proton beam therapy in patients with previously untreated hepatocellular carcinoma. Cancer Sci 2017;108:497-503. Available at: https://www.ncbi.nlm.nih.gov/pubmed/28012214.

169. Kim TH, Koh YH, Kim BH, et al. Proton beam radiotherapy vs. radiofrequency ablation for recurrent hepatocellular carcinoma: A randomized phase III trial. J Hepatol 2021;74:603-612. Available at: https://www.ncbi.nlm.nih.gov/pubmed/33031846.

170. Bowlus CL, Arrive L, Bergquist A, et al. AASLD practice guidance on primary sclerosing cholangitis and cholangiocarcinoma. Hepatology 2023;77:659-702. Available at: https://www.ncbi.nlm.nih.gov/pubmed/36083140.

171. Mambrini A, Guglielmi A, Pacetti P, et al. Capecitabine plus hepatic intra-arterial epirubicin and cisplatin in unresectable biliary cancer: a phase II study. Anticancer Res 2007;27:3009-3013. Available at: http://www.ncbi.nlm.nih.gov/pubmed/17695488.

Discussion update in progress

Version 1.2026 © 2026 National Comprehensive Cancer Network© (NCCN©), All rights reserved. NCCN Guidelines® and this illustration may not be reproduced in any form without the express written permission of NCCN.

PLEASE NOTE that use of this NCCN Content is governed by the End-User License Agreement, and you MAY NOT distribute this Content or use it with any artificial intelligence model or tool.
Printed by Máximo López Chenlo on 5/4/2026 6:13:37 PM. Copyright © 2026 National Comprehensive Cancer Network, Inc. All Rights Reserved.

172. Inaba Y, Arai Y, Yamaura H, et al. Phase I/II study of hepatic arterial infusion chemotherapy with gemcitabine in patients with unresectable intrahepatic cholangiocarcinoma (JIVROSG-0301). Am J Clin Oncol 2011;34:58-62. Available at: http://www.ncbi.nlm.nih.gov/pubmed/20177362.

173. Kemeny NE, Schwartz L, Gonen M, et al. Treating primary liver cancer with hepatic arterial infusion of floxuridine and dexamethasone: does the addition of systemic bevacizumab improve results? Oncology 2011;80:153-159. Available at: http://www.ncbi.nlm.nih.gov/pubmed/21677464.

174. Jarnagin WR, Schwartz LH, Gultekin DH, et al. Regional chemotherapy for unresectable primary liver cancer: results of a phase II clinical trial and assessment of DCE-MRI as a biomarker of survival. Ann Oncol 2009;20:1589-1595. Available at: https://www.ncbi.nlm.nih.gov/pubmed/19491285.

175. Konstantinidis IT, Do RK, Gultekin DH, et al. Regional chemotherapy for unresectable intrahepatic cholangiocarcinoma: a potential role for dynamic magnetic resonance imaging as an imaging biomarker and a survival update from two prospective clinical trials. Ann Surg Oncol 2014;21:2675-2683. Available at: https://www.ncbi.nlm.nih.gov/pubmed/24664624.

176. Cercek A, Boerner T, Tan BR, et al. Assessment of hepatic arterial infusion of floxuridine in combination with systemic gemcitabine and oxaliplatin in patients with unresectable intrahepatic cholangiocarcinoma: A phase 2 clinical trial. JAMA Oncol 2020;6:60-67. Available at: https://www.ncbi.nlm.nih.gov/pubmed/31670750.

177. Franssen S, Rousian M, Nooijen LE, et al. Hepatic arterial infusion pump chemotherapy in patients with advanced intrahepatic cholangiocarcinoma confined to the liver: A multicenter phase II trial [abstract]. J Clin Oncol 2024;42:Abstract 433. Available at: https://ascopubs.org/doi/abs/10.1200/JCO.2024.42.3_suppl.433.

178. Boehm LM, Jayakrishnan TT, Miura JT, et al. Comparative effectiveness of hepatic artery based therapies for unresectable intrahepatic cholangiocarcinoma. J Surg Oncol 2015;111:213-220. Available at: https://www.ncbi.nlm.nih.gov/pubmed/25176325.

179. Konstantinidis IT, Groot Koerkamp B, Do RK, et al. Unresectable intrahepatic cholangiocarcinoma: Systemic plus hepatic arterial infusion chemotherapy is associated with longer survival in comparison with systemic chemotherapy alone. Cancer 2016;122:758-765. Available at: https://www.ncbi.nlm.nih.gov/pubmed/26695839.

180. Yang Z, Fu Y, Wu W, et al. Comparison of hepatic arterial infusion chemotherapy with mFOLFOX vs. first-line systemic chemotherapy in patients with unresectable intrahepatic cholangiocarcinoma. Front Pharmacol 2023;14:1234342. Available at: https://www.ncbi.nlm.nih.gov/pubmed/37731737.

181. Childs A, Zakeri N, Ma YT, et al. Biopsy for advanced hepatocellular carcinoma: Results of a multicentre UK audit. Br J Cancer 2021;125:1350-1355. Available at: https://www.ncbi.nlm.nih.gov/pubmed/34526664.

182. Teufel A, Rodriguez I, Winzler C, et al. Clinical characterization of HCC/CCA mixed cancers in a population-based cohort. J Gastrointestin Liver Dis 2023;32:190-196. Available at: https://www.ncbi.nlm.nih.gov/pubmed/37345609.

183. Raevskaya O, Appelman H, Razumilava N. A contemporary approach to diagnosis and treatment of combined hepatocellular-cholangiocarcinoma. Curr Hepatol Rep 2020;19:478-485. Available at: https://www.ncbi.nlm.nih.gov/pubmed/33415066.

184. Tang Y, Wang L, Teng F, et al. The clinical characteristics and prognostic factors of combined hepatocellular carcinoma and cholangiocarcinoma, hepatocellular carcinoma and intrahepatic cholangiocarcinoma after surgical resection: A propensity score matching analysis. Int J Med Sci 2021;18:187-198. Available at: https://www.ncbi.nlm.nih.gov/pubmed/33390787.

185. Claasen M, Ivanics T, Beumer BR, et al. An international multicentre evaluation of treatment strategies for combined hepatocellular-

Discussion update in progress

Version 1.2026 © 2026 National Comprehensive Cancer Network© (NCCN©), All rights reserved. NCCN Guidelines® and this illustration may not be reproduced in any form without the express written permission of NCCN.

PLEASE NOTE that use of this NCCN Content is governed by the End-User License Agreement, and you MAY NOT distribute this Content or use it with any artificial intelligence model or tool.
Printed by Máximo López Chenlo on 5/4/2026 6:13:37 PM. Copyright © 2026 National Comprehensive Cancer Network, Inc. All Rights Reserved.

cholangiocarcinoma. JHEP Rep 2023;5:100745. Available at: https://www.ncbi.nlm.nih.gov/pubmed/37234277.

186. Pomej K, Balcar L, Shmanko K, et al. Clinical characteristics and outcome of patients with combined hepatocellular-cholangiocarcinoma-a European multicenter cohort. ESMO Open 2023;8:100783. Available at: https://www.ncbi.nlm.nih.gov/pubmed/36753993.

187. Kelley RK, Ueno M, Yoo C, et al. Pembrolizumab in combination with gemcitabine and cisplatin compared with gemcitabine and cisplatin alone for patients with advanced biliary tract cancer (KEYNOTE-966): A randomised, double-blind, placebo-controlled, phase 3 trial. Lancet 2023;401:1853-1865. Available at: https://www.ncbi.nlm.nih.gov/pubmed/37075781.

188. Oh DY, Ruth He A, Qin S, et al. Durvalumab plus gemcitabine and cisplatin in advanced biliary tract cancer. NEJM Evid 2022;1:EVID0a2200015. Available at: https://pubmed.ncbi.nlm.nih.gov/38319896/.

189. Valle J, Wasan H, Palmer DH, et al. Cisplatin plus gemcitabine versus gemcitabine for biliary tract cancer. N Engl J Med 2010;362:1273-1281. Available at: http://www.ncbi.nlm.nih.gov/pubmed/20375404.

190. Abou-Alfa GK, Lau G, Kudo M, et al. Tremelimumab plus durvalumab in unresectable hepatocellular carcinoma. NEJM Evid 2022;1:EVIDoa2100070. Available at: https://pubmed.ncbi.nlm.nih.gov/38319892/.

191. Finn RS, Ryoo BY, Merle P, et al. Pembrolizumab as second-line therapy in patients with advanced hepatocellular carcinoma in KEYNOTE-240: A randomized, double-blind, phase III trial. J Clin Oncol 2020;38:193-202. Available at: https://www.ncbi.nlm.nih.gov/pubmed/31790344.

192. Qin S, Chen Z, Fang W, et al. Pembrolizumab versus placebo as second-line therapy in patients from Asia with advanced hepatocellular carcinoma: A randomized, double-blind, phase III trial. J Clin Oncol 2023;41:1434-1443. Available at: https://www.ncbi.nlm.nih.gov/pubmed/36455168.

193. Zhu AX, Finn RS, Edeline J, et al. Pembrolizumab in patients with advanced hepatocellular carcinoma previously treated with sorafenib (KEYNOTE-224): a non-randomised, open-label phase 2 trial. Lancet Oncol 2018;19:940-952. Available at: https://www.ncbi.nlm.nih.gov/pubmed/29875066.

194. Yau T, Kang YK, Kim TY, et al. Efficacy and safety of nivolumab plus ipilimumab in patients with advanced hepatocellular carcinoma previously treated with sorafenib: The CheckMate 040 randomized clinical trial. JAMA Oncol 2020;6:e204564. Available at: https://www.ncbi.nlm.nih.gov/pubmed/33001135.

195. Klein O, Kee D, Nagrial A, et al. Evaluation of combination nivolumab and ipilimumab immunotherapy in patients with advanced biliary tract cancers: Subgroup analysis of a phase 2 nonrandomized clinical trial. JAMA Oncol 2020;6:1405-1409. Available at: https://www.ncbi.nlm.nih.gov/pubmed/32729929.

196. Bruix J, Qin S, Merle P, et al. Regorafenib for patients with hepatocellular carcinoma who progressed on sorafenib treatment (RESORCE): a randomised, double-blind, placebo-controlled, phase 3 trial. Lancet 2017;389:56-66. Available at: https://www.ncbi.nlm.nih.gov/pubmed/27932229.

197. Sun W, Patel A, Normolle D, et al. A phase 2 trial of regorafenib as a single agent in patients with chemotherapy-refractory, advanced, and metastatic biliary tract adenocarcinoma. Cancer 2019;125:902-909. Available at: https://www.ncbi.nlm.nih.gov/pubmed/30561756.

198. Akamatsu N, Sugawara Y, Hashimoto D. Surgical strategy for bile duct cancer: Advances and current limitations. World J Clin Oncol 2011;2:94-107. Available at: http://www.ncbi.nlm.nih.gov/pubmed/21603318.

199. Nagino M, Ebata T, Yokoyama Y, et al. Evolution of surgical treatment for perihilar cholangiocarcinoma: a single-center 34-year review of 574 consecutive resections. Ann Surg 2013;258:129-140. Available at: https://www.ncbi.nlm.nih.gov/pubmed/23059502.

Discussion update in progress

Version 1.2026 © 2026 National Comprehensive Cancer Network© (NCCN©), All rights reserved. NCCN Guidelines® and this illustration may not be reproduced in any form without the express written permission of NCCN.

PLEASE NOTE that use of this NCCN Content is governed by the End-User License Agreement, and you MAY NOT distribute this Content or use it with any artificial intelligence model or tool.
Printed by Máximo López Chenlo on 5/4/2026 6:13:37 PM. Copyright © 2026 National Comprehensive Cancer Network, Inc. All Rights Reserved.

200. Qiao Q-L, Zhang T-P, Guo J-C, et al. Prognostic factors after pancreatoduodenectomy for distal bile duct cancer. Am Surg 2011;77:1445-1448. Available at: http://www.ncbi.nlm.nih.gov/pubmed/22196654.

201. Groot Koerkamp B, Wiggers JK, Gonen M, et al. Survival after resection of perihilar cholangiocarcinoma-development and external validation of a prognostic nomogram. Ann Oncol 2015;26:1930-1935. Available at: https://www.ncbi.nlm.nih.gov/pubmed/26133967.

202. Schwarz RE, Smith DD. Lymph node dissection impact on staging and survival of extrahepatic cholangiocarcinomas, based on U.S. population data. J Gastrointest Surg 2007;11:158-165. Available at: http://www.ncbi.nlm.nih.gov/pubmed/17390167.

203. Ito K, Ito H, Allen PJ, et al. Adequate lymph node assessment for extrahepatic bile duct adenocarcinoma. Ann Surg 2010;251:675-681. Available at: http://www.ncbi.nlm.nih.gov/pubmed/20224368.

204. Ota T, Araida T, Yamamoto M, Takasaki K. Operative outcome and problems of right hepatic lobectomy with pancreatoduodenectomy for advanced carcinoma of the biliary tract. J Hepatobiliary Pancreat Surg 2007;14:155-158. Available at: https://www.ncbi.nlm.nih.gov/pubmed/17384906.

205. Miwa S, Kobayashi A, Akahane Y, et al. Is major hepatectomy with pancreatoduodenectomy justified for advanced biliary malignancy? J Hepatobiliary Pancreat Surg 2007;14:136-141. Available at: https://www.ncbi.nlm.nih.gov/pubmed/17384903.

206. Ribero D, Zimmitti G, Aloia TA, et al. Preoperative cholangitis and future liver remnant volume determine the risk of liver failure in patients undergoing resection for hilar cholangiocarcinoma. J Am Coll Surg 2016;223:87-97. Available at: https://www.ncbi.nlm.nih.gov/pubmed/27049784.

207. Nishio H, Nagino M, Nimura Y. Surgical management of hilar cholangiocarcinoma: the Nagoya experience. HPB (Oxford) 2005;7:259-262. Available at: http://www.ncbi.nlm.nih.gov/pubmed/18333203.

208. Ito F, Agni R, Rettammel RJ, et al. Resection of hilar cholangiocarcinoma: concomitant liver resection decreases hepatic recurrence. Ann Surg 2008;248:273-279. Available at: http://www.ncbi.nlm.nih.gov/pubmed/18650638.

209. van Gulik TM, Kloek JJ, Ruys AT, et al. Multidisciplinary management of hilar cholangiocarcinoma (Klatskin tumor): extended resection is associated with improved survival. Eur J Surg Oncol 2011;37:65-71. Available at: http://www.ncbi.nlm.nih.gov/pubmed/21115233.

210. Cheng QB, Yi B, Wang JH, et al. Resection with total caudate lobectomy confers survival benefit in hilar cholangiocarcinoma of Bismuth type III and IV. Eur J Surg Oncol 2012;38:1197-1203. Available at: http://www.ncbi.nlm.nih.gov/pubmed/22992326.

211. Cho MS, Kim SH, Park SW, et al. Surgical outcomes and predicting factors of curative resection in patients with hilar cholangiocarcinoma: 10-year single-institution experience. J Gastrointest Surg 2012;16:1672-1679. Available at: http://www.ncbi.nlm.nih.gov/pubmed/22798185.

212. de Jong MC, Marques H, Clary BM, et al. The impact of portal vein resection on outcomes for hilar cholangiocarcinoma: a multi-institutional analysis of 305 cases. Cancer 2012;118:4737-4747. Available at: http://www.ncbi.nlm.nih.gov/pubmed/22415526.

213. Wu XS, Dong P, Gu J, et al. Combined portal vein resection for hilar cholangiocarcinoma: a meta-analysis of comparative studies. J Gastrointest Surg 2013;17:1107-1115. Available at: http://www.ncbi.nlm.nih.gov/pubmed/23592188.

214. Cho A, Yamamoto H, Kainuma O, et al. Laparoscopy in the management of hilar cholangiocarcinoma. World J Gastroenterol 2014;20:15153-15157. Available at: http://www.ncbi.nlm.nih.gov/pubmed/25386064.

215. Ruys AT, Busch OR, Gouma DJ, van Gulik TM. Staging laparoscopy for hilar cholangiocarcinoma: is it still worthwhile? Indian J Surg Oncol 2012;3:147-153. Available at: http://www.ncbi.nlm.nih.gov/pubmed/23728233.

Discussion update in progress

Version 1.2026 © 2026 National Comprehensive Cancer Network© (NCCN©), All rights reserved. NCCN Guidelines® and this illustration may not be reproduced in any form without the express written permission of NCCN.

PLEASE NOTE that use of this NCCN Content is governed by the End-User License Agreement, and you MAY NOT distribute this Content or use it with any artificial intelligence model or tool.
Printed by Máximo López Chenlo on 5/4/2026 6:13:37 PM. Copyright © 2026 National Comprehensive Cancer Network, Inc. All Rights Reserved.

216. Nimura Y. Preoperative biliary drainage before resection for cholangiocarcinoma (Pro). HPB (Oxford) 2008;10:130-133. Available at: http://www.ncbi.nlm.nih.gov/pubmed/18773090.

217. Kennedy TJ, Yopp A, Qin Y, et al. Role of preoperative biliary drainage of liver remnant prior to extended liver resection for hilar cholangiocarcinoma. HPB (Oxford) 2009;11:445-451. Available at: http://www.ncbi.nlm.nih.gov/pubmed/19768150.

218. Liu F, Li Y, Wei Y, Li B. Preoperative biliary drainage before resection for hilar cholangiocarcinoma: whether or not? A systematic review. Dig Dis Sci 2011;56:663-672. Available at: http://www.ncbi.nlm.nih.gov/pubmed/20635143.

219. Farges O, Regimbeau JM, Fuks D, et al. Multicentre European study of preoperative biliary drainage for hilar cholangiocarcinoma. Br J Surg 2013;100:274-283. Available at: http://www.ncbi.nlm.nih.gov/pubmed/23124720.

220. Abulkhir A, Limongelli P, Healey AJ, et al. Preoperative portal vein embolization for major liver resection: a meta-analysis. Ann Surg 2008;247:49-57. Available at: http://www.ncbi.nlm.nih.gov/pubmed/18156923.

221. Shindoh J, Vauthey J-N, Zimmitti G, et al. Analysis of the efficacy of portal vein embolization for patients with extensive liver malignancy and very low future liver remnant volume, including a comparison with the associating liver partition with portal vein ligation for staged hepatectomy approach. J Am Coll Surg 2013;217:126-133; discussion 133-134. Available at: http://www.ncbi.nlm.nih.gov/pubmed/23632095.

222. Davids PH, Groen AK, Rauws EA, et al. Randomised trial of self-expanding metal stents versus polyethylene stents for distal malignant biliary obstruction. Lancet 1992;340:1488-1492. Available at: http://www.ncbi.nlm.nih.gov/pubmed/1281903.

223. Prat F, Chapat O, Ducot B, et al. A randomized trial of endoscopic drainage methods for inoperable malignant strictures of the common bile duct. Gastrointest Endosc 1998;47:1-7. Available at: http://www.ncbi.nlm.nih.gov/pubmed/9468416.

224. Abraham NS, Barkun JS, Barkun AN. Palliation of malignant biliary obstruction: a prospective trial examining impact on quality of life. Gastrointest Endosc 2002;56:835-841. Available at: http://www.ncbi.nlm.nih.gov/pubmed/12447294.

225. Paik WH, Park YS, Hwang JH, et al. Palliative treatment with self-expandable metallic stents in patients with advanced type III or IV hilar cholangiocarcinoma: a percutaneous versus endoscopic approach. Gastrointest Endosc 2009;69:55-62. Available at: http://www.ncbi.nlm.nih.gov/pubmed/18657806.

226. Robles R, Figueras J, Turrion VS, et al. Spanish experience in liver transplantation for hilar and peripheral cholangiocarcinoma. Ann Surg 2004;239:265-271. Available at: http://www.ncbi.nlm.nih.gov/pubmed/14745336.

227. Becker NS, Rodriguez JA, Barshes NR, et al. Outcomes analysis for 280 patients with cholangiocarcinoma treated with liver transplantation over an 18-year period. J Gastrointest Surg 2008;12:117-122. Available at: http://www.ncbi.nlm.nih.gov/pubmed/17963015.

228. Kaiser GM, Sotiropoulos GC, Jauch KW, et al. Liver transplantation for hilar cholangiocarcinoma: a German survey. Transplant Proc 2008;40:3191-3193. Available at: http://www.ncbi.nlm.nih.gov/pubmed/19010230.

229. Friman S, Foss A, Isoniemi H, et al. Liver transplantation for cholangiocarcinoma: selection is essential for acceptable results. Scand J Gastroenterol 2011;46:370-375. Available at: http://www.ncbi.nlm.nih.gov/pubmed/21073376.

230. Darwish Murad S, Kim WR, Harnois DM, et al. Efficacy of neoadjuvant chemoradiation, followed by liver transplantation, for perihilar cholangiocarcinoma at 12 US centers. Gastroenterology 2012;143:88-98. Available at: http://www.ncbi.nlm.nih.gov/pubmed/22504095.

Discussion update in progress

Version 1.2026 © 2026 National Comprehensive Cancer Network© (NCCN©), All rights reserved. NCCN Guidelines® and this illustration may not be reproduced in any form without the express written permission of NCCN.

PLEASE NOTE that use of this NCCN Content is governed by the End-User License Agreement, and you MAY NOT distribute this Content or use it with any artificial intelligence model or tool.
Printed by Máximo López Chenlo on 5/4/2026 6:13:37 PM. Copyright © 2026 National Comprehensive Cancer Network, Inc. All Rights Reserved.

231. Panjala C, Nguyen JH, Al-Hajjaj AN, et al. Impact of neoadjuvant chemoradiation on the tumor burden before liver transplantation for unresectable cholangiocarcinoma. Liver Transpl 2012;18:594-601. Available at: http://www.ncbi.nlm.nih.gov/pubmed/22140024.

232. Duignan S, Maguire D, Ravichand CS, et al. Neoadjuvant chemoradiotherapy followed by liver transplantation for unresectable cholangiocarcinoma: a single-centre national experience. HPB (Oxford) 2013;16:91-98. Available at: http://www.ncbi.nlm.nih.gov/pubmed/23600750.

233. Rea DJ, Heimbach JK, Rosen CB, et al. Liver transplantation with neoadjuvant chemoradiation is more effective than resection for hilar cholangiocarcinoma. Ann Surg 2005;242:451-458. Available at: http://www.ncbi.nlm.nih.gov/pubmed/16135931.

234. Hong JC, Jones CM, Duffy JP, et al. Comparative analysis of resection and liver transplantation for intrahepatic and hilar cholangiocarcinoma: a 24-year experience in a single center. Arch Surg 2011;146:683-689. Available at: http://www.ncbi.nlm.nih.gov/pubmed/21690444.

235. Ortner MEJ, Caca K, Berr F, et al. Successful photodynamic therapy for nonresectable cholangiocarcinoma: a randomized prospective study. Gastroenterology 2003;125:1355-1363. Available at: http://www.ncbi.nlm.nih.gov/pubmed/14598251.

236. Zoepf T, Jakobs R, Arnold JC, et al. Palliation of nonresectable bile duct cancer: improved survival after photodynamic therapy. Am J Gastroenterol 2005;100:2426-2430. Available at: http://www.ncbi.nlm.nih.gov/pubmed/16279895.

237. Zhang XF, Beal EW, Bagante F, et al. Early versus late recurrence of intrahepatic cholangiocarcinoma after resection with curative intent. Br J Surg 2018;105:848-856. Available at: https://www.ncbi.nlm.nih.gov/pubmed/29193010.

238. Spolverato G, Kim Y, Alexandrescu S, et al. Management and outcomes of patients with recurrent intrahepatic cholangiocarcinoma following previous curative-intent surgical resection. Ann Surg Oncol 2016;23:235-243. Available at: https://www.ncbi.nlm.nih.gov/pubmed/26059651.

239. Cereda S, Belli C, Reni M. Adjuvant treatment in biliary tract cancer: to treat or not to treat? World J Gastroenterol 2012;18:2591-2596. Available at: http://www.ncbi.nlm.nih.gov/pubmed/22690066.

240. Primrose JN, Fox RP, Palmer DH, et al. Capecitabine compared with observation in resected biliary tract cancer (BILCAP): a randomised, controlled, multicentre, phase 3 study. Lancet Oncol 2019;20:663-673. Available at: https://www.ncbi.nlm.nih.gov/pubmed/30922733.

241. Bridgewater J, Fletcher P, Palmer DH, et al. Long-term outcomes and exploratory analyses of the randomized phase III BILCAP study. J Clin Oncol 2022;40:2048-2057. Available at: https://www.ncbi.nlm.nih.gov/pubmed/35316080.

242. Jeong H, Kim KP, Jeong JH, et al. Adjuvant gemcitabine plus cisplatin versus capecitabine in node-positive extrahepatic cholangiocarcinoma: The STAMP randomized trial. Hepatology 2023;77:1540-1549. Available at: https://www.ncbi.nlm.nih.gov/pubmed/37070950.

243. Takada T, Amano H, Yasuda H, et al. Is postoperative adjuvant chemotherapy useful for gallbladder carcinoma? A phase III multicenter prospective randomized controlled trial in patients with resected pancreaticobiliary carcinoma. Cancer 2002;95:1685-1695. Available at: http://www.ncbi.nlm.nih.gov/pubmed/12365016.

244. Nakachi K, Ikeda M, Konishi M, et al. Adjuvant S-1 compared with observation in resected biliary tract cancer (JCOG1202, ASCOT): A multicentre, open-label, randomised, controlled, phase 3 trial. Lancet 2023;401:195-203. Available at: https://www.ncbi.nlm.nih.gov/pubmed/36681415.

245. Edeline J, Benabdelghani M, Bertaut A, et al. Gemcitabine and oxaliplatin chemotherapy or surveillance in resected biliary tract cancer (PRODIGE 12-ACCORD 18-UNICANCER GI): a randomized phase III

Discussion update in progress

Version 1.2026 © 2026 National Comprehensive Cancer Network© (NCCN©), All rights reserved. NCCN Guidelines® and this illustration may not be reproduced in any form without the express written permission of NCCN.

PLEASE NOTE that use of this NCCN Content is governed by the End-User License Agreement, and you MAY NOT distribute this Content or use it with any artificial intelligence model or tool.
Printed by Máximo López Chenlo on 5/4/2026 6:13:37 PM. Copyright © 2026 National Comprehensive Cancer Network, Inc. All Rights Reserved.

study. J Clin Oncol 2019;37:658-667. Available at: https://www.ncbi.nlm.nih.gov/pubmed/30707660.

246. Ebata T, Hirano S, Konishi M, et al. Randomized clinical trial of adjuvant gemcitabine chemotherapy versus observation in resected bile duct cancer. Br J Surg 2018;105:192-202. Available at: https://www.ncbi.nlm.nih.gov/pubmed/29405274.

247. Jarnagin WR, Ruo L, Little SA, et al. Patterns of initial disease recurrence after resection of gallbladder carcinoma and hilar cholangiocarcinoma: implications for adjuvant therapeutic strategies. Cancer 2003;98:1689-1700. Available at: http://www.ncbi.nlm.nih.gov/pubmed/14534886.

248. Glazer ES, Liu P, Abdalla EK, et al. Neither neoadjuvant nor adjuvant therapy increases survival after biliary tract cancer resection with wide negative margins. J Gastrointest Surg 2012;16:1666-1671. Available at: http://www.ncbi.nlm.nih.gov/pubmed/22777053.

249. Tran Cao HS, Zhang Q, Sada YH, et al. The role of surgery and adjuvant therapy in lymph node-positive cancers of the gallbladder and intrahepatic bile ducts. Cancer 2018;124:74-83. Available at: https://www.ncbi.nlm.nih.gov/pubmed/28841223.

250. Horgan AM, Amir E, Walter T, Knox JJ. Adjuvant therapy in the treatment of biliary tract cancer: a systematic review and meta-analysis. J Clin Oncol 2012;30:1934-1940. Available at: http://www.ncbi.nlm.nih.gov/pubmed/22529261.

251. Rangarajan K, Simmons G, Manas D, et al. Systemic adjuvant chemotherapy for cholangiocarcinoma surgery: A systematic review and meta-analysis. Eur J Surg Oncol 2020;46:684-693. Available at: https://www.ncbi.nlm.nih.gov/pubmed/31761507.

252. Ren B, Guo Q, Yang Y, et al. A meta-analysis of the efficacy of postoperative adjuvant radiotherapy versus no radiotherapy for extrahepatic cholangiocarcinoma and gallbladder carcinoma. Radiat Oncol 2020;15:15. Available at: https://www.ncbi.nlm.nih.gov/pubmed/31941520.

253. Ma N, Cheng H, Qin B, et al. Adjuvant therapy in the treatment of gallbladder cancer: a meta-analysis. BMC Cancer 2015;15:615. Available at: https://www.ncbi.nlm.nih.gov/pubmed/26337466.

254. Gold DG, Miller RC, Haddock MG, et al. Adjuvant therapy for gallbladder carcinoma: the Mayo Clinic Experience. Int J Radiat Oncol Biol Phys 2009;75:150-155. Available at: http://www.ncbi.nlm.nih.gov/pubmed/19297105.

255. Cho SY, Kim SH, Park S-J, et al. Adjuvant chemoradiation therapy in gallbladder cancer. J Surg Oncol 2010;102:87-93. Available at: http://www.ncbi.nlm.nih.gov/pubmed/20578085.

256. Kim K, Chie EK, Jang JY, et al. Postoperative chemoradiotherapy for gallbladder cancer. Strahlenther Onkol 2012;188:388-392. Available at: http://www.ncbi.nlm.nih.gov/pubmed/22402869.

257. Kim Y, Amini N, Wilson A, et al. Impact of chemotherapy and external-beam radiation therapy on outcomes among patients with resected gallbladder cancer: a multi-institutional analysis. Ann Surg Oncol 2016;23:2998-3008. Available at: https://www.ncbi.nlm.nih.gov/pubmed/27169772.

258. Hughes MA, Frassica DA, Yeo CJ, et al. Adjuvant concurrent chemoradiation for adenocarcinoma of the distal common bile duct. Int J Radiat Oncol Biol Phys 2007;68:178-182. Available at: http://www.ncbi.nlm.nih.gov/pubmed/17276614.

259. Nelson JW, Ghafoori AP, Willett CG, et al. Concurrent chemoradiotherapy in resected extrahepatic cholangiocarcinoma. Int J Radiat Oncol Biol Phys 2009;73:148-153. Available at: http://www.ncbi.nlm.nih.gov/pubmed/18805651.

260. Lim KH, Oh DY, Chie EK, et al. Adjuvant concurrent chemoradiation therapy (CCRT) alone versus CCRT followed by adjuvant chemotherapy: which is better in patients with radically resected extrahepatic biliary tract cancer?: a non-randomized, single center study. BMC Cancer 2009;9:345. Available at: http://www.ncbi.nlm.nih.gov/pubmed/19781103.

Discussion update in progress

Version 1.2026 © 2026 National Comprehensive Cancer Network© (NCCN©), All rights reserved. NCCN Guidelines® and this illustration may not be reproduced in any form without the express written permission of NCCN.

PLEASE NOTE that use of this NCCN Content is governed by the End-User License Agreement, and you MAY NOT distribute this Content or use it with any artificial intelligence model or tool.
Printed by Máximo López Chenlo on 5/4/2026 6:13:37 PM. Copyright © 2026 National Comprehensive Cancer Network, Inc. All Rights Reserved.

261. Kim TH, Han SS, Park SJ, et al. Role of adjuvant chemoradiotherapy for resected extrahepatic biliary tract cancer. Int J Radiat Oncol Biol Phys 2011;81:e853-859. Available at: http://www.ncbi.nlm.nih.gov/pubmed/21497455.

262. Borghero Y, Crane CH, Szklaruk J, et al. Extrahepatic bile duct adenocarcinoma: patients at high-risk for local recurrence treated with surgery and adjuvant chemoradiation have an equivalent overall survival to patients with standard-risk treated with surgery alone. Ann Surg Oncol 2008;15:3147-3156. Available at: http://www.ncbi.nlm.nih.gov/pubmed/18754070.

263. Park J-h, Choi EK, Ahn SD, et al. Postoperative chemoradiotherapy for extrahepatic bile duct cancer. Int J Radiat Oncol Biol Phys 2011;79:696-704. Available at: http://www.ncbi.nlm.nih.gov/pubmed/20510541.

264. Dominguez DA, Wong P, Chen YJ, et al. Adjuvant chemoradiation in resected biliary adenocarcinoma: Evaluation of SWOG S0809 with a large national database. Ann Surg Oncol 2024;31:4896-4904. Available at: https://www.ncbi.nlm.nih.gov/pubmed/38443700.

265. Das P, Wolff RA, Abbruzzese JL, et al. Concurrent capecitabine and upper abdominal radiation therapy is well tolerated. Radiat Oncol 2006;1:41. Available at: http://www.ncbi.nlm.nih.gov/pubmed/17062148.

266. Lin LL, Picus J, Drebin JA, et al. A phase II study of alternating cycles of split course radiation therapy and gemcitabine chemotherapy for inoperable pancreatic or biliary tract carcinoma. Am J Clin Oncol 2005;28:234-241. Available at: http://www.ncbi.nlm.nih.gov/pubmed/15923794.

267. Williams KJ, Picus J, Trinkhaus K, et al. Gemcitabine with carboplatin for advanced biliary tract cancers: a phase II single institution study. HPB (Oxford) 2010;12:418-426. Available at: http://www.ncbi.nlm.nih.gov/pubmed/20662793.

268. Park J, Kim MH, Kim KP, et al. Natural history and prognostic factors of advanced cholangiocarcinoma without surgery, chemotherapy, or radiotherapy: a large-scale observational study. Gut Liver 2009;3:298-305. Available at: http://www.ncbi.nlm.nih.gov/pubmed/20431764.

269. Oh DY, He AR, Bouattour M, et al. Durvalumab or placebo plus gemcitabine and cisplatin in participants with advanced biliary tract cancer (TOPAZ-1): Updated overall survival from a randomised phase 3 study. Lancet Gastroenterol Hepatol 2024;9:694-704. Available at: https://www.ncbi.nlm.nih.gov/pubmed/38823398.

270. Glimelius B, Hoffman K, Sjoden PO, et al. Chemotherapy improves survival and quality of life in advanced pancreatic and biliary cancer. Ann Oncol 1996;7:593-600. Available at: http://www.ncbi.nlm.nih.gov/pubmed/8879373.

271. Sharma A, Dwary AD, Mohanti BK, et al. Best supportive care compared with chemotherapy for unresectable gall bladder cancer: a randomized controlled study. J Clin Oncol 2010;28:4581-4586. Available at: http://www.ncbi.nlm.nih.gov/pubmed/20855823.

272. Hezel AF, Zhu AX. Systemic therapy for biliary tract cancers. Oncologist 2008;13:415-423. Available at: http://www.ncbi.nlm.nih.gov/pubmed/18448556.

273. Geynisman DM, Catenacci DV. Toward personalized treatment of advanced biliary tract cancers. Discov Med 2012;14:41-57. Available at: http://www.ncbi.nlm.nih.gov/pubmed/22846202.

274. Eckel F, Schmid RM. Chemotherapy in advanced biliary tract carcinoma: a pooled analysis of clinical trials. Br J Cancer 2007;96:896-902. Available at: http://www.ncbi.nlm.nih.gov/pubmed/17325704.

275. Yonemoto N, Furuse J, Okusaka T, et al. A multi-center retrospective analysis of survival benefits of chemotherapy for unresectable biliary tract cancer. Jpn J Clin Oncol 2007;37:843-851. Available at: http://www.ncbi.nlm.nih.gov/pubmed/17942578.

276. Kornek GV, Schuell B, Laengle F, et al. Mitomycin C in combination with capecitabine or biweekly high-dose gemcitabine in patients with advanced biliary tract cancer: a randomised phase II trial. Ann Oncol

Discussion update in progress

Version 1.2026 © 2026 National Comprehensive Cancer Network© (NCCN©), All rights reserved. NCCN Guidelines® and this illustration may not be reproduced in any form without the express written permission of NCCN.

PLEASE NOTE that use of this NCCN Content is governed by the End-User License Agreement, and you MAY NOT distribute this Content or use it with any artificial intelligence model or tool.
Printed by Máximo López Chenlo on 5/4/2026 6:13:37 PM. Copyright © 2026 National Comprehensive Cancer Network, Inc. All Rights Reserved.

2004;15:478-483. Available at: http://www.ncbi.nlm.nih.gov/pubmed/14998852.

277. Ducreux M, Van Cutsem E, Van Laethem JL, et al. A randomised phase II trial of weekly high-dose 5-fluorouracil with and without folinic acid and cisplatin in patients with advanced biliary tract carcinoma: results of the 40955 EORTC trial. Eur J Cancer 2005;41:398-403. Available at: http://www.ncbi.nlm.nih.gov/pubmed/15691639.

278. Okusaka T, Nakachi K, Fukutomi A, et al. Gemcitabine alone or in combination with cisplatin in patients with biliary tract cancer: a comparative multicentre study in Japan. Br J Cancer 2010;103:469-474. Available at: http://www.ncbi.nlm.nih.gov/pubmed/20628385.

279. Phelip JM, Desrame J, Edeline J, et al. Modified FOLFIRINOX versus CISGEM chemotherapy for patients with advanced biliary tract cancer (PRODIGE 38 AMEBICA): A randomized phase II study. J Clin Oncol 2022;40:262-271. Available at: https://www.ncbi.nlm.nih.gov/pubmed/34662180.

280. Lamarca A, Palmer DH, Wasan HS, et al. Second-line FOLFOX chemotherapy versus active symptom control for advanced biliary tract cancer (ABC-06): a phase 3, open-label, randomised, controlled trial. Lancet Oncol 2021;22:690-701. Available at: https://www.ncbi.nlm.nih.gov/pubmed/33798493.

281. Caparica R, Lengele A, Bekolo W, Hendlisz A. FOLFIRI as second-line treatment of metastatic biliary tract cancer patients. Autops Case Rep 2019;9:e2019087. Available at: https://www.ncbi.nlm.nih.gov/pubmed/31528622.

282. Mizrahi JD, Gunchick V, Mody K, et al. Multi-institutional retrospective analysis of FOLFIRI in patients with advanced biliary tract cancers. World J Gastrointest Oncol 2020;12:83-91. Available at: https://www.ncbi.nlm.nih.gov/pubmed/31966916.

283. Choi IS, Kim KH, Lee JH, et al. A randomised phase II study of oxaliplatin/5-FU (mFOLFOX) versus irinotecan/5-FU (mFOLFIRI) chemotherapy in locally advanced or metastatic biliary tract cancer refractory to first-line gemcitabine/cisplatin chemotherapy. Eur J Cancer 2021;154:288-295. Available at: https://www.ncbi.nlm.nih.gov/pubmed/34303267.

284. Yoo C, Kim KP, Jeong JH, et al. Liposomal irinotecan plus fluorouracil and leucovorin versus fluorouracil and leucovorin for metastatic biliary tract cancer after progression on gemcitabine plus cisplatin (NIFTY): A multicentre, open-label, randomised, phase 2b study. Lancet Oncol 2021;22:1560-1572. Available at: https://www.ncbi.nlm.nih.gov/pubmed/34656226.

285. Hyung J, Kim I, Kim KP, et al. Treatment with liposomal irinotecan plus fluorouracil and leucovorin for patients With previously treated metastatic biliary tract cancer: The phase 2b NIFTY randomized clinical trial. JAMA Oncol 2023;9:692-699. Available at: https://www.ncbi.nlm.nih.gov/pubmed/36951834.

286. Vogel A, Saborowski A, Wenzel P, et al. Nanoliposomal irinotecan and fluorouracil plus leucovorin versus fluorouracil plus leucovorin in patients with cholangiocarcinoma and gallbladder carcinoma previously treated with gemcitabine-based therapies (AIO NALIRICC): A multicentre, open-label, randomised, phase 2 trial. Lancet Gastroenterol Hepatol 2024;9:734-744. Available at: https://www.ncbi.nlm.nih.gov/pubmed/38870977.

287. Doval DC, Sekhon JS, Gupta SK, et al. A phase II study of gemcitabine and cisplatin in chemotherapy-naive, unresectable gall bladder cancer. Br J Cancer 2004;90:1516-1520. Available at: http://www.ncbi.nlm.nih.gov/pubmed/15083178.

288. Thongprasert S, Napapan S, Charoentum C, Moonprakan S. Phase II study of gemcitabine and cisplatin as first-line chemotherapy in inoperable biliary tract carcinoma. Ann Oncol 2005;16:279-281. Available at: http://www.ncbi.nlm.nih.gov/pubmed/15668284.

289. Giuliani F, Gebbia V, Maiello E, et al. Gemcitabine and cisplatin for inoperable and/or metastatic biliary tree carcinomas: a multicenter phase II study of the Gruppo Oncologico dell'Italia Meridionale (GOIM). Ann Oncol

Discussion update in progress

Version 1.2026 © 2026 National Comprehensive Cancer Network© (NCCN©), All rights reserved. NCCN Guidelines® and this illustration may not be reproduced in any form without the express written permission of NCCN.

PLEASE NOTE that use of this NCCN Content is governed by the End-User License Agreement, and you MAY NOT distribute this Content or use it with any artificial intelligence model or tool.
Printed by Máximo López Chenlo on 5/4/2026 6:13:37 PM. Copyright © 2026 National Comprehensive Cancer Network, Inc. All Rights Reserved.

2006;17 Suppl 7:73-77. Available at: http://www.ncbi.nlm.nih.gov/pubmed/16760299.

290. Lee J, Kim T-Y, Lee MA, et al. Phase II trial of gemcitabine combined with cisplatin in patients with inoperable biliary tract carcinomas. Cancer Chemother Pharmacol 2008;61:47-52. Available at: http://www.ncbi.nlm.nih.gov/pubmed/17364190.

291. Meyerhardt JA, Zhu AX, Stuart K, et al. Phase-II study of gemcitabine and cisplatin in patients with metastatic biliary and gallbladder cancer. Dig Dis Sci 2008;53:564-570. Available at: http://www.ncbi.nlm.nih.gov/pubmed/17597402.

292. Andre T, Reyes-Vidal JM, Fartoux L, et al. Gemcitabine and oxaliplatin in advanced biliary tract carcinoma: a phase II study. Br J Cancer 2008;99:862-867. Available at: http://www.ncbi.nlm.nih.gov/pubmed/19238628.

293. Harder J, Riecken B, Kummer O, et al. Outpatient chemotherapy with gemcitabine and oxaliplatin in patients with biliary tract cancer. Br J Cancer 2006;95:848-852. Available at: http://www.ncbi.nlm.nih.gov/pubmed/16969352.

294. Kim HJ, Lee NS, Lee S-C, et al. A phase II study of gemcitabine in combination with oxaliplatin as first-line chemotherapy in patients with inoperable biliary tract cancer. Cancer Chemother Pharmacol 2009;64:371-377. Available at: http://www.ncbi.nlm.nih.gov/pubmed/19142638.

295. Jang J-S, Lim HY, Hwang IG, et al. Gemcitabine and oxaliplatin in patients with unresectable biliary cancer including gall bladder cancer: a Korean Cancer Study Group phase II trial. Cancer Chemother Pharmacol 2010;65:641-647. Available at: http://www.ncbi.nlm.nih.gov/pubmed/19652971.

296. Alberts SR, Al-Khatib H, Mahoney MR, et al. Gemcitabine, 5-fluorouracil, and leucovorin in advanced biliary tract and gallbladder carcinoma: a North Central Cancer Treatment Group phase II trial. Cancer 2005;103:111-118. Available at: http://www.ncbi.nlm.nih.gov/pubmed/15558814.

297. Knox JJ, Hedley D, Oza A, et al. Combining gemcitabine and capecitabine in patients with advanced biliary cancer: a phase II trial. J Clin Oncol 2005;23:2332-2338. Available at: http://www.ncbi.nlm.nih.gov/pubmed/15800324.

298. Riechelmann RP, Townsley CA, Chin SN, et al. Expanded phase II trial of gemcitabine and capecitabine for advanced biliary cancer. Cancer 2007;110:1307-1312. Available at: http://www.ncbi.nlm.nih.gov/pubmed/17628484.

299. Koeberle D, Saletti P, Borner M, et al. Patient-reported outcomes of patients with advanced biliary tract cancers receiving gemcitabine plus capecitabine: a multicenter, phase II trial of the Swiss Group for Clinical Cancer Research. J Clin Oncol 2008;26:3702-3708. Available at: http://www.ncbi.nlm.nih.gov/pubmed/18669455.

300. Iqbal S, Rankin C, Lenz H-J, et al. A phase II trial of gemcitabine and capecitabine in patients with unresectable or metastatic gallbladder cancer or cholangiocarcinoma: Southwest Oncology Group study S0202. Cancer Chemother Pharmacol 2011;68:1595-1602. Available at: http://www.ncbi.nlm.nih.gov/pubmed/21556747.

301. Sahai V, Catalano PJ, Zalupski MM, et al. Nab-paclitaxel and gemcitabine as first-line treatment of advanced or metastatic cholangiocarcinoma: a phase 2 clinical trial. JAMA Oncol 2018;4:1707-1712. Available at: https://www.ncbi.nlm.nih.gov/pubmed/30178032.

302. Borbath I, Ceratti A, Verslype C, et al. Combination of gemcitabine and cetuximab in patients with advanced cholangiocarcinoma: a phase II study of the Belgian Group of Digestive Oncology. Ann Oncol 2013;24:2824-2829. Available at: http://www.ncbi.nlm.nih.gov/pubmed/23975665.

303. Nehls O, Klump B, Arkenau HT, et al. Oxaliplatin, fluorouracil and leucovorin for advanced biliary system adenocarcinomas: a prospective

Discussion update in progress

Version 1.2026 © 2026 National Comprehensive Cancer Network© (NCCN©), All rights reserved. NCCN Guidelines® and this illustration may not be reproduced in any form without the express written permission of NCCN.

PLEASE NOTE that use of this NCCN Content is governed by the End-User License Agreement, and you MAY NOT distribute this Content or use it with any artificial intelligence model or tool.
Printed by Máximo López Chenlo on 5/4/2026 6:13:37 PM. Copyright © 2026 National Comprehensive Cancer Network, Inc. All Rights Reserved.

phase II trial. Br J Cancer 2002;87:702-704. Available at: http://www.ncbi.nlm.nih.gov/pubmed/12232749.

304. Nehls O, Oettle H, Hartmann JT, et al. Capecitabine plus oxaliplatin as first-line treatment in patients with advanced biliary system adenocarcinoma: a prospective multicentre phase II trial. Br J Cancer 2008;98:309-315. Available at: http://www.ncbi.nlm.nih.gov/pubmed/18182984.

305. Kim TW, Chang HM, Kang HJ, et al. Phase II study of capecitabine plus cisplatin as first-line chemotherapy in advanced biliary cancer. Ann Oncol 2003;14:1115-1120. Available at: http://www.ncbi.nlm.nih.gov/pubmed/12853355.

306. Kobayashi K, Tsuji A, Morita S, et al. A phase II study of LFP therapy (5-FU (5-fluorourasil) continuous infusion (CVI) and Low-dose consecutive (Cisplatin) CDDP) in advanced biliary tract carcinoma. BMC Cancer 2006;6:121. Available at: https://www.ncbi.nlm.nih.gov/pubmed/16677397.

307. Kim ST, Kang JH, Lee J, et al. Capecitabine plus oxaliplatin versus gemcitabine plus oxaliplatin as first-line therapy for advanced biliary tract cancers: a multicenter, open-label, randomized, phase III, noninferiority trial. Ann Oncol 2019;30:788-795. Available at: https://www.ncbi.nlm.nih.gov/pubmed/30785198.

308. Rao S, Cunningham D, Hawkins RE, et al. Phase III study of 5FU, etoposide and leucovorin (FELV) compared to epirubicin, cisplatin and 5FU (ECF) in previously untreated patients with advanced biliary cancer. Br J Cancer 2005;92:1650-1654. Available at: http://www.ncbi.nlm.nih.gov/pubmed/15856037.

309. Yamashita Y-i, Taketomi A, Fukuzawa K, et al. Gemcitabine combined with 5-fluorouracil and cisplatin (GFP) in patients with advanced biliary tree cancers: a pilot study. Anticancer Res 2006;26:771-775. Available at: http://www.ncbi.nlm.nih.gov/pubmed/16739352.

310. Wagner AD, Buechner-Steudel P, Moehler M, et al. Gemcitabine, oxaliplatin and 5-FU in advanced bile duct and gallbladder carcinoma: two parallel, multicentre phase-II trials. Br J Cancer 2009;101:1846-1852. Available at: http://www.ncbi.nlm.nih.gov/pubmed/19904267.

311. Sohal DP, Mykulowycz K, Uehara T, et al. A phase II trial of gemcitabine, irinotecan and panitumumab in advanced cholangiocarcinoma. Ann Oncol 2013;24:3061-3065. Available at: http://www.ncbi.nlm.nih.gov/pubmed/24146220.

312. Moehler M, Maderer A, Schimanski C, et al. Gemcitabine plus sorafenib versus gemcitabine alone in advanced biliary tract cancer: a double-blind placebo-controlled multicentre phase II AIO study with biomarker and serum programme. Eur J Cancer 2014;50:3125-3135. Available at: https://www.ncbi.nlm.nih.gov/pubmed/25446376.

313. Ettrich TJ, Modest DP, Sinn M, et al. Nanoliposomal irinotecan with fluorouracil and leucovorin or gemcitabine plus cisplatin in advanced cholangiocarcinoma: A phase II Study of the AIO Hepatobiliary-YMO cancer groups (NIFE-AIO-YMO HEP-0315). J Clin Oncol 2024;42:3094-3104. Available at: https://www.ncbi.nlm.nih.gov/pubmed/38843469.

314. Ramaswamy A, Bhargava P, Srinivas S, et al. Bevacizumab erlotinib switch maintenance in chemo-responsive advanced gallbladder and cholangiocarcinoma (BEER BTC): A multicenter, open-label, randomized, phase II trial. J Clin Oncol 2024;42:3218-3227. Available at: https://www.ncbi.nlm.nih.gov/pubmed/39102628.

315. Ghafoori AP, Nelson JW, Willett CG, et al. Radiotherapy in the treatment of patients with unresectable extrahepatic cholangiocarcinoma. Int J Radiat Oncol Biol Phys 2011;81:654-659. Available at: https://www.ncbi.nlm.nih.gov/pubmed/20864265.

316. Macdonald OK, Crane CH. Palliative and postoperative radiotherapy in biliary tract cancer. Surg Oncol Clin N Am 2002;11:941-954. Available at: http://www.ncbi.nlm.nih.gov/pubmed/12607581.

317. Czito BG, Anscher MS, Willett CG. Radiation therapy in the treatment of cholangiocarcinoma. Oncology (Williston Park) 2006;20:873-884. Available at: http://www.ncbi.nlm.nih.gov/pubmed/16922259.

Discussion update in progress

Version 1.2026 © 2026 National Comprehensive Cancer Network© (NCCN©), All rights reserved. NCCN Guidelines® and this illustration may not be reproduced in any form without the express written permission of NCCN.

PLEASE NOTE that use of this NCCN Content is governed by the End-User License Agreement, and you MAY NOT distribute this Content or use it with any artificial intelligence model or tool.
Printed by Máximo López Chenlo on 5/4/2026 6:13:37 PM. Copyright © 2026 National Comprehensive Cancer Network, Inc. All Rights Reserved.

318. Frakulli R, Buwenge M, Macchia G, et al. Stereotactic body radiation therapy in cholangiocarcinoma: a systematic review. Br J Radiol 2019;92:20180688. Available at: https://www.ncbi.nlm.nih.gov/pubmed/30673295.

319. Moureau-Zabotto L, Turrini O, Resbeut M, et al. Impact of radiotherapy in the management of locally advanced extrahepatic cholangiocarcinoma. BMC Cancer 2013;13:568. Available at: https://www.ncbi.nlm.nih.gov/pubmed/24299517.

320. Uno T, Itami J, Aruga M, et al. Primary carcinoma of the gallbladder: role of external beam radiation therapy in patients with locally advanced tumor. Strahlenther Onkol 1996;172:496-500. Available at: https://www.ncbi.nlm.nih.gov/pubmed/8830812.

321. Kumar-Sinha C, Vats P, Tran N, et al. Genomics driven precision oncology in advanced biliary tract cancer improves survival. Neoplasia 2023;42:100910. Available at: https://www.ncbi.nlm.nih.gov/pubmed/37267699.

322. Maynard H, Stadler ZK, Berger MF, et al. Germline alterations in patients with biliary tract cancers: A spectrum of significant and previously underappreciated findings. Cancer 2020;126:1995-2002. Available at: https://www.ncbi.nlm.nih.gov/pubmed/32012241.

323. Samadder NJ, Riegert-Johnson D, Boardman L, et al. Comparison of universal genetic testing vs guideline-directed targeted testing for patients with hereditary cancer syndrome. JAMA Oncol 2021;7:230-237. Available at: https://www.ncbi.nlm.nih.gov/pubmed/33126242.

324. Okamura R, Boichard A, Kato S, et al. Analysis of *NTRK* alterations in pan-cancer adult and pediatric malignancies: Implications for NTRK-targeted therapeutics. JCO Precis Oncol 2018;2018:PO.18.00183. Available at: https://www.ncbi.nlm.nih.gov/pubmed/30637364.

325. Lamarca A, Barriuso J, McNamara MG, Valle JW. Molecular targeted therapies: Ready for "prime time" in biliary tract cancer. J Hepatol 2020;73:170-185. Available at: https://www.ncbi.nlm.nih.gov/pubmed/32171892.

326. Drilon A, Laetsch TW, Kummar S, et al. Efficacy of larotrectinib in TRK fusion-positive cancers in adults and children. N Engl J Med 2018;378:731-739. Available at: https://www.ncbi.nlm.nih.gov/pubmed/29466156.

327. Doebele RC, Drilon A, Paz-Ares L, et al. Entrectinib in patients with advanced or metastatic NTRK fusion-positive solid tumours: integrated analysis of three phase 1-2 trials. Lancet Oncol 2020;21:271-282. Available at: https://www.ncbi.nlm.nih.gov/pubmed/31838007.

328. Solomon BJ, Drilon A, Lin JJ, et al. Repotrectinib in patients (pts) with NTRK fusion-positive (NTRK+) advanced solid tumors, including NSCLC: Update from the phase I/II TRIDENT-1 trial [abstract]. Ann Oncol 2023;34:Abstract 1372P. Available at: https://www.annalsofoncology.org/article/S0923-7534(23)03242-8/fulltext.

329. Le DT, Durham JN, Smith KN, et al. Mismatch repair deficiency predicts response of solid tumors to PD-1 blockade. Science 2017;357:409-413. Available at: https://www.ncbi.nlm.nih.gov/pubmed/28596308.

330. Silva VW, Askan G, Daniel TD, et al. Biliary carcinomas: Pathology and the role of DNA mismatch repair deficiency. Chin Clin Oncol 2016;5:62. Available at: https://www.ncbi.nlm.nih.gov/pubmed/27829276.

331. Rizzo A, Ricci AD, Brandi G. PD-L1, TMB, MSI, and other predictors of response to immune checkpoint inhibitors in biliary tract cancer. Cancers (Basel) 2021;13:558. Available at: https://www.ncbi.nlm.nih.gov/pubmed/33535621.

332. Marabelle A, Fakih M, Lopez J, et al. Association of tumour mutational burden with outcomes in patients with advanced solid tumours treated with pembrolizumab: prospective biomarker analysis of the multicohort, open-label, phase 2 KEYNOTE-158 study. Lancet Oncol 2020;21:1353-1365. Available at: https://www.ncbi.nlm.nih.gov/pubmed/32919526.

333. Piha-Paul SA, Oh DY, Ueno M, et al. Efficacy and safety of pembrolizumab for the treatment of advanced biliary cancer: Results from

Discussion update in progress

Version 1.2026 © 2026 National Comprehensive Cancer Network© (NCCN©), All rights reserved. NCCN Guidelines® and this illustration may not be reproduced in any form without the express written permission of NCCN.

PLEASE NOTE that use of this NCCN Content is governed by the End-User License Agreement, and you MAY NOT distribute this Content or use it with any artificial intelligence model or tool.
Printed by Máximo López Chenlo on 5/4/2026 6:13:37 PM. Copyright © 2026 National Comprehensive Cancer Network, Inc. All Rights Reserved.

the KEYNOTE-158 and KEYNOTE-028 studies. Int J Cancer 2020;147:2190-2198. Available at: https://www.ncbi.nlm.nih.gov/pubmed/32359091.

334. Zang YS, Dai C, Xu X, et al. Comprehensive analysis of potential immunotherapy genomic biomarkers in 1000 Chinese patients with cancer. Cancer Med 2019;8:4699-4708. Available at: https://www.ncbi.nlm.nih.gov/pubmed/31270941.

335. Cancer Genome Atlas Research Network. Comprehensive and integrative genomic characterization of hepatocellular carcinoma. Cell 2017;169:1327-1341.e1323. Available at: https://www.ncbi.nlm.nih.gov/pubmed/28622513.

336. Weinberg BA, Xiu J, Lindberg MR, et al. Molecular profiling of biliary cancers reveals distinct molecular alterations and potential therapeutic targets. J Gastrointest Oncol 2019;10:652-662. Available at: https://www.ncbi.nlm.nih.gov/pubmed/31392046.

337. Israel MA, Danziger N, McGregor KA, et al. Comparative genomic analysis of intrahepatic cholangiocarcinoma: Biopsy type, ancestry, and testing patterns. Oncologist 2021;26:787-796. Available at: https://www.ncbi.nlm.nih.gov/pubmed/34080753.

338. Marabelle A, Le DT, Ascierto PA, et al. Efficacy of pembrolizumab in patients with noncolorectal high microsatellite instability/mismatch repair-deficient cancer: Results from the phase II KEYNOTE-158 study. J Clin Oncol 2020;38:1-10. Available at: https://www.ncbi.nlm.nih.gov/pubmed/31682550.

339. Maio M, Ascierto PA, Manzyuk L, et al. Pembrolizumab in microsatellite instability high or mismatch repair deficient cancers: Updated analysis from the phase II KEYNOTE-158 study. Ann Oncol 2022;33:929-938. Available at: https://www.ncbi.nlm.nih.gov/pubmed/35680043.

340. Sicklick JK, Kato S, Okamura R, et al. Molecular profiling of cancer patients enables personalized combination therapy: the I-PREDICT study. Nat Med 2019;25:744-750. Available at: https://www.ncbi.nlm.nih.gov/pubmed/31011206.

341. Andre T, Berton D, Curigliano G, et al. Antitumor activity and safety of dostarlimab monotherapy in patients with mismatch repair deficient solid tumors: A nonrandomized controlled trial. JAMA Netw Open 2023;6:e2341165. Available at: https://www.ncbi.nlm.nih.gov/pubmed/37917058.

342. Schenker M, Burotto M, Richardet M, et al. Randomized, open-label, phase 2 study of nivolumab plus ipilimumab or nivolumab monotherapy in patients with advanced or metastatic solid tumors of high tumor mutational burden. J Immunother Cancer 2024;12. Available at: https://www.ncbi.nlm.nih.gov/pubmed/39107131.

343. Kim RD, Chung V, Alese OB, et al. A phase 2 multi-institutional study of nivolumab for patients with advanced refractory biliary tract cancer. JAMA Oncol 2020;6:888-894. Available at: https://www.ncbi.nlm.nih.gov/pubmed/32352498.

344. Ahn S, Lee JC, Shin DW, et al. High PD-L1 expression is associated with therapeutic response to pembrolizumab in patients with advanced biliary tract cancer. Sci Rep 2020;10:12348. Available at: https://www.ncbi.nlm.nih.gov/pubmed/32704067.

345. Subbiah V, Lassen U, Elez E, et al. Dabrafenib plus trametinib in patients with BRAF^{V600E}-mutated biliary tract cancer (ROAR): A phase 2, open-label, single-arm, multicentre basket trial. Lancet Oncol 2020;21:1234-1243. Available at: https://www.ncbi.nlm.nih.gov/pubmed/32818466.

346. Andersen JB, Spee B, Blechacz BR, et al. Genomic and genetic characterization of cholangiocarcinoma identifies therapeutic targets for tyrosine kinase inhibitors. Gastroenterology 2012;142:1021-1031.e1015. Available at: https://www.ncbi.nlm.nih.gov/pubmed/22178589.

347. Goeppert B, Frauenschuh L, Renner M, et al. BRAF V600E-specific immunohistochemistry reveals low mutation rates in biliary tract cancer and restriction to intrahepatic cholangiocarcinoma. Mod Pathol

Discussion update in progress

Version 1.2026 © 2026 National Comprehensive Cancer Network© (NCCN©), All rights reserved. NCCN Guidelines® and this illustration may not be reproduced in any form without the express written permission of NCCN.

PLEASE NOTE that use of this NCCN Content is governed by the End-User License Agreement, and you MAY NOT distribute this Content or use it with any artificial intelligence model or tool.
Printed by Máximo López Chenlo on 5/4/2026 6:13:37 PM. Copyright © 2026 National Comprehensive Cancer Network, Inc. All Rights Reserved.

2014;27:1028-1034. Available at: https://www.ncbi.nlm.nih.gov/pubmed/24309328.

348. Simbolo M, Fassan M, Ruzzenente A, et al. Multigene mutational profiling of cholangiocarcinomas identifies actionable molecular subgroups. Oncotarget 2014;5:2839-2852. Available at: https://www.ncbi.nlm.nih.gov/pubmed/24867389.

349. Salama AKS, Li S, Macrae ER, et al. Dabrafenib and trametinib in patients with tumors with *BRAF*^{V600E} mutations: Results of the NCI-MATCH trial Subprotocol H. J Clin Oncol 2020;38:3895-3904. Available at: https://www.ncbi.nlm.nih.gov/pubmed/32758030.

350. Farshidfar F, Zheng S, Gingras MC, et al. Integrative genomic analysis of cholangiocarcinoma identifies distinct IDH-mutant molecular profiles. Cell Rep 2017;18:2780-2794. Available at: https://www.ncbi.nlm.nih.gov/pubmed/28297679.

351. Lee H, Wang K, Johnson A, et al. Comprehensive genomic profiling of extrahepatic cholangiocarcinoma reveals a long tail of therapeutic targets. J Clin Pathol 2016;69:403-408. Available at: https://www.ncbi.nlm.nih.gov/pubmed/26500333.

352. Goyal L, Meric-Bernstam F, Hollebecque A, et al. Futibatinib for *FGFR2*-rearranged intrahepatic cholangiocarcinoma. N Engl J Med 2023;388:228-239. Available at: https://www.ncbi.nlm.nih.gov/pubmed/36652354.

353. Silverman IM, Hollebecque A, Friboulet L, et al. Clinicogenomic analysis of *FGFR2*-rearranged cholangiocarcinoma identifies correlates of response and mechanisms of resistance to pemigatinib. Cancer Discov 2021;11:326-339. Available at: https://www.ncbi.nlm.nih.gov/pubmed/33218975.

354. Vogel A, Sahai V, Hollebecque A, et al. An open-label study of pemigatinib in cholangiocarcinoma: Final results from FIGHT-202. ESMO Open 2024;9:103488. Available at: https://www.ncbi.nlm.nih.gov/pubmed/38838500.

355. Pant S, Schuler M, Iyer G, et al. Erdafitinib in patients with advanced solid tumours with FGFR alterations (RAGNAR): An international, single-arm, phase 2 study. Lancet Oncol 2023;24:925-935. Available at: https://www.ncbi.nlm.nih.gov/pubmed/37541273.

356. Javle MM, Abou-Alfa GK, Macarulla T, et al. Efficacy of derazantinib in intrahepatic cholangiocarcinoma patients with FGFR2 mutations or amplifications: Interim results from the phase 2 study FIDES-01 [abstract]. J Clin Oncol 2022;40:Abstract 427. Available at: https://ascopubs.org/doi/abs/10.1200/JCO.2022.40.4_suppl.427.

357. Aguado-Fraile E, Tassinari A, Ishii Y, et al. Molecular and morphological changes induced by ivosidenib correlate with efficacy in mutant-*IDH1* cholangiocarcinoma. Future Oncol 2021;17:2057-2074. Available at: https://www.ncbi.nlm.nih.gov/pubmed/33709779.

358. Boscoe AN, Rolland C, Kelley RK. Frequency and prognostic significance of isocitrate dehydrogenase 1 mutations in cholangiocarcinoma: a systematic literature review. J Gastrointest Oncol 2019;10:751-765. Available at: https://www.ncbi.nlm.nih.gov/pubmed/31392056.

359. Javle M, Bekaii-Saab T, Jain A, et al. Biliary cancer: Utility of next-generation sequencing for clinical management. Cancer 2016;122:3838-3847. Available at: https://www.ncbi.nlm.nih.gov/pubmed/27622582.

360. Abou-Alfa GK, Macarulla T, Javle MM, et al. Ivosidenib in IDH1-mutant, chemotherapy-refractory cholangiocarcinoma (ClarIDHy): A multicentre, randomised, double-blind, placebo-controlled, phase 3 study. Lancet Oncol 2020;21:796-807. Available at: https://www.ncbi.nlm.nih.gov/pubmed/32416072.

361. Zhu AX, Macarulla T, Javle MM, et al. Final overall survival efficacy results of ivosidenib for patients with advanced cholangiocarcinoma with IDH1 mutation: The phase 3 randomized clinical ClarIDHy trial. JAMA Oncol 2021;7:1669-1677. Available at: https://www.ncbi.nlm.nih.gov/pubmed/34554208.

Discussion update in progress

Version 1.2026 © 2026 National Comprehensive Cancer Network© (NCCN©), All rights reserved. NCCN Guidelines® and this illustration may not be reproduced in any form without the express written permission of NCCN.

PLEASE NOTE that use of this NCCN Content is governed by the End-User License Agreement, and you MAY NOT distribute this Content or use it with any artificial intelligence model or tool.
Printed by Máximo López Chenlo on 5/4/2026 6:13:37 PM. Copyright © 2026 National Comprehensive Cancer Network, Inc. All Rights Reserved.

362. Jacobi O, Ross JS, Goshen-Lago T, et al. ERBB2 pathway in biliary tract carcinoma: Clinical implications of a targetable pathway. Oncol Res Treat 2021;44:20-27. Available at: https://www.ncbi.nlm.nih.gov/pubmed/33279901.

363. Xian ZH, Zhang SH, Cong WM, et al. Overexpression/amplification of HER-2/neu is uncommon in hepatocellular carcinoma. J Clin Pathol 2005;58:500-503. Available at: https://www.ncbi.nlm.nih.gov/pubmed/15858121.

364. Hiraoka N, Nitta H, Ohba A, et al. Details of human epidermal growth factor receptor 2 status in 454 cases of biliary tract cancer. Hum Pathol 2020;105:9-19. Available at: https://www.ncbi.nlm.nih.gov/pubmed/32891647.

365. Galdy S, Lamarca A, McNamara MG, et al. HER2/HER3 pathway in biliary tract malignancies; systematic review and meta-analysis: A potential therapeutic target? Cancer Metastasis Rev 2017;36:141-157. Available at: https://www.ncbi.nlm.nih.gov/pubmed/27981460.

366. Yan M, Schwaederle M, Arguello D, et al. HER2 expression status in diverse cancers: Review of results from 37,992 patients. Cancer Metastasis Rev 2015;34:157-164. Available at: https://www.ncbi.nlm.nih.gov/pubmed/25712293.

367. Churi CR, Shroff R, Wang Y, et al. Mutation profiling in cholangiocarcinoma: prognostic and therapeutic implications. PLoS One 2014;9:e115383. Available at: https://www.ncbi.nlm.nih.gov/pubmed/25536104.

368. Roa I, de Toro G, Schalper K, et al. Overexpression of the HER2/neu gene: a new therapeutic possibility for patients with advanced gallbladder cancer. Gastrointest Cancer Res 2014;7:42-48. Available at: https://www.ncbi.nlm.nih.gov/pubmed/24799970.

369. Ramanathan RK, Belani CP, Singh DA, et al. A phase II study of lapatinib in patients with advanced biliary tree and hepatocellular cancer. Cancer Chemother Pharmacol 2009;64:777-783. Available at: https://www.ncbi.nlm.nih.gov/pubmed/19169683.

370. Peck J, Wei L, Zalupski M, et al. HER2/neu may not be an interesting target in biliary cancers: Results of an early phase II study with lapatinib. Oncology 2012;82:175-179. Available at: https://www.ncbi.nlm.nih.gov/pubmed/22433475.

371. Hainsworth JD, Meric-Bernstam F, Swanton C, et al. Targeted therapy for advanced solid tumors on the basis of molecular profiles: Results from MyPathway, an open-label, phase IIa multiple basket study. J Clin Oncol 2018;36:536-542. Available at: https://www.ncbi.nlm.nih.gov/pubmed/29320312.

372. Hyman DM, Piha-Paul SA, Won H, et al. HER kinase inhibition in patients with HER2- and HER3-mutant cancers. Nature 2018;554:189-194. Available at: https://www.ncbi.nlm.nih.gov/pubmed/29420467.

373. Meric-Bernstam F, Beeram M, Hamilton E, et al. Zanidatamab, a novel bispecific antibody, for the treatment of locally advanced or metastatic HER2-expressing or HER2-amplified cancers: A phase 1, dose-escalation and expansion study. Lancet Oncol 2022;23:1558-1570. Available at: https://www.ncbi.nlm.nih.gov/pubmed/36400106.

374. Meric-Bernstam F, Makker V, Oaknin A, et al. Efficacy and safety of trastuzumab deruxtecan in patients with HER2-expressing solid tumors: Primary results from the DESTINY-PanTumor02 phase II trial. J Clin Oncol 2024;42:47-58. Available at: https://www.ncbi.nlm.nih.gov/pubmed/37870536.

375. Ohba A, Morizane C, Kawamoto Y, et al. Trastuzumab Deruxtecan in Human Epidermal Growth Factor Receptor 2-Expressing Biliary Tract Cancer (HERB; NCCH1805): A Multicenter, Single-Arm, Phase II Trial. J Clin Oncol 2024;42:3207-3217. Available at: https://www.ncbi.nlm.nih.gov/pubmed/39102634.

376. Javle M, Churi C, Kang HC, et al. HER2/neu-directed therapy for biliary tract cancer. J Hematol Oncol 2015;8:58. Available at: https://www.ncbi.nlm.nih.gov/pubmed/26022204.

377. Javle M, Borad MJ, Azad NS, et al. Pertuzumab and trastuzumab for HER2-positive, metastatic biliary tract cancer (MyPathway): A multicentre,

Discussion update in progress

Version 1.2026 © 2026 National Comprehensive Cancer Network© (NCCN©), All rights reserved. NCCN Guidelines® and this illustration may not be reproduced in any form without the express written permission of NCCN.

PLEASE NOTE that use of this NCCN Content is governed by the End-User License Agreement, and you MAY NOT distribute this Content or use it with any artificial intelligence model or tool.
Printed by Máximo López Chenlo on 5/4/2026 6:13:37 PM. Copyright © 2026 National Comprehensive Cancer Network, Inc. All Rights Reserved.

open-label, phase 2a, multiple basket study. Lancet Oncol 2021;22:1290-1300. Available at: https://www.ncbi.nlm.nih.gov/pubmed/34339623.

378. Cannon TL, Rothe M, Mangat PK, et al. Pertuzumab plus trastuzumab in patients with biliary tract cancer with ERBB2/3 alterations: Results from the Targeted Agent and Profiling Utilization Registry study. J Clin Oncol 2024;42:3228-3237. Available at: https://www.ncbi.nlm.nih.gov/pubmed/38748939.

379. Jeong H, Jeong JH, Kim KP, et al. Feasibility of HER2-targeted therapy in advanced biliary tract cancer: A prospective pilot sudy of trastuzumab biosimilar in combination with gemcitabine plus cisplatin. Cancers (Basel) 2021;13:161. Available at: https://www.ncbi.nlm.nih.gov/pubmed/33418871.

380. Nakamura Y, Mizuno N, Sunakawa Y, et al. Tucatinib and trastuzumab for previously treated human epidermal growth factor receptor 2-positive metastatic biliary tract cancer (SGNTUC-019): A phase II basket study. J Clin Oncol 2023;41:5569-5578. Available at: https://www.ncbi.nlm.nih.gov/pubmed/37751561.

381. Harding JJ, Fan J, Oh DY, et al. Zanidatamab for HER2-amplified, unresectable, locally advanced or metastatic biliary tract cancer (HERIZON-BTC-01): A multicentre, single-arm, phase 2b study. Lancet Oncol 2023;24:772-782. Available at: https://www.ncbi.nlm.nih.gov/pubmed/37276871.

382. Harding JJ, Piha-Paul SA, Shah RH, et al. Antitumour activity of neratinib in patients with HER2-mutant advanced biliary tract cancers. Nat Commun 2023;14:630. Available at: https://www.ncbi.nlm.nih.gov/pubmed/36746967.

383. Ostwal V, Mandavkar S, Bhargava P, et al. Trastuzumab plus gemcitabine-cisplatin for treatment-naive human epidermal growth factor receptor 2-positive biliary tract adenocarcinoma: A multicenter, open-label, phase II study (TAB). J Clin Oncol 2024;42:800-807. Available at: https://www.ncbi.nlm.nih.gov/pubmed/37944079.

384. Hong DS, Fakih MG, Strickler JH, et al. KRAS^{G12C} inhibition with sotorasib in advanced solid tumors. N Engl J Med 2020;383:1207-1217. Available at: https://www.ncbi.nlm.nih.gov/pubmed/32955176.

385. Skoulidis F, Li BT, Dy GK, et al. Sotorasib for lung cancers with *KRAS* p.G12C mutation. N Engl J Med 2021;384:2371-2381. Available at: https://www.ncbi.nlm.nih.gov/pubmed/34096690.

386. Bekaii-Saab TS, Yaeger R, Spira AI, et al. Adagrasib in advanced solid tumors harboring a KRAS^{G12C} mutation. J Clin Oncol 2023;41:4097-4106. Available at: https://www.ncbi.nlm.nih.gov/pubmed/37099736.

387. Goyal L, Zheng H, Yurgelun MB, et al. A phase 2 and biomarker study of cabozantinib in patients with advanced cholangiocarcinoma. Cancer 2017;123:1979-1988. Available at: https://www.ncbi.nlm.nih.gov/pubmed/28192597.

388. Pant S, Saleh M, Bendell J, et al. A phase I dose escalation study of oral c-MET inhibitor tivantinib (ARQ 197) in combination with gemcitabine in patients with solid tumors. Ann Oncol 2014;25:1416-1421. Available at: https://www.ncbi.nlm.nih.gov/pubmed/24737778.

389. Abou-Alfa GK, Meyer T, Cheng AL, et al. Cabozantinib in patients with advanced and progressing hepatocellular carcinoma. N Engl J Med 2018;379:54-63. Available at: https://www.ncbi.nlm.nih.gov/pubmed/29972759.

390. Zhou Y, Lizaso A, Mao X, et al. Novel AMBRA1-ALK fusion identified by next-generation sequencing in advanced gallbladder cancer responds to crizotinib: A case report. Ann Transl Med 2020;8:1099. Available at: https://www.ncbi.nlm.nih.gov/pubmed/33145318.

391. Subbiah V, Cassier PA, Siena S, et al. Pan-cancer efficacy of pralsetinib in patients with RET fusion-positive solid tumors from the phase 1/2 ARROW trial. Nat Med 2022;28:1640-1645. Available at: https://www.ncbi.nlm.nih.gov/pubmed/35962206.

392. Gu TL, Deng X, Huang F, et al. Survey of tyrosine kinase signaling reveals ROS kinase fusions in human cholangiocarcinoma. PLoS One

Discussion update in progress

Version 1.2026 © 2026 National Comprehensive Cancer Network© (NCCN©), All rights reserved. NCCN Guidelines® and this illustration may not be reproduced in any form without the express written permission of NCCN.

PLEASE NOTE that use of this NCCN Content is governed by the End-User License Agreement, and you MAY NOT distribute this Content or use it with any artificial intelligence model or tool.
Printed by Máximo López Chenlo on 5/4/2026 6:13:37 PM. Copyright © 2026 National Comprehensive Cancer Network, Inc. All Rights Reserved.

2011;6:e15640. Available at: https://www.ncbi.nlm.nih.gov/pubmed/21253578.

393. Argani P, Palsgrove DN, Anders RA, et al. A novel NIPBL-NACC1 gene fusion is characteristic of the cholangioblastic variant of intrahepatic cholangiocarcinoma. Am J Surg Pathol 2021;45:1550-1560. Available at: https://www.ncbi.nlm.nih.gov/pubmed/33999553.

394. Augustin J, Gabignon C, Scriva A, et al. Testing for ROS1, ALK, MET, and HER2 rearrangements and amplifications in a large series of biliary tract adenocarcinomas. Virchows Arch 2020;477:33-45. Available at: https://www.ncbi.nlm.nih.gov/pubmed/32447492.

395. Salem ME, El-Refai SM, Sha W, et al. Landscape of *KRAS*^{G12C}, associated genomic alterations, and interrelation with Immuno-oncology biomarkers in *KRAS*-mutated cancers. JCO Precis Oncol 2022;6:e2100245. Available at: https://www.ncbi.nlm.nih.gov/pubmed/35319967.

396. Berchuck JE, Facchinetti F, DiToro DF, et al. The clinical landscape of cell-free DNA alterations in 1671 patients with advanced biliary tract cancer. Ann Oncol 2022;33:1269-1283. Available at: https://www.ncbi.nlm.nih.gov/pubmed/36089135.

397. Kato S, Subbiah V, Marchlik E, et al. *RET* aberrations in diverse cancers: Next-generation sequencing of 4,871 patients. Clin Cancer Res 2017;23:1988-1997. Available at: https://www.ncbi.nlm.nih.gov/pubmed/27683183.

398. Subbiah V, Wolf J, Konda B, et al. Tumour-agnostic efficacy and safety of selpercatinib in patients with RET fusion-positive solid tumours other than lung or thyroid tumours (LIBRETTO-001): A phase 1/2, open-label, basket trial. Lancet Oncol 2022;23:1261-1273. Available at: https://www.ncbi.nlm.nih.gov/pubmed/36108661.

399. Kim RD, Sanoff HK, Poklepovic AS, et al. A multi-institutional phase 2 trial of regorafenib in refractory advanced biliary tract cancer. Cancer 2020;126:3464-3470. Available at: https://www.ncbi.nlm.nih.gov/pubmed/32453456.

400. Demols A, Borbath I, Van den Eynde M, et al. Regorafenib after failure of gemcitabine and platinum-based chemotherapy for locally advanced/metastatic biliary tumors: REACHIN, a randomized, double-blind, phase II trial. Ann Oncol 2020;31:1169-1177. Available at: https://www.ncbi.nlm.nih.gov/pubmed/32464280.

Discussion update in progress

Version 1.2026 © 2026 National Comprehensive Cancer Network© (NCCN©), All rights reserved. NCCN Guidelines® and this illustration may not be reproduced in any form without the express written permission of NCCN.